

Forensic on Hyper Drive!



Matt A. Chandran
INFOVALLEY Group

Scene of Death

Natural Death



Unnatural Death



Suicide



Homicide



Accident



95 percent via Coroners




5 percent by Police



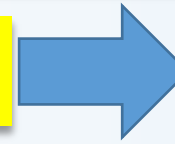
**AUTOPSY
CASES**



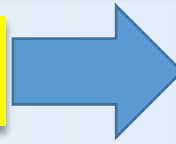
Crime Scene



Secured



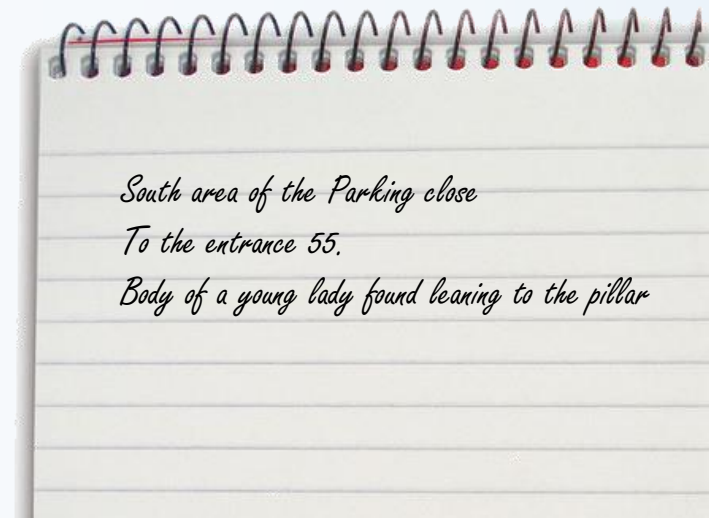
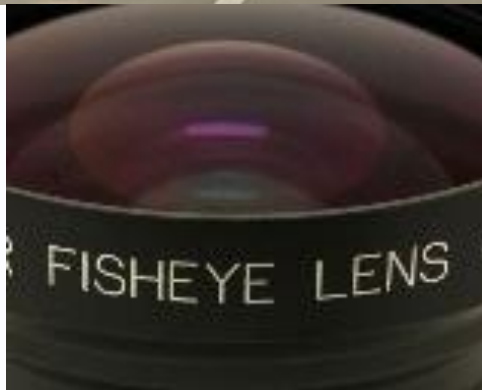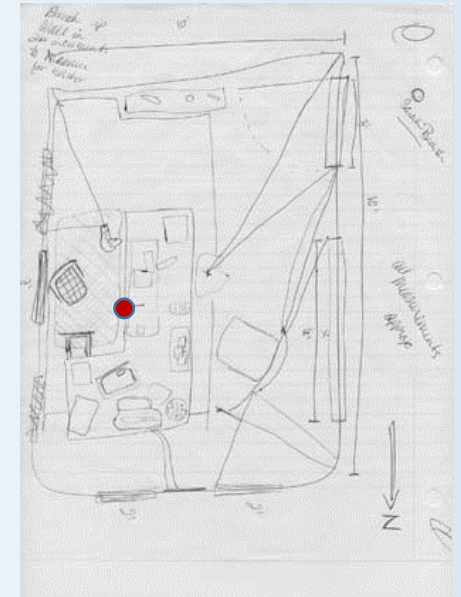
Explored



Tagged

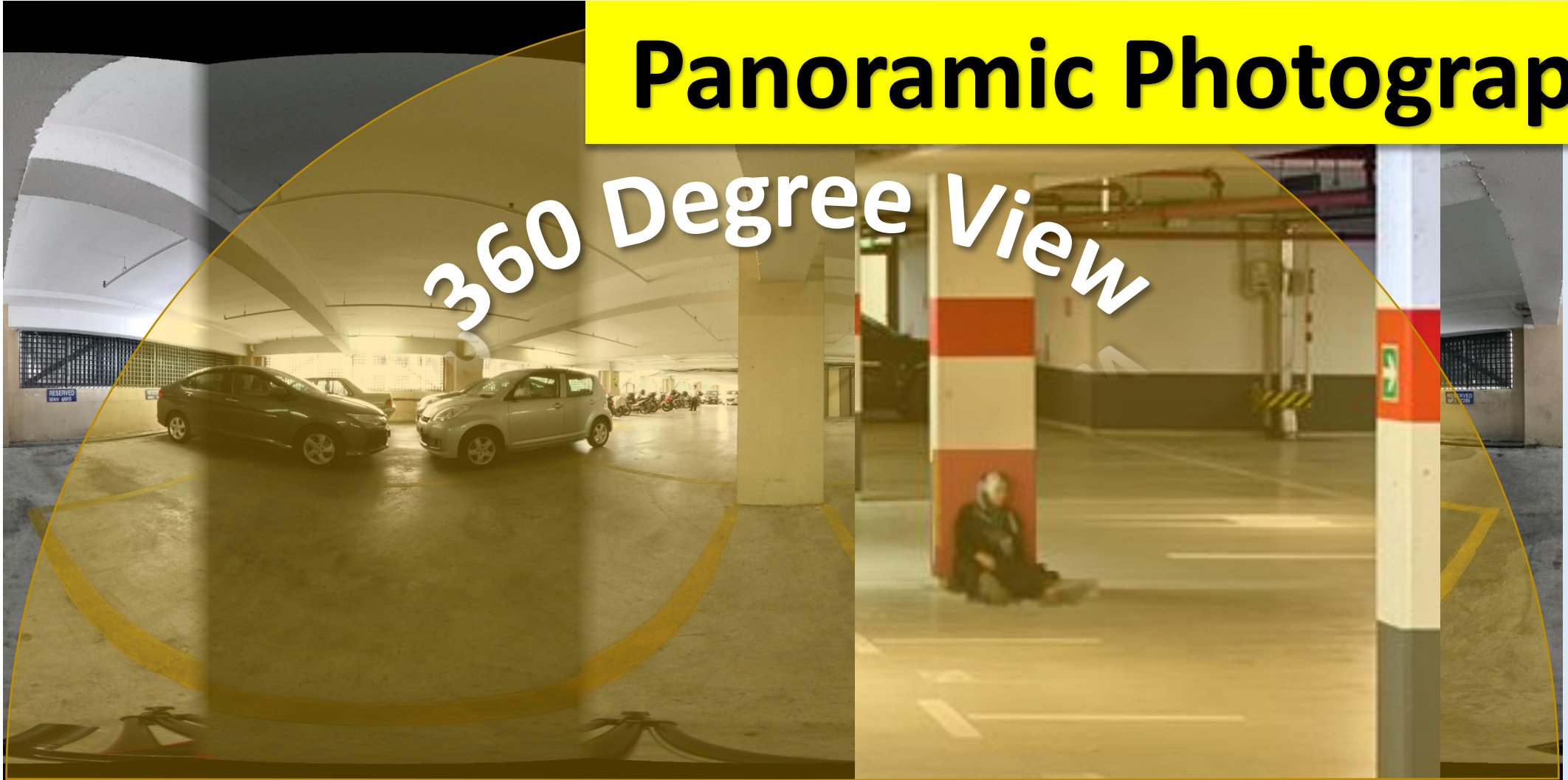


Crime Scene should be Documented





Panoramic Photography

360 Degree View



Detail Photography



Video



Textual Data

*South area of the Parking close
To the entrance 55.
Body of a young lady found leaning to the pillar*

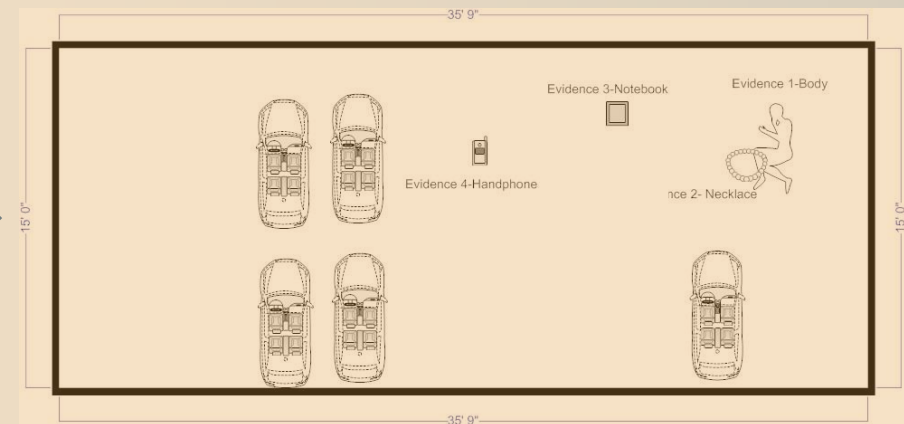
Transcription


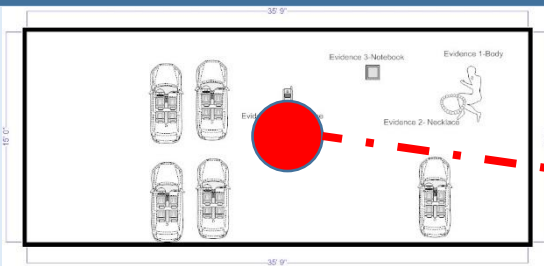
South area of the Parking
Close To the entrance 55.
Body of a young lady found
leaning to the pillar



[illegible]

The diagram illustrates a process flow. A blue arrow enters from the top left, curves downwards, and points into a grey rectangular box labeled "Digitization". From the bottom of this box, a green arrow curves downwards and points to the right, leading towards a yellow rectangular box labeled "Digitalization". The entire process is set against a light blue background with a faint grid. A red dashed line runs horizontally across the middle of the diagram, separating the "Digitization" box from the "Digitalization" box.





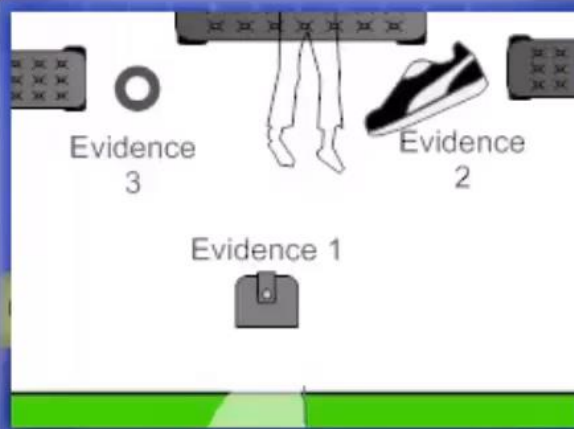
South area of the Parking close
To the entrance 55.
Body of a young lady found
leaning to the pillar



Consolidated Report



iCRIME SCENE INVESTIGATION



Two female bodies found in separate locations . First victim found at the Level 1 car park of the Mines Waterfront Business Park, Block C building. Whilst second body



Pano 1



Pano 1-RK

Crime Scene Digital Documentation **Service**



**All documents in
Digital**

**Forensic Backend
Services**


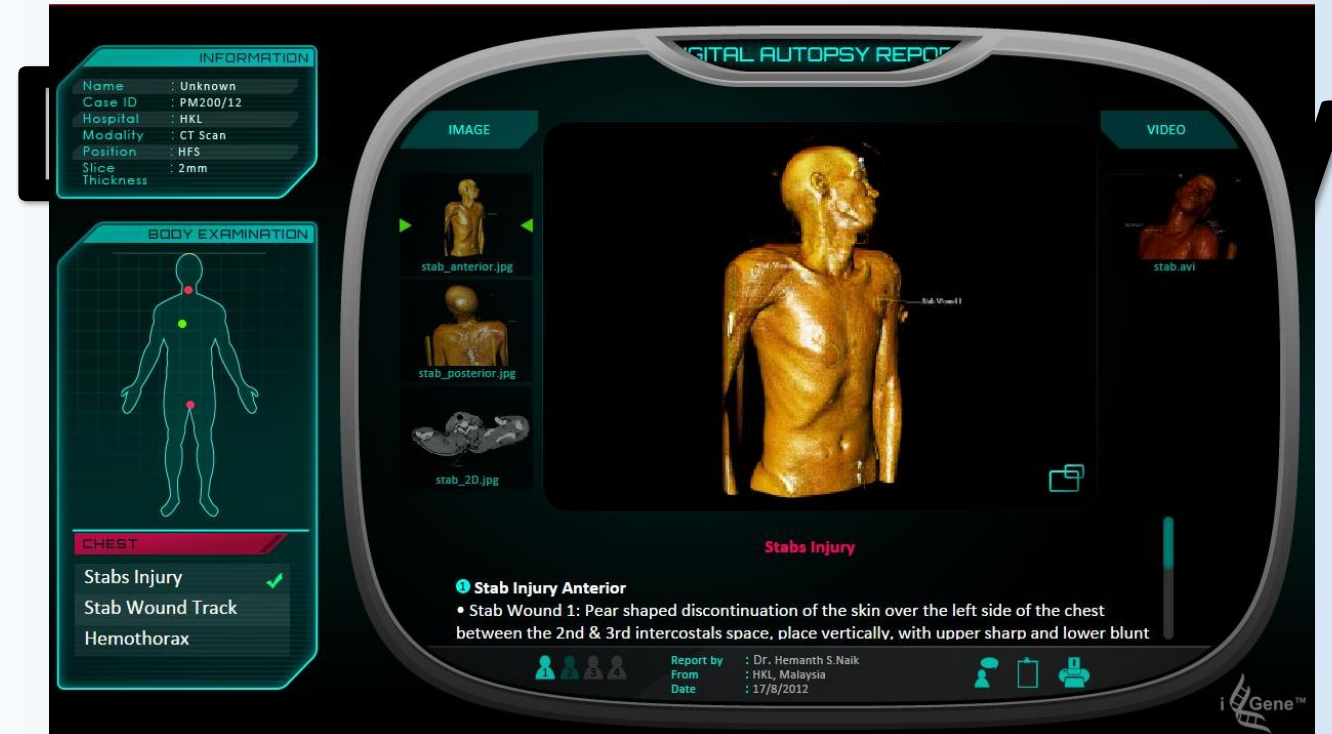
Receive your Report




Increase Analytical Value

integrate

Consolidated Report



South area of the Parking close To the entrance 55.
Body of a young lady found leaning to the pillar



Body Sent for Autopsy



Autopsy

Conventional

Digital



DEAD BODY DETAILS

Fields marked with () are mandatory*

CORONER'S DETAILS

Fields marked with () are mandatory*

Coroner's Name *

Select Coroner



Coroner's Summary



Send Request to Scanner

Scanner (Modality) Scheduling



Digital Autopsy

CT Scanning

Digitization

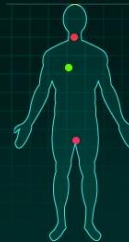Analysis

Multimedia
Report

INFORMATION

Name	: Unknown
Case ID	: PM200/12
Hospital	: HKL
Modality	: CT Scan
Position	: HFS
Slice Thickness	: 2mm

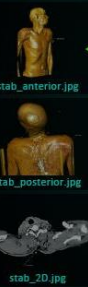BODY EXAMINATION



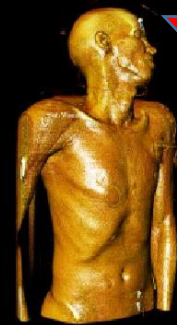CHEST

Stabs Injury	✓
Stab Wound Track	
Hemothorax	

IMAGE



VIDEO



Stabs Injury

Stab Injury Anterior

Stab Wound 1: Pear shaped discontinuation of the skin over the left side of the chest between the 2nd & 3rd intercostals space, place vertically, with upper sharp and lower blunt



Report by : Dr. Hemanth S.Naik
From : HKL, Malaysia
Date : 17/8/2012



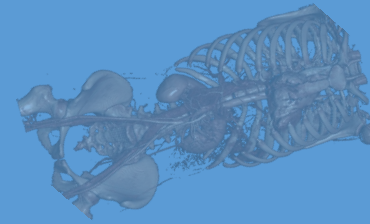
Stab

Stab Wound 2

Stab Wound 1



St



media port

VIDEO



stab.avi



side of the chest
sharp and lower blunt



Case Id: DAF_iGene/10101/2015
Reg. Date & Time: 14/09/2015 11:44AM

CASE DETAILS

CLINICAL HISTORY

RADIOLOGY FINDINGS

RADIOLOGY CORRELATION


SUGGESTED CAUSE OF DEATH

REPORT SIGN OFF

Search Page

Home > Gallery > Hospital

Hospital Images - at HKL



REPORT SIGN OFF



Digital Autopsy

Identification

Data
CT Scanning

Summary

Photographs

Digitization

Analysis

Videos

Multimedia

Textual Report

INFORMATION

Name	: Unknown
Case ID	: PM200/12
Hospital	: HKL
Modality	: CT Scan
Position	: HFS
Slice Thickness	: 2mm

BODY EXAMINATION

Stabs Injury
Stab Wound Track
Hemothorax

Stab Injury Anterior

Stab Wound 1: Pear shaped discontinuation of the skin over the left side of the chest between the 2nd & 3rd intercostals space, place vertically, with upper sharp and lower blunt

Report by : Dr. Hemanth S. Naik
From : HKL, Malaysia
Date : 17/8/2012

Identification

Case ID: PM200/12
Hospital: HKL
Modality: HFS
Position: HFS
Slice: 2mm
Thickness:

Data

BODY EXAMINATION



Summary

Stabs Injury ✓
Stab Wound Track
Hemothorax

DIGITAL AUTOPSY REPORT

IMAGE

Photographs

stab_01.jpg
stab_02.jpg
stab_03.jpg
stab_04.jpg
stab_05.jpg
stab_06.jpg
stab_07.jpg
stab_08.jpg
stab_09.jpg
stab_10.jpg
stab_11.jpg
stab_12.jpg
stab_13.jpg
stab_14.jpg
stab_15.jpg
stab_16.jpg
stab_17.jpg
stab_18.jpg
stab_19.jpg
stab_20.jpg



VIDEO

Videos

Textual Report


Stabs Injury

Stab Injury Anterior

Stab Wound 1: Pear shaped discontinuation of the skin on the left side of the chest between the 2nd & 3rd intercostals space, place vertically, with upper sharp and lower blunt

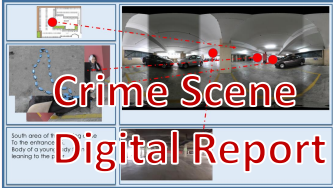

Report by : Dr. Hemant S. Naik
From : HKL, Malaysia
Date : 17/8/2012



**Crime Scene
Digital
Documentation**

**Documentation
Investigation
Reconstruction**



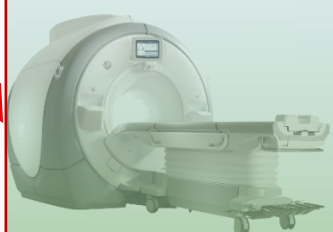
**Case
Registration &
Management**

Chain of Custody



**Multi
Modality
Management**

**Platform
Independent**



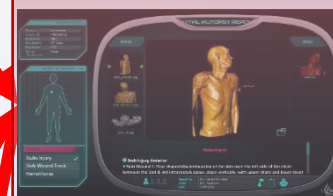**Multi User
Visualization**

**Anytime
Anywhere**



**Multimedia
Integrated
Reports**

**Objective
Transparent
Integrity**



**Multi
Customer
Management**

**Social Justice
Efficiency
Effective**





THANK YOU