

Blood morphology in practice: From smear to clinical insight

Presenter: Marta Costa

DVM MSc FRCPath DipECVCP MRCVS

Clinical Pathologist, & UK Deputy Head of Veterinary Clinical Microbiology

Date: 11th June 2026

The IDEXX logo is rendered in a bold, black, sans-serif font. The letters are closely spaced, with the 'I' and 'D' being particularly prominent. The 'X' is formed by two intersecting diagonal lines.

Disclosure:
Full-time Employee of IDEXX



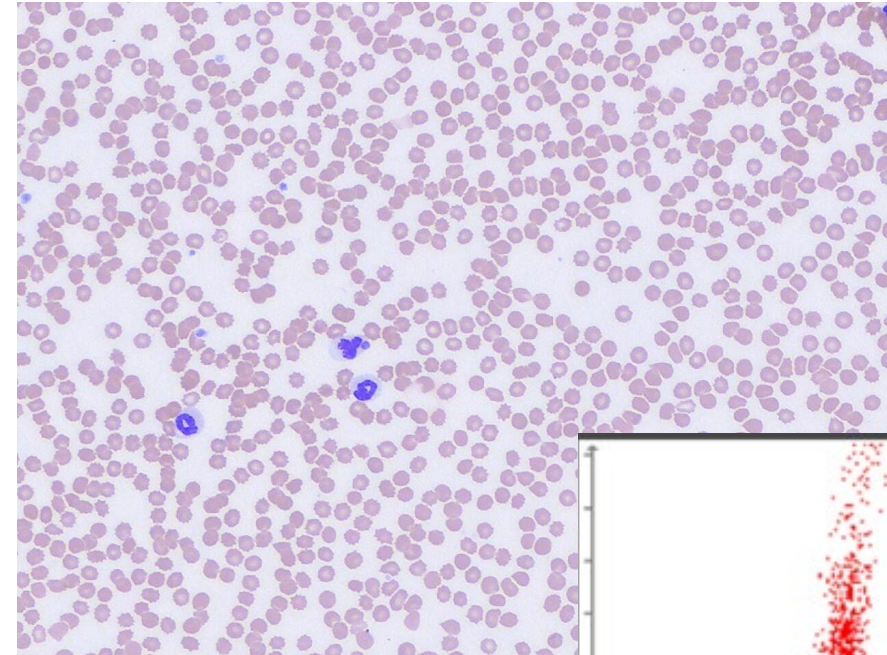
The information contained herein is intended to provide general guidance only. As with any diagnosis or treatment you should use clinical discretion with each patient based on a complete evaluation of the patient, including history, physical exam and presentation, and laboratory data. With respect to any drug therapy or monitoring program, you should refer to applicable product insert(s) for complete description of dosage, indications, interactions, and cautions. Diagnosis, treatment, and monitoring should be patient specific and is the responsibility of the veterinarian providing primary care. (2026)









Haematology is an important diagnostic tool

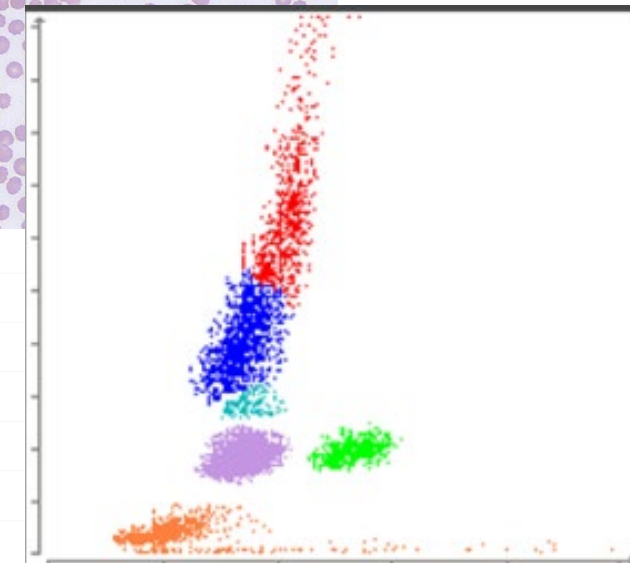
- Part of minimal data base
- Investigation of every sick patient

Components of haematology results

- Automated analysis
 - Numerical values
 - Dot plot analysis
- Blood film evaluation



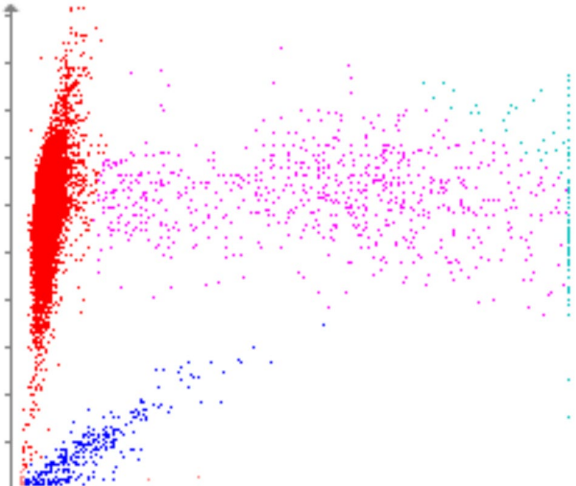
Neutrophils	*19.68	2.95 - 11.64 x10 ⁹ /L	
Lymphocytes	*1.29	1.05 - 5.10 x10 ⁹ /L	
Monocytes	*0.70	0.16 - 1.12 x10 ⁹ /L	
Eosinophils	*0.78	0.06 - 1.23 x10 ⁹ /L	
Basophils	*0.08	0.00 - 0.10 x10 ⁹ /L	
Nucleated RBC	*Suspected		
Platelets	*533	148 - 484 x10 ⁹ /L	
PDW	-	9.1 - 19.4 fL	
MPV	18.7	8.7 - 13.2 fL	
Plateletcrit	1.00	0.14 - 0.46 %	



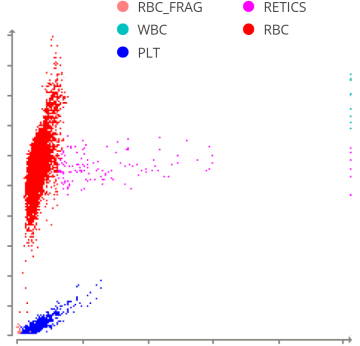
ProCyte Dx™ - Canine Normal WBC Dot Plot

...so much data!

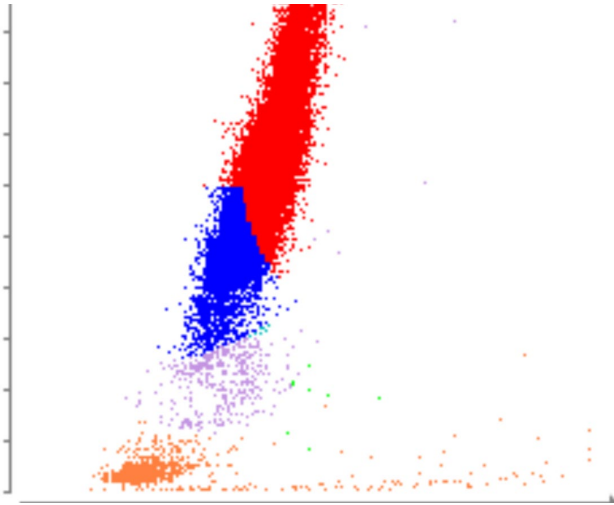
🔊 📉 RBC	3.75	5.65 - 8.87 x10 ¹² /L	
🔊 📉 Haematocrit	0.265	0.373 - 0.617 L/L	
🔊 📉 Haemoglobin	94	131 - 205 g/L	
🔊 📉 MCV	70.7	61.6 - 73.5 fL	
🔊 📉 MCH	25.1	21.2 - 25.9 pg	
🔊 📉 MCHC	355	320 - 379 g/L	
🔊 📉 RDW	18.0	13.6 - 21.7 %	
🔊 % Reticulocyte	3.1	%	
🔊 📉 Reticulocytes	114.8	10.0 - 110.0 K/ μ L	
🔊 📉 Reticulocyte Haemoglobin	26.7	22.3 - 29.6 pg	
🔊 📈 WBC	54.21	5.05 - 16.76 x10 ⁹ /L	
🔊 📉 Neutrophils	*0.82	2.95 - 11.64 x10 ⁹ /L	
🔊 📉 Bands	*Suspected		
🔊 📉 Lymphocytes	*10.93	1.05 - 5.10 x10 ⁹ /L	
🔊 📉 Monocytes	*42.44	0.16 - 1.12 x10 ⁹ /L	
🔊 📉 Eosinophils	0.01	0.06 - 1.23 x10 ⁹ /L	
🔊 📉 Basophils	0.01	0.00 - 0.10 x10 ⁹ /L	
🔊 📉 Platelets	*32	148 - 484 x10 ⁹ /L	
🔊 📉 PDW	-	9.1 - 19.4 fL	
🔊 📉 MPV	17.2	8.7 - 13.2 fL	
🔊 📉 Plateletcrit	0.06	0.14 - 0.46 %	



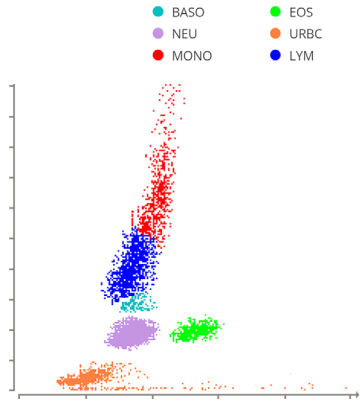
ProCyte Dx™ – Canine Patient RBC Dot Plot



ProCyte Dx - Canine Normal RBC Dot Plot



ProCyte Dx – Canine Patient WBC Dot Plot



ProCyte Dx - Canine Normal WBC Dot Plot

... and many sample features that interfere with automated CBCs

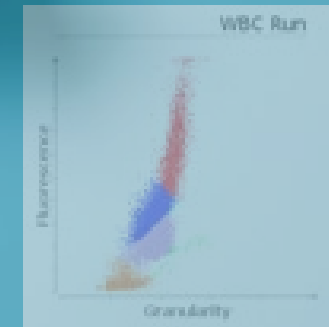
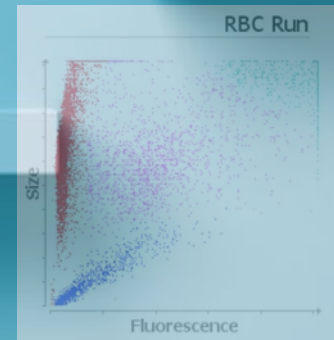
- + Clots
- + Platelet clumps
- + Macroplatelets
- + RBC agglutination
- + nRBC
- + Heinz bodies
- + Lipaemia
- + Leukocyte agglutination
- + Delay in sample handling (increase in MCV, haemolysis, changes in leucocytes, etc)

TIER 1

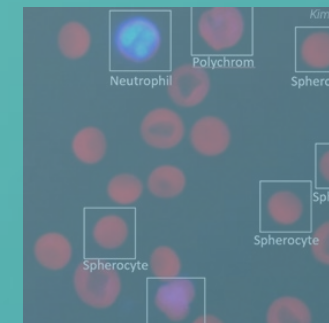

RBC	1.29 MJ/L	5.65 - 8.87	LOW		
HCT	9.8 %	37.3 - 61.7	LOW		
HGB	3.9 g/dL	13.1 - 20.5	LOW		
MCV	89.9 fL	81.6 - 101.5	HIGH		
MCH	35.8 pg	21.2 - 25.9	HIGH		
MCHC	39.8 g/dL	32.0 - 37.9	HIGH		
RDW	*26.3 %	13.6 - 21.7	HIGH		
%RETIC	17.0 %				
RETIC	186.8 K/uL	10.0 - 110.0	HIGH		
RETIC-HGB	25.5 pg	22.3 - 29.6			
WBC	43.20 K/uL	5.05 - 16.76	HIGH		
%NEU	*66.2 %				
%LYM	*21.6 %				
%MONO	*8.9 %				
%EOS	0.2 %				
%BASO	0.1 %				
NEU	*29.88 K/uL	2.95 - 11.84	HIGH		
BAND	*Suspected				
LYM	*9.34 K/uL	1.05 - 5.10	HIGH		
MONO	*3.85 K/uL	0.16 - 1.12	HIGH		
EOS	0.09 K/uL	0.06 - 1.23			
BASO	0.03 K/uL	0.00 - 0.10			
PLT	*60 K/uL	148 - 484	LOW		
MPV	187.7 fL	8.7 - 13.2	HIGH		
PDW	--- fL	9.1 - 19.4			
PCT	0.12 %	0.14 - 0.46	LOW		

* Confirm with dot plot and/or blood film review.

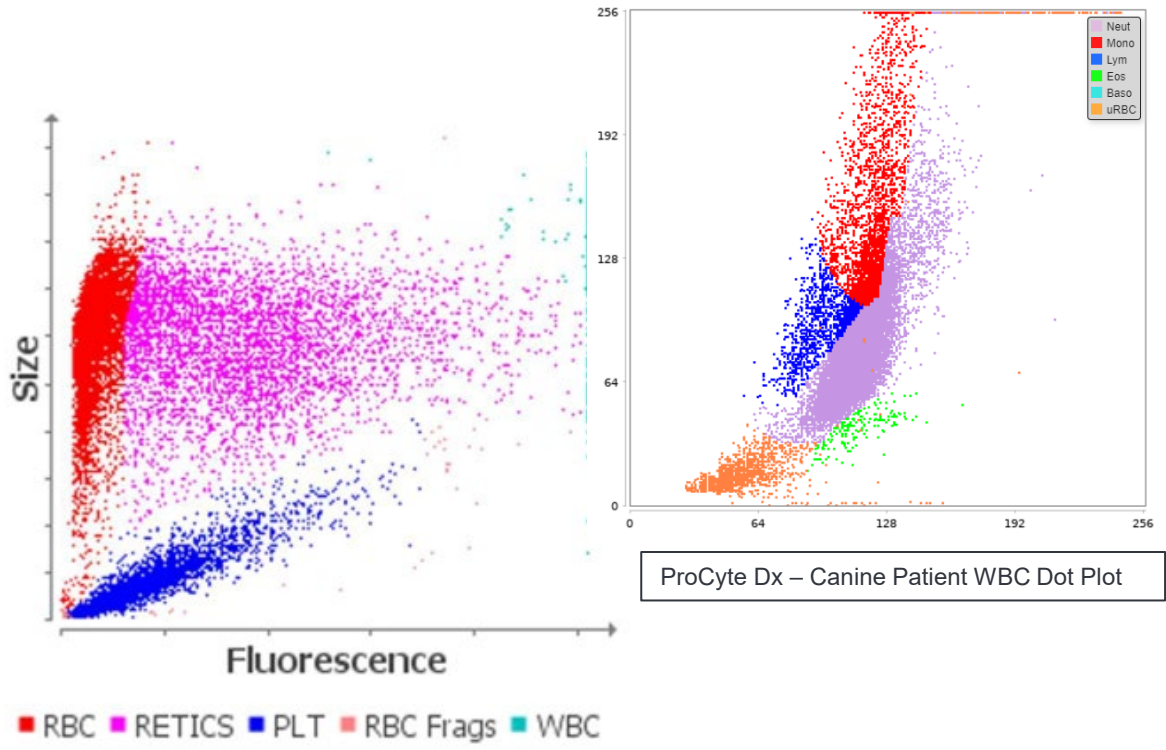
TIER 2



TIER 3



Why is morphological evaluation of cells important?

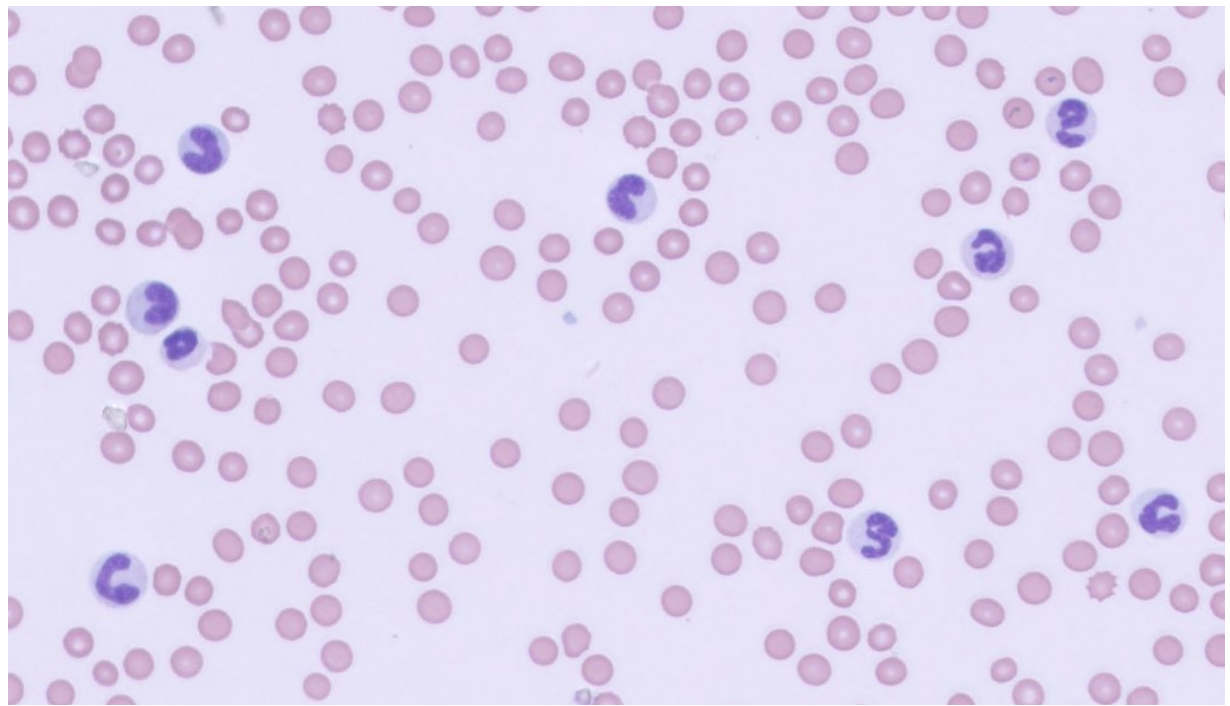


ProCyte Dx – Canine Patient WBC Dot Plot

ProCyte Dx™ – Canine patient RBC Dot Plots

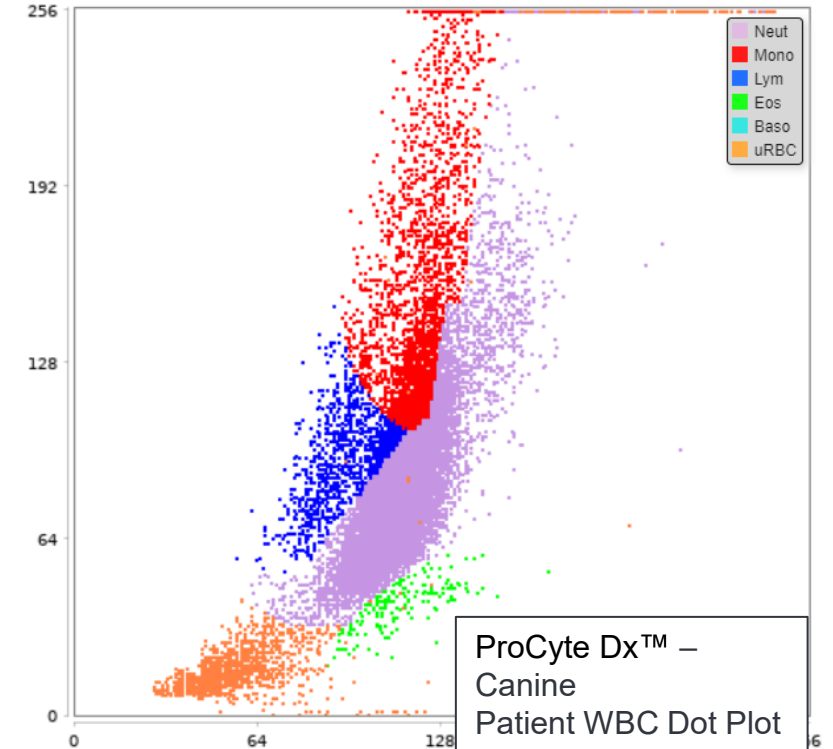
Bands * Suspected

* Confirm with dot plot and/or blood film review.
Immature and/or toxic neutrophils likely present - consider inflammation



When should blood cell morphology be reviewed ?

- Ideally all smears should be evaluated
- Investigation of critically ill patient
- Moderately to severely anaemic patients
- Markedly high WBC counts
- Markedly low WBC/Plt counts
- Flags in dot plots/indistinct separation of clusters
- Unexpected or suspicious instrument results



Bands

*** Suspected**

*** Confirm with dot plot and/or blood film review.**

Immature and/or toxic neutrophils likely present - consider inflammation

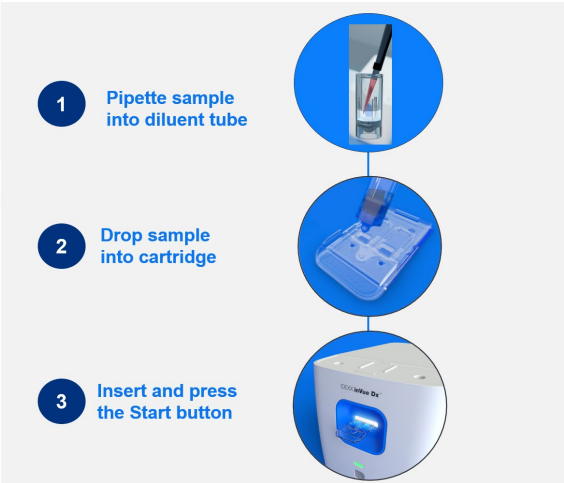
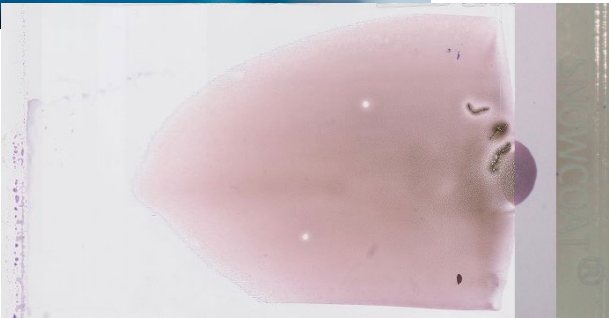ASVCP guidelines

Some suggested numerical guidelines for medical review of blood smear and CBC data

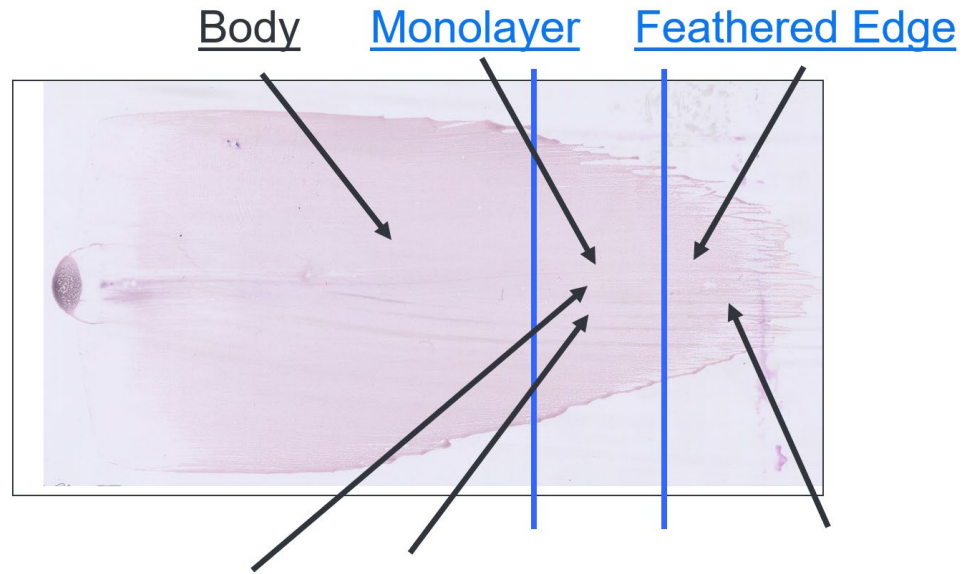
	CRITERIA
WBC	Leukopaenia < 3 x10e9/L
	Leukocytosis > 30 x10e9/L
	Lymphocytosis > 10 x10e9/L
	<i>Any unclassified cells</i>
Platelets	Thrombocytopaenia < 100 x10e9/L
	Thrombocytosis > 900 x10e9/L
	Abnormal MPV (if reported by instrument)
RBC	Moderate to severe anaemia
	>5 nRBC/100WBC
	Abnormal MCV

Modified from ASVCP guidelines: quality assurance for point-of-care testing in veterinary medicine. ASVCP, 2013.

Morphological evaluation of blood cells




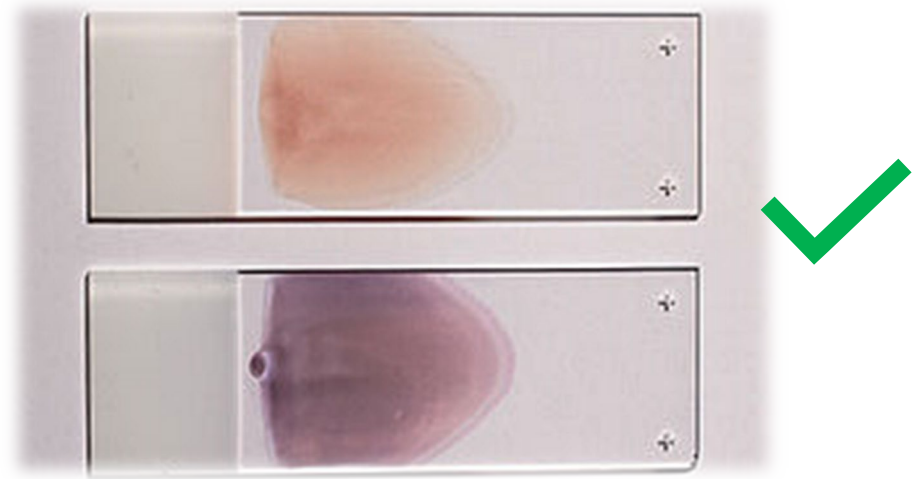
Blood smear



- Rouleaux
- Agglutination

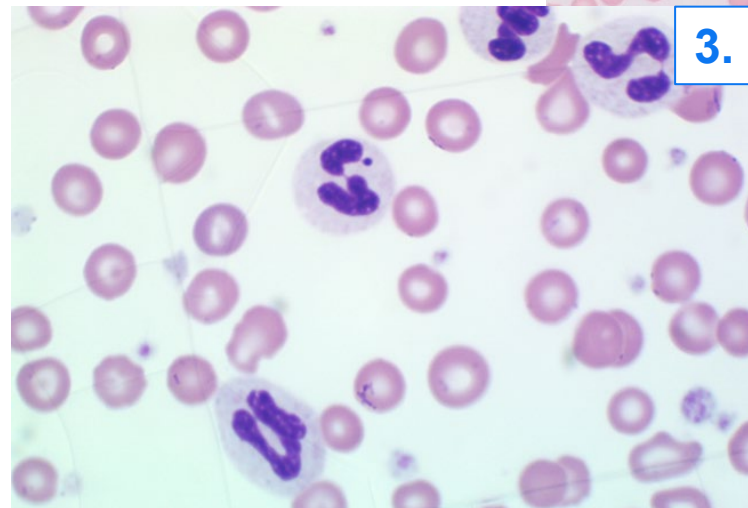
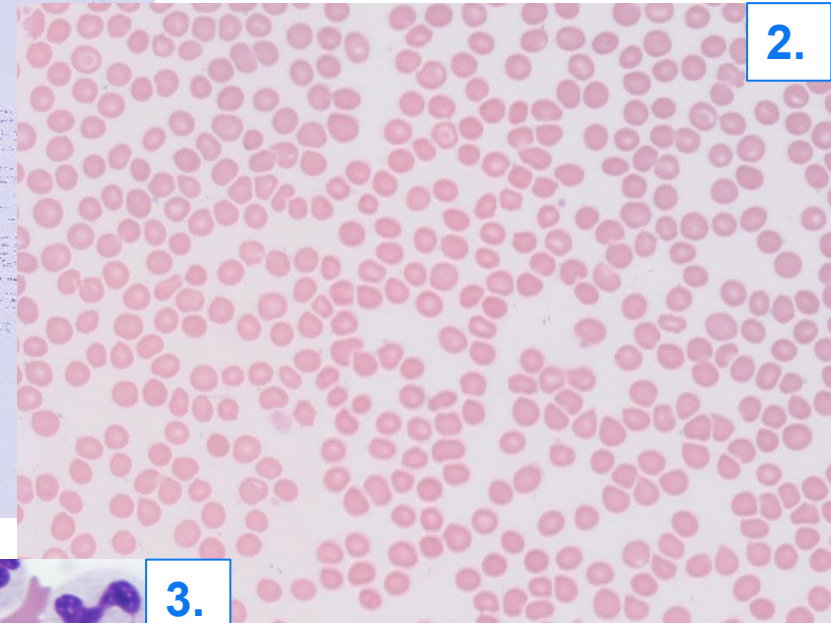

- Estimate numbers
- Morphology

- Platelet clumps
- Large cells
- Microfilaria



Systematic approach to blood smear review

1. Start small – with low magnification (10x) and then feathered edge
2. Go deeper - Go two to three fields back to the body of the smear into the monolayer
3. Go bigger – Increase to oil and evaluate morphology
4. Have a consistent approach:
 - + Platelets
 - + Red Blood Cells
 - + White Blood Cells



Blood smear evaluation steps - Systematic stepwise approach



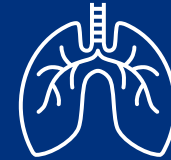Cell distribution

For all cell types:
Agglutination/
aggregation



Platelets

Estimate plt numbers
Examine morphology



Red Blood cells

Evaluate:

- size
- shape
- color
- inclusions



White blood cells

Do or verify differential
cell count
Evaluate morphology
changes and inclusions

LOKI

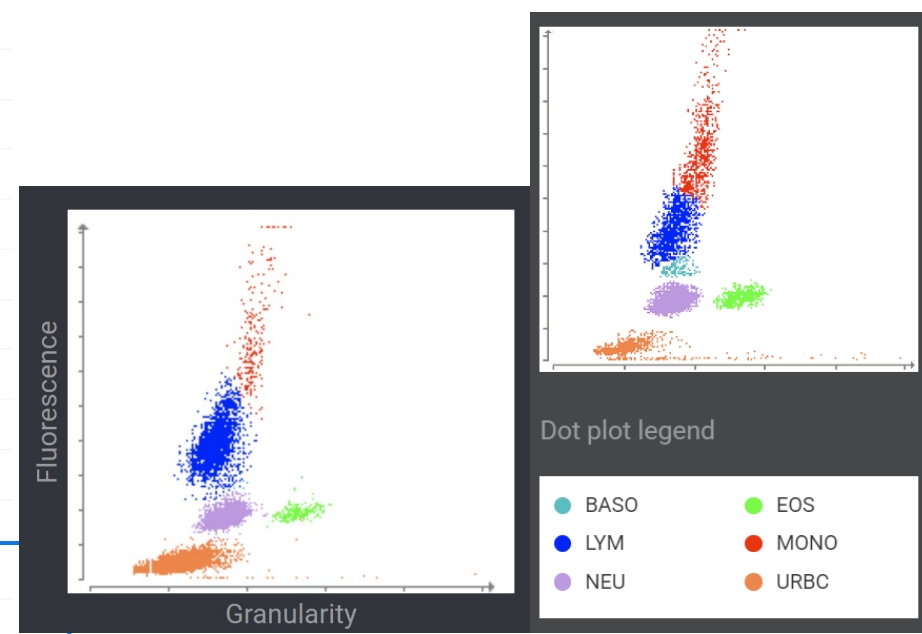
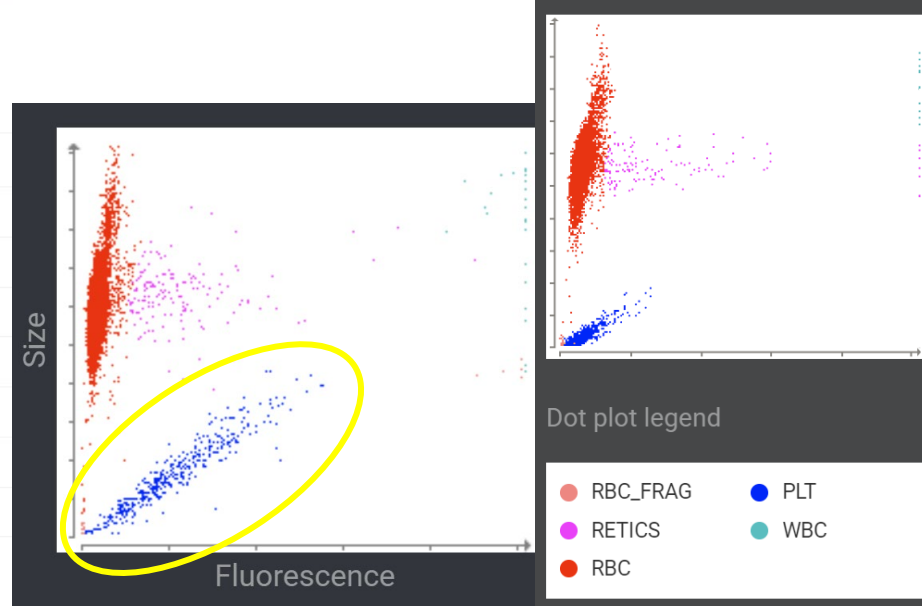
+ 8Y old

+ MN

+ CKCS

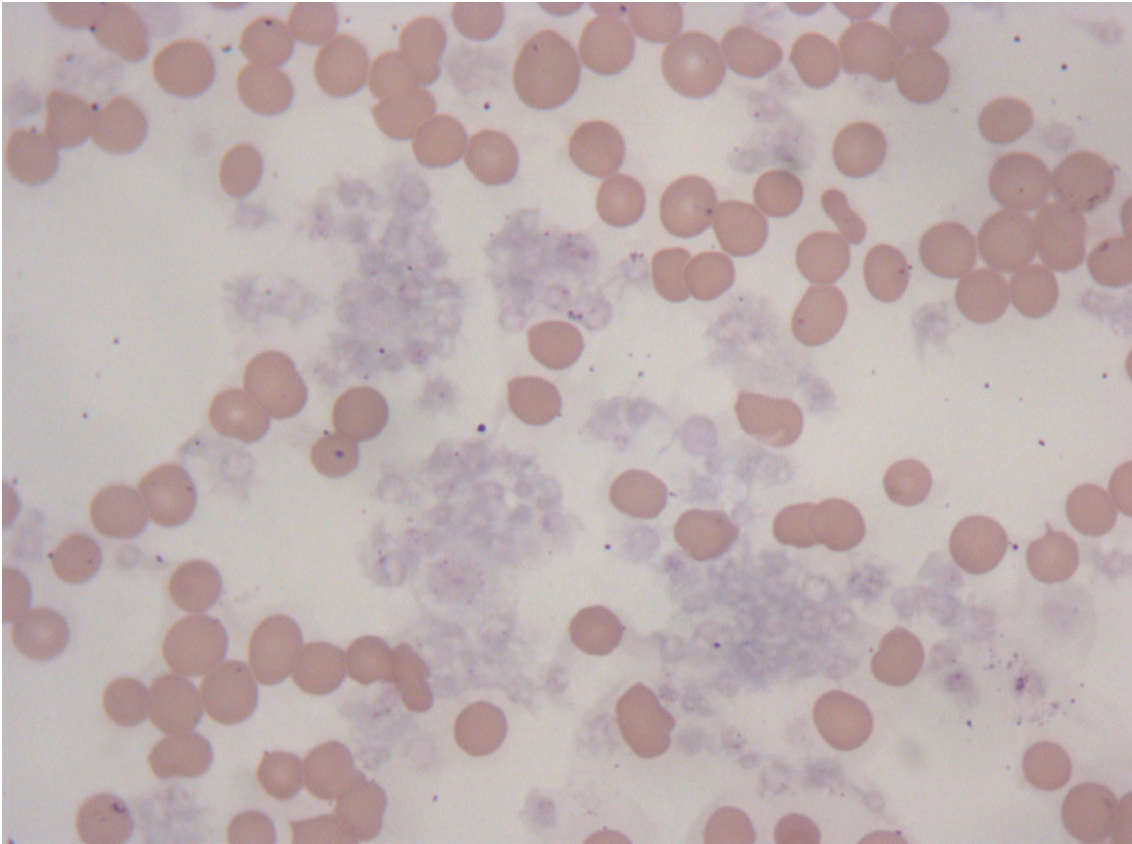
Routine screen

Haematology		24/02/2025 09:56	
RBC	6.56	5.65 - 8.87 x10 ¹² /L	
Haematocrit	0.445	0.373 - 0.617 L/L	
Haemoglobin	152	131 - 205 g/L	
MCV	67.8	61.6 - 73.5 fL	
MCH	23.2	21.2 - 25.9 pg	
MCHC	342	320 - 379 g/L	
RDW	18.0	13.6 - 21.7 %	
% Reticulocytes	0.7	%	
Reticulocytes	43.3	10.0 - 110.0 K/ μ L	
Reticulocyte Haemoglobin	27.3	22.3 - 29.6 pg	
WBC	8.11	5.05 - 16.76 x10 ⁹ /L	
% Neutrophils	57.7	%	
% Lymphocytes	35.4	%	
% Monocytes	3.2	%	
% Eosinophils	3.6	%	
% Basophils	0.1	%	
Neutrophils	4.68	2.95 - 11.64 x10 ⁹ /L	
Lymphocytes	2.87	1.05 - 5.10 x10 ⁹ /L	
Monocytes	0.26	0.16 - 1.12 x10 ⁹ /L	
Eosinophils	0.29	0.06 - 1.23 x10 ⁹ /L	
Basophils	0.01	0.00 - 0.10 x10 ⁹ /L	
Platelets	*66	148 - 484 x10 ⁹ /L	
Platelet Estimate			
PDW	-	9.1 - 19.4 fL	
MPV	24.7	8.7 - 13.2 fL	
Plateletcrit	0.16	0.14 - 0.46 %	

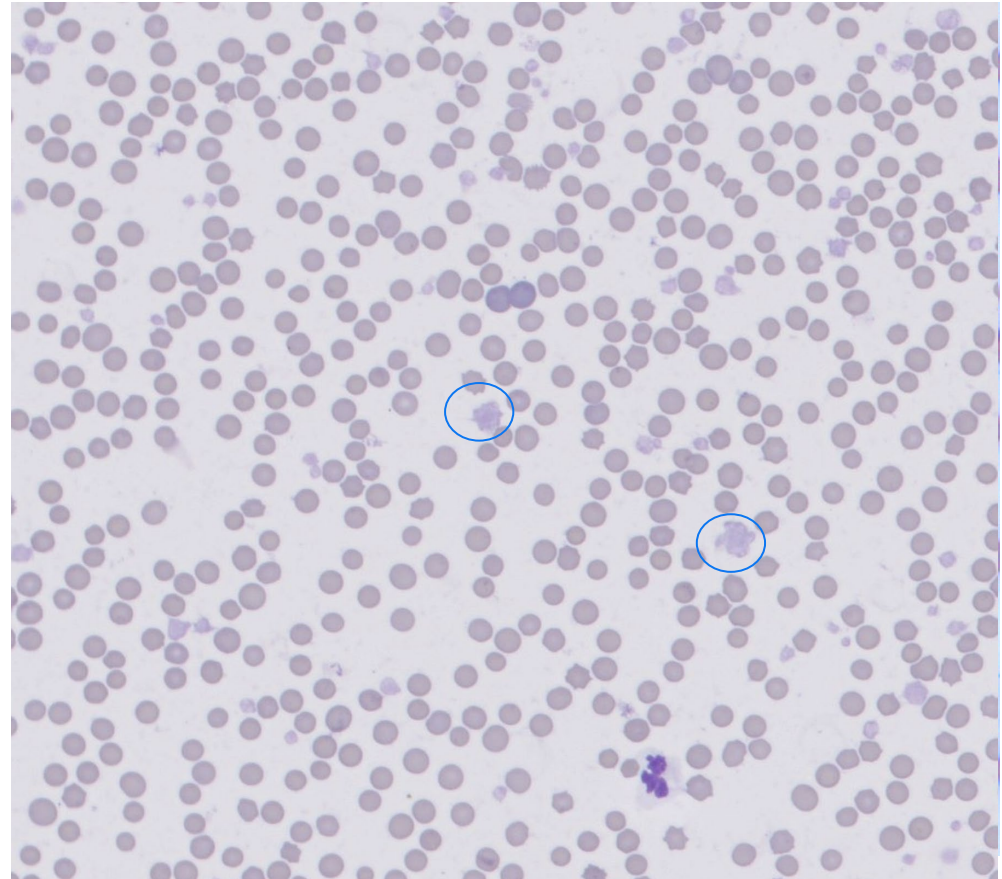


Platelets

Platelet clumps



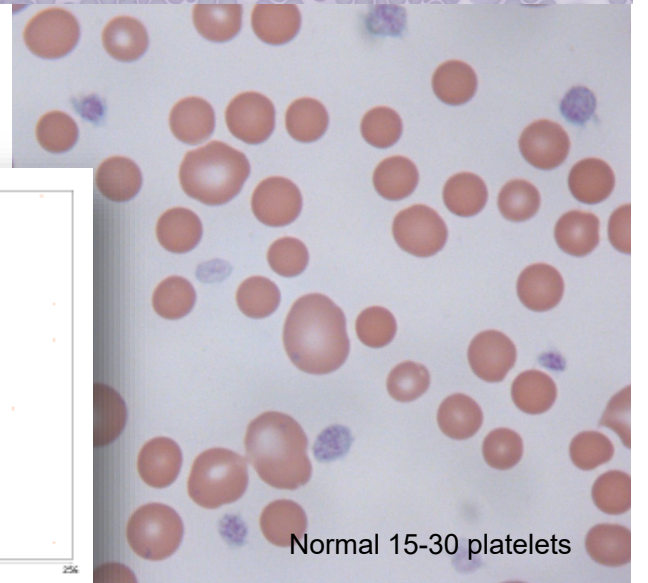
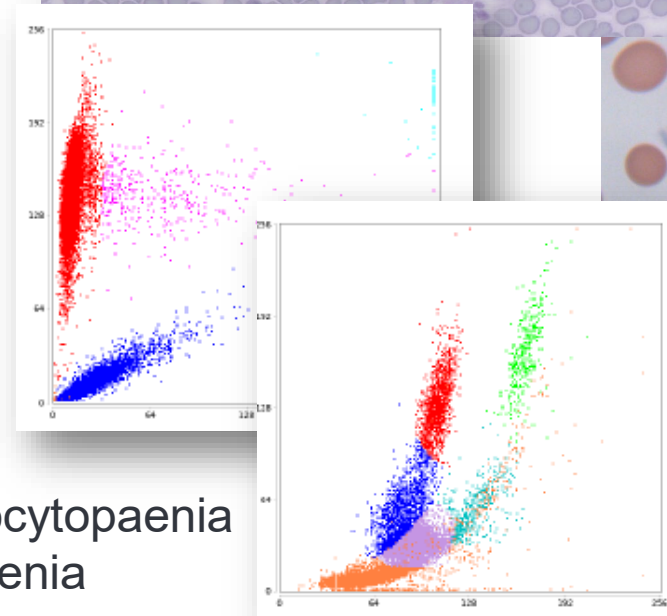
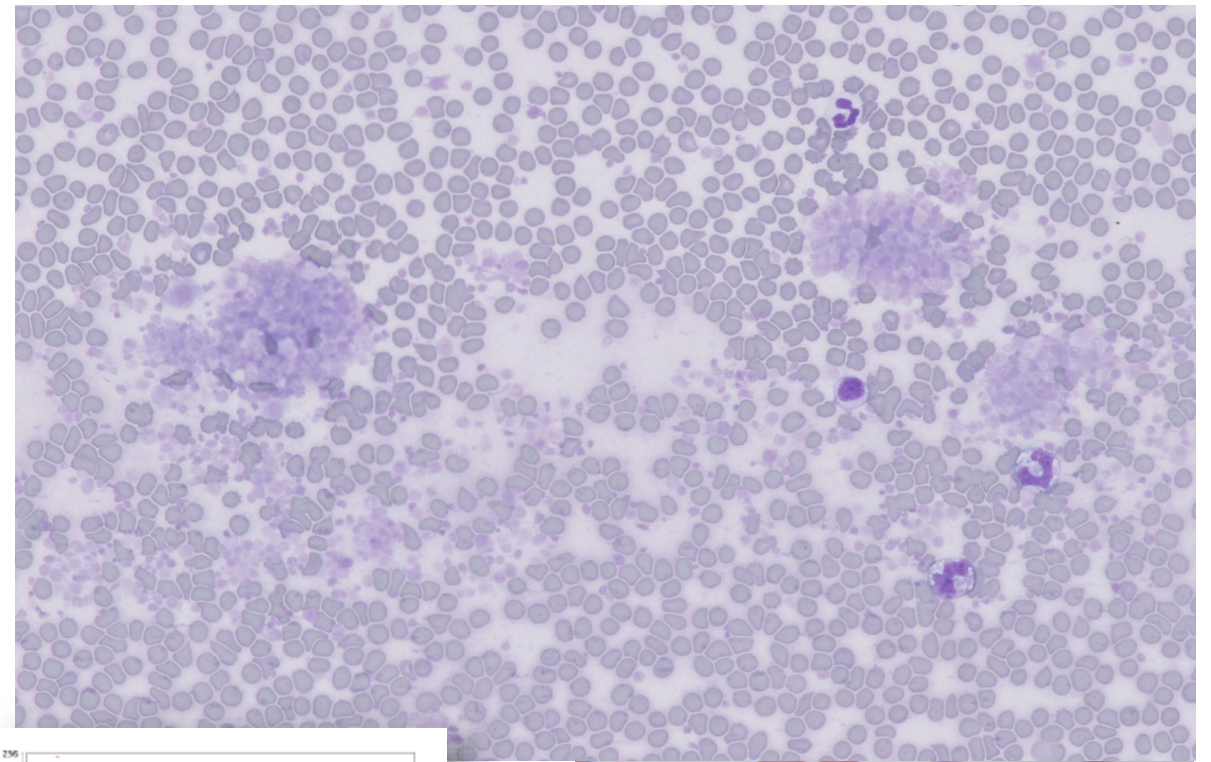
Macroplatelets



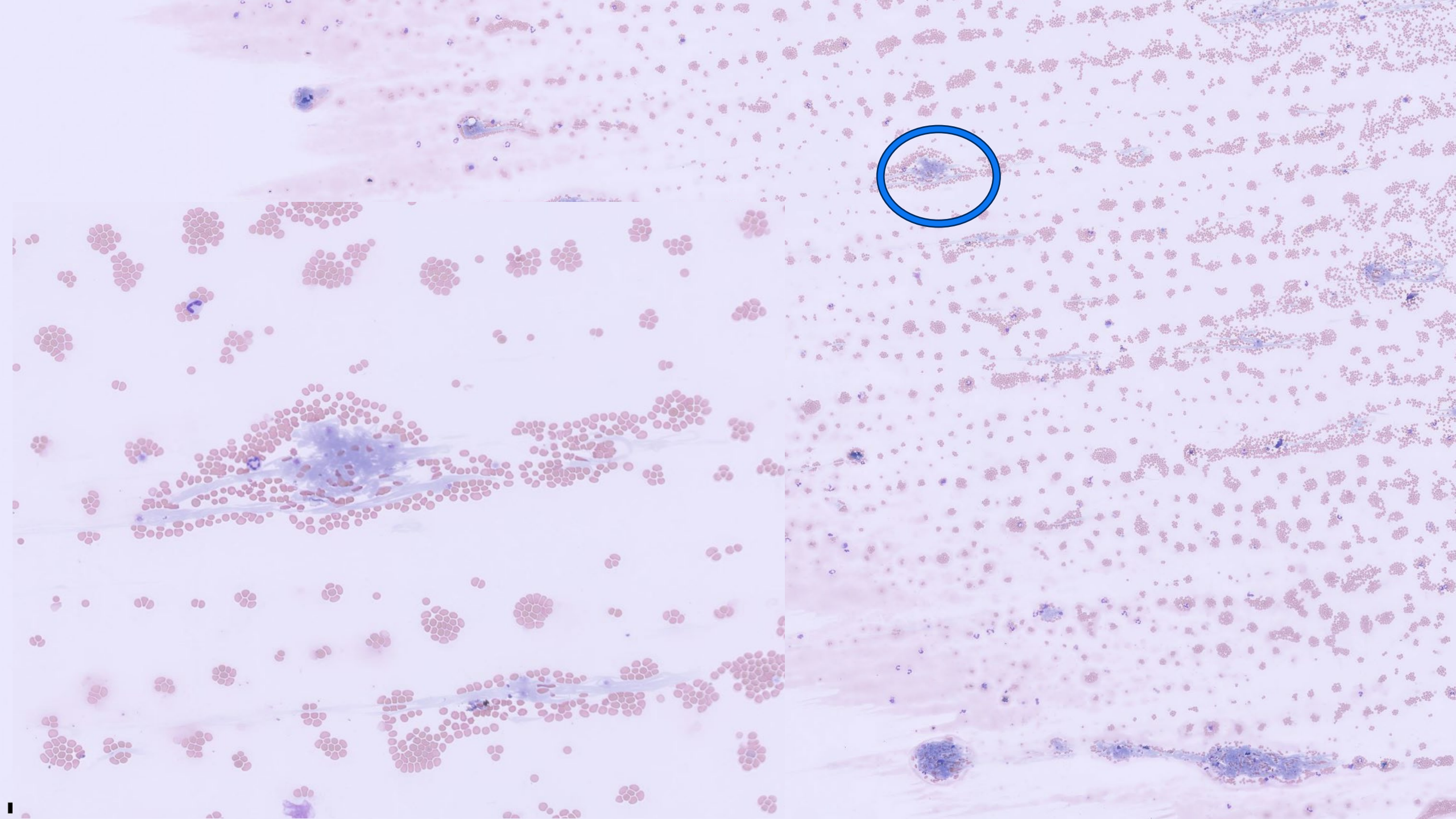Platelet estimates

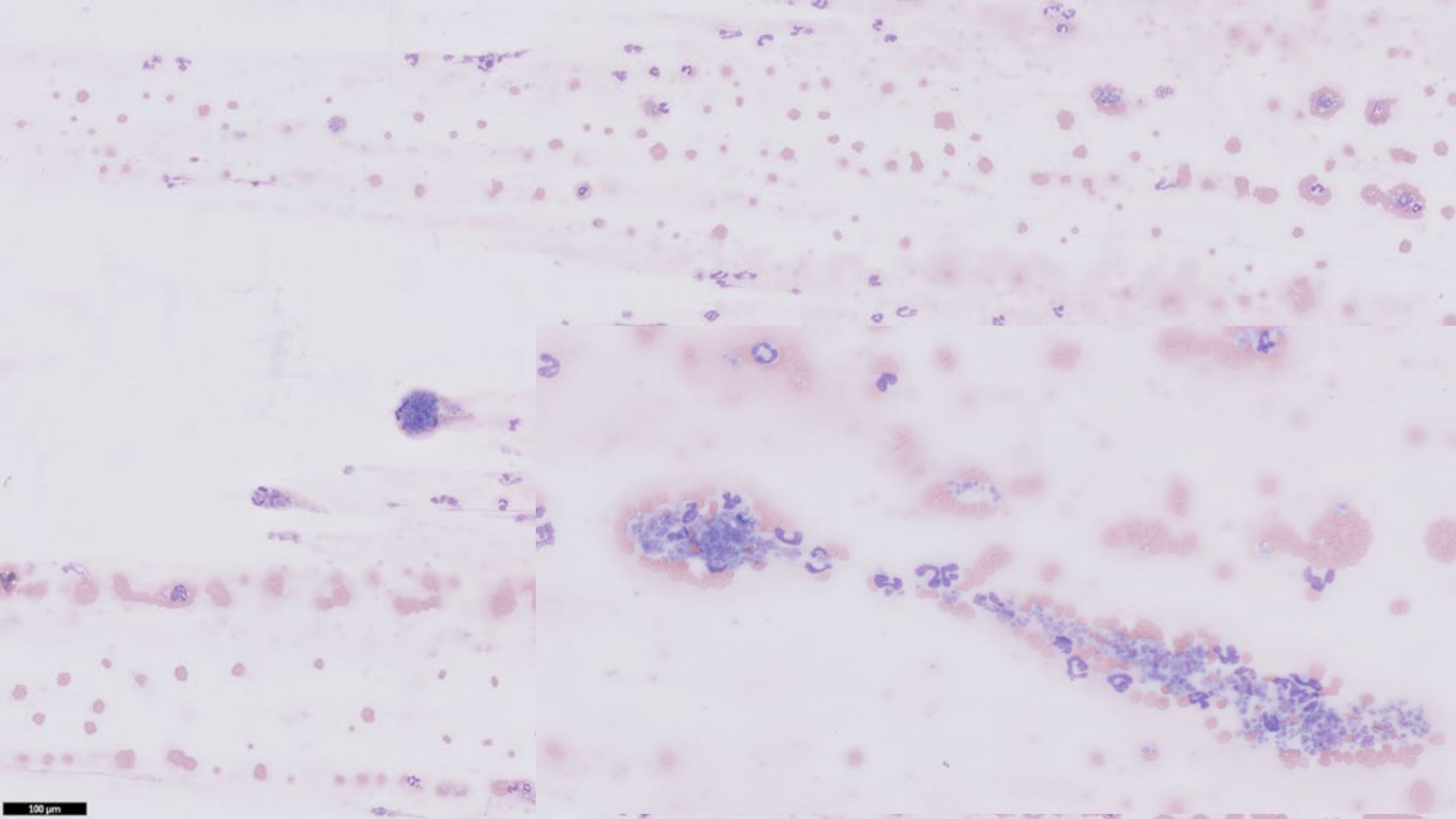
- ✓ Assuming NO PLT CLUMPS in feathered edge and NO CLOTS!
- 1. Count number of platelets in 10 fields oil immersion in monolayer
- 2. Do the average ($\Sigma / 10$)
- 3. Multiply by 15 or 20
- 4. This is the **estimated** number
($\times 10^9/L$)

>10 per HPF = no significant thrombocytopenia
<2 per HPF = marked thrombocytopenia

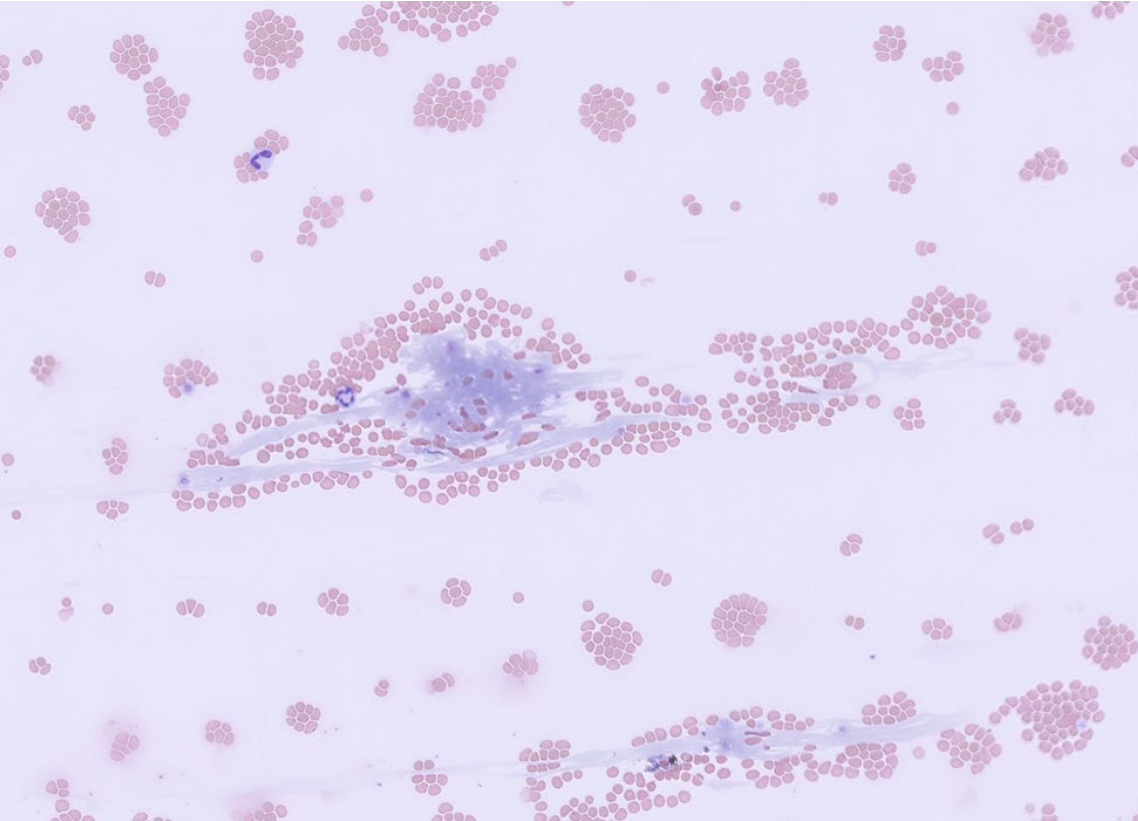


Normal 15-30 platelets

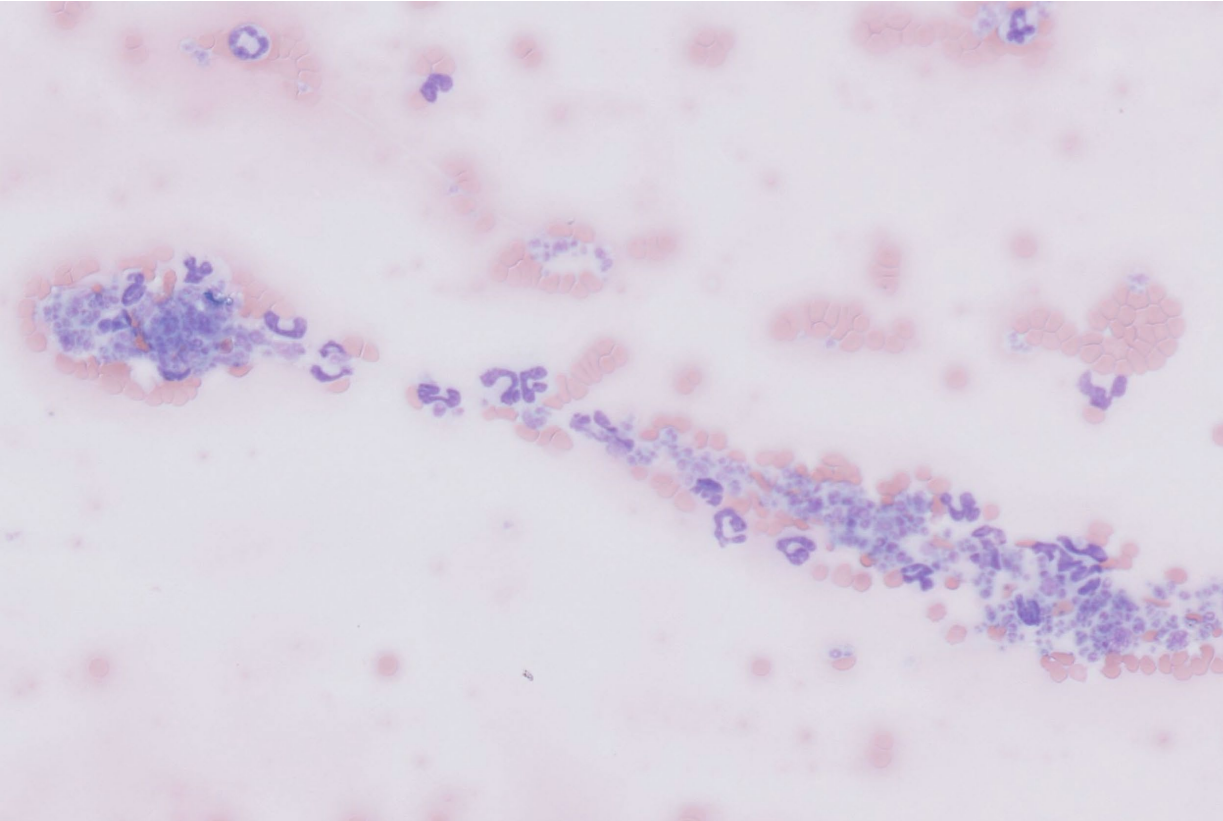




Fibrin strands

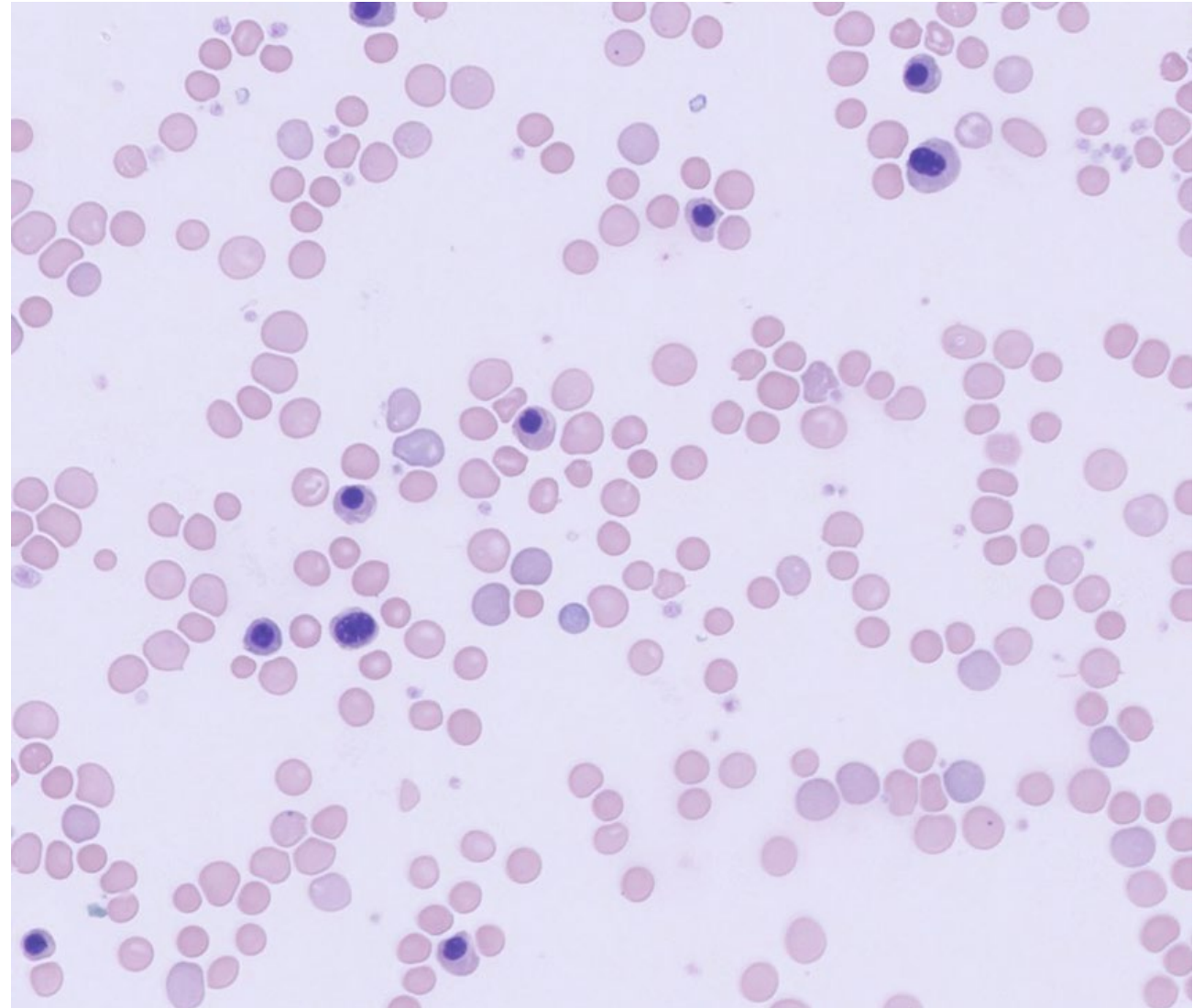


Platelet clumps

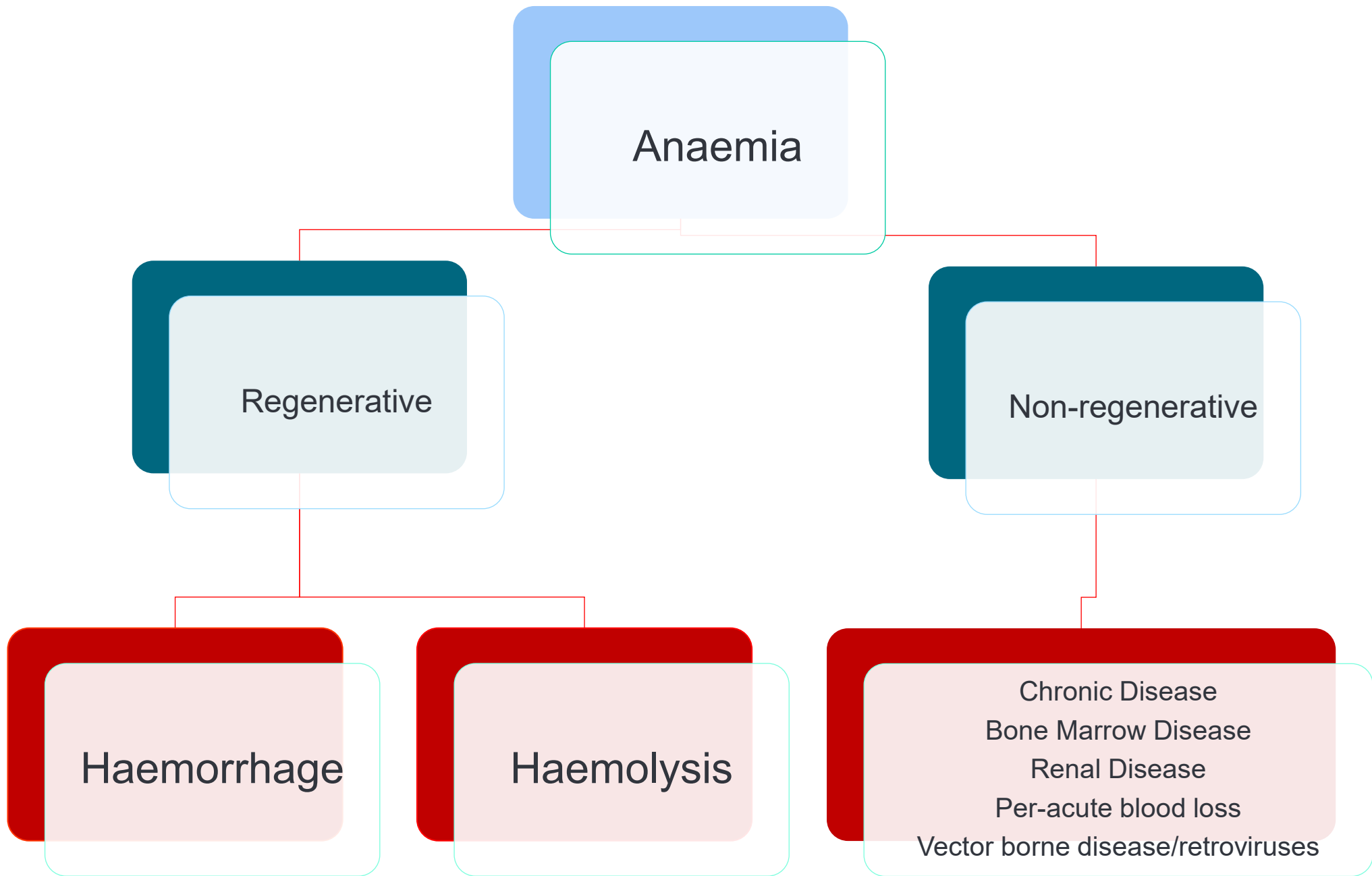


For the RBC we are evaluating 3 main things...

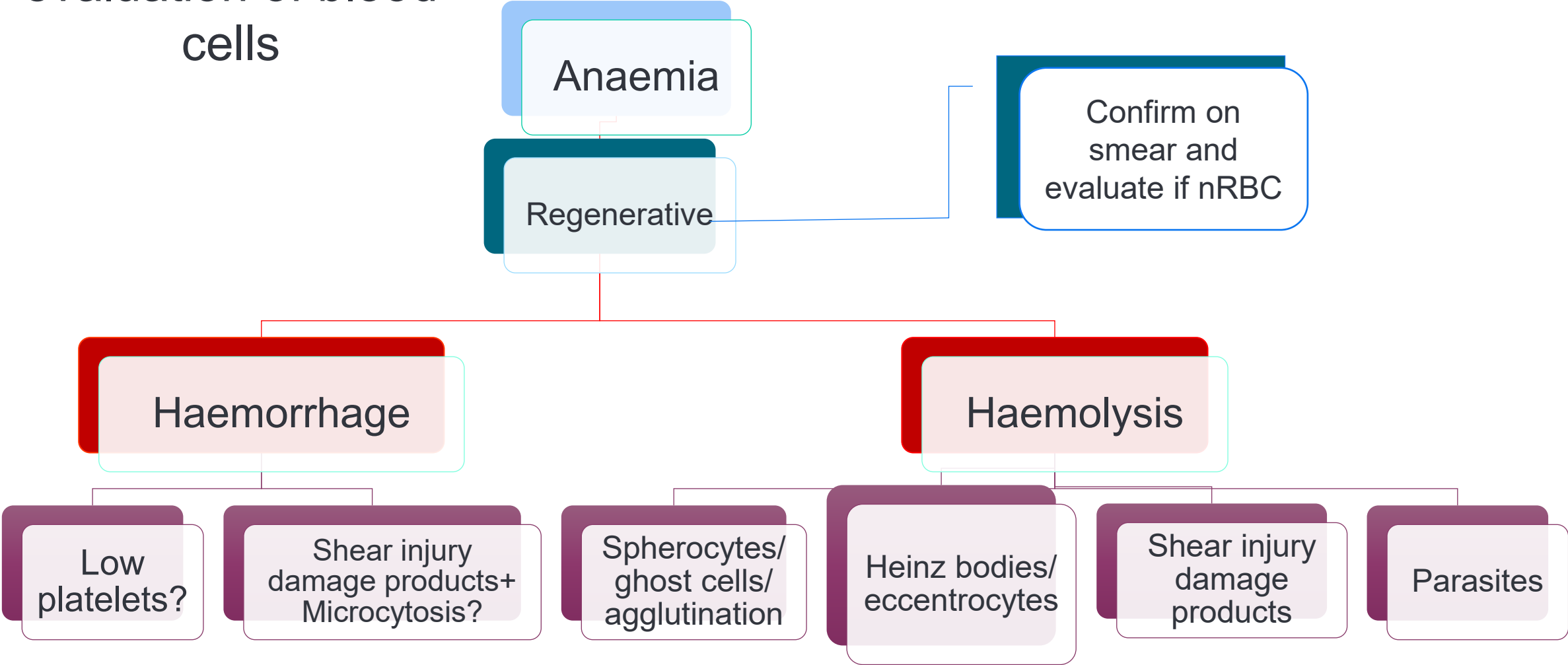
- + Density and spread
 - + Agglutination
 - + Rouleaux
- + Colour
 - + Polychromasia
 - + Hypochromasia
- + Size, shapes and inclusions
 - + nRBC
 - + Heinz bodies
 - + Spherocytes and ghost cells
 - + Poikilocytes



Is the patient anaemic?

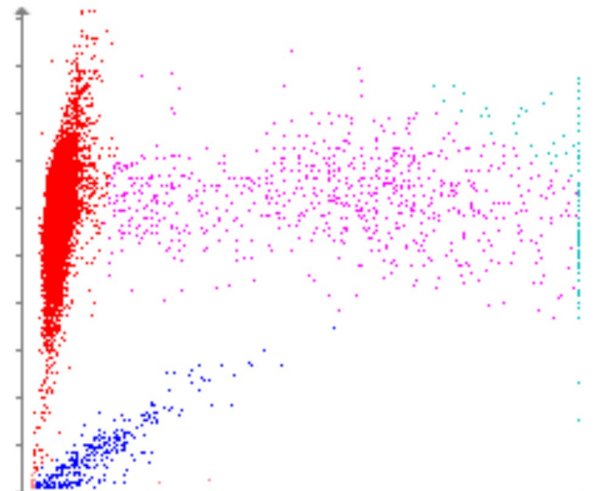
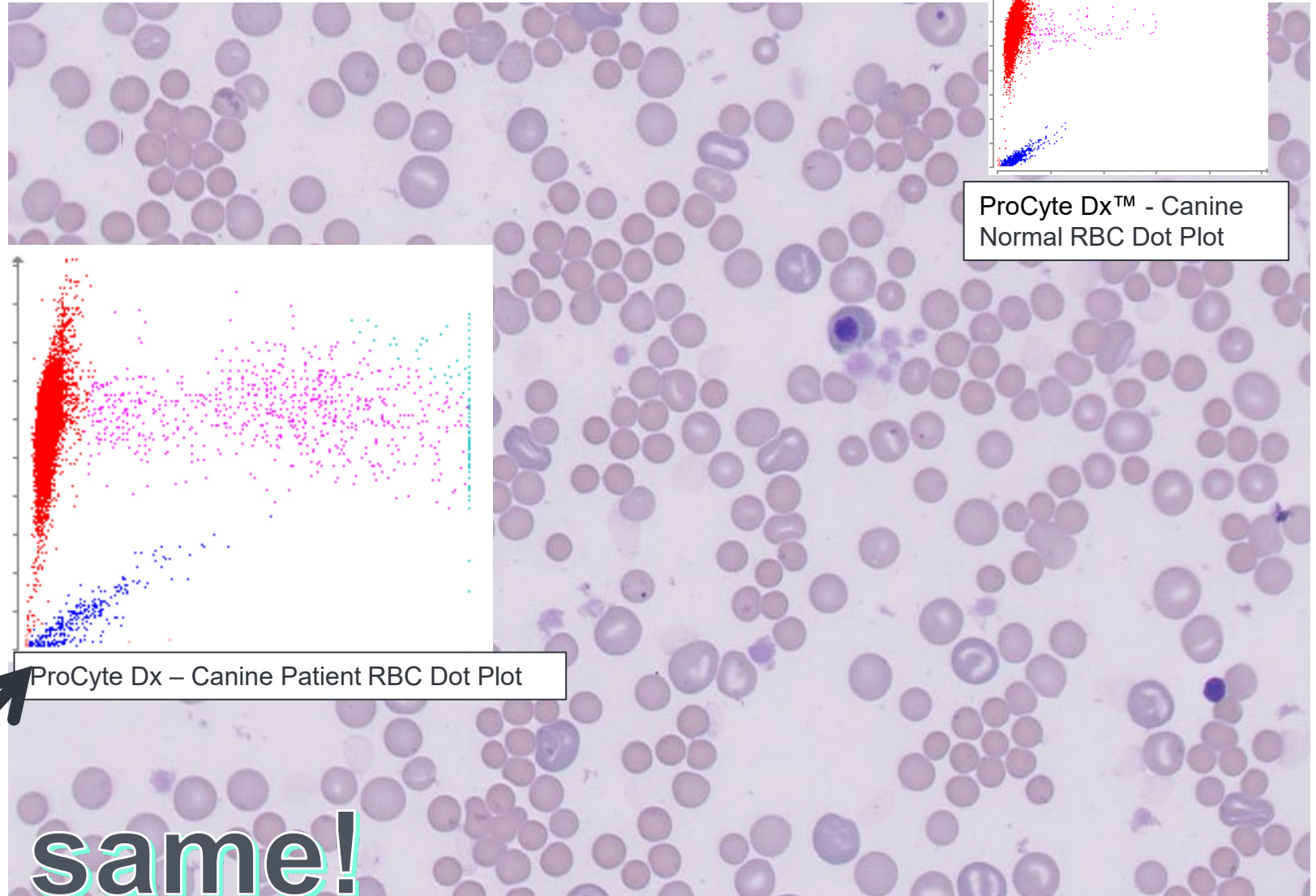
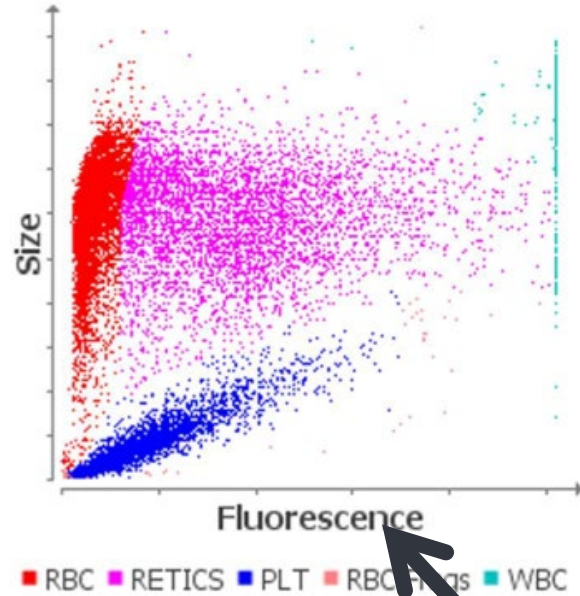


Morphological evaluation of blood cells



Reticulocytes

+ Polychromasia



Not the same!

Charlie

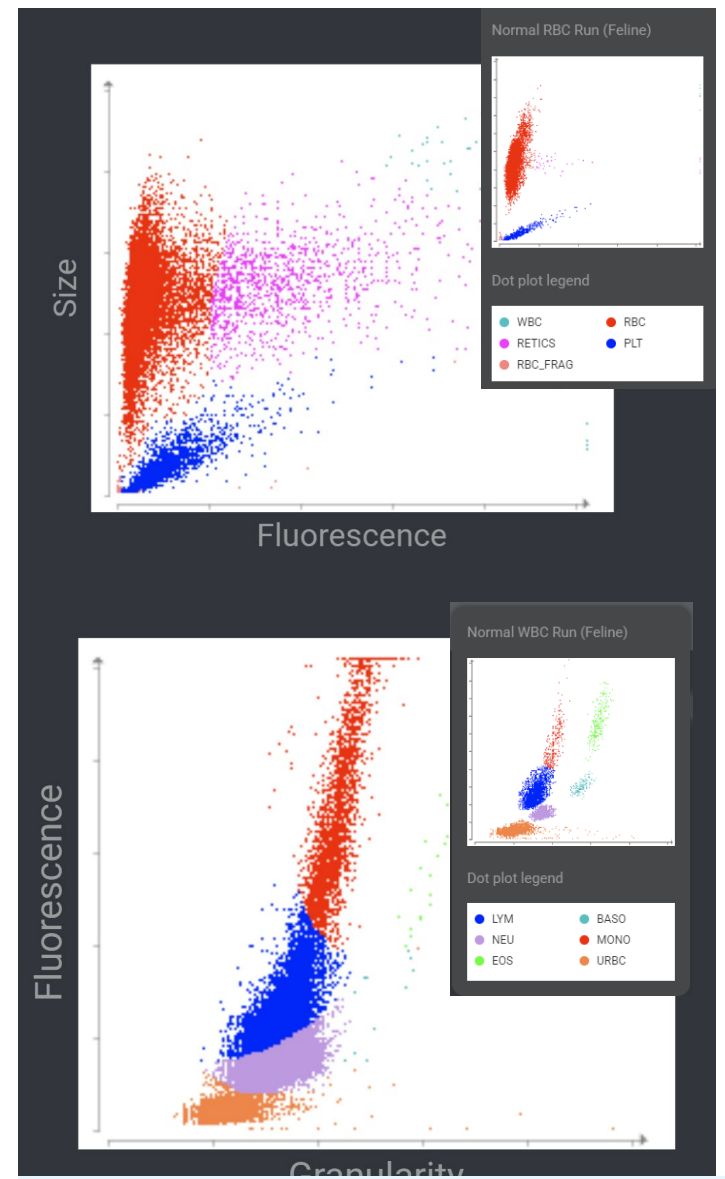
+ 8Y

+ FN

+ DSH

+ No Hx

Haematology		13/05/2026	10:55
RBC	2.25	6.54 - 12.20 x10 ¹² /L	
Haematocrit	0.141	0.303 - 0.523 L/L	
Haemoglobin	39	98 - 162 g/L	
MCV	62.7	35.9 - 53.1 fL	
MCH	17.3	11.8 - 17.3 pg	
MCHC	277	281 - 358 g/L	
RDW	27.8	15.0 - 27.0 %	
% Reticulocytes	6.0	%	
Reticulocytes	134.8	3.0 - 50.0 K/ μ L	
Reticulocyte Haemoglobin	20.5	13.2 - 20.8 pg	
WBC	24.91	2.87 - 17.02 x10 ⁹ /L	
% Neutrophils	*47.7	%	
% Lymphocytes	*39.5	%	
% Monocytes	*12.7	%	
% Eosinophils	0.1	%	
% Basophils	0.0	%	
Neutrophils	*11.88	2.30 - 10.29 x10 ⁹ /L	
Bands	*Suspected		
Lymphocytes	*9.83	0.92 - 6.88 x10 ⁹ /L	
Monocytes	*3.17	0.05 - 0.67 x10 ⁹ /L	
Eosinophils	0.02	0.17 - 1.57 x10 ⁹ /L	
Basophils	0.01	0.01 - 0.26 x10 ⁹ /L	
Platelets	142	151 - 600 x10 ⁹ /L	
MPV	18.6	11.4 - 21.6 fL	
Plateletcrit	0.26	0.17 - 0.86 %	

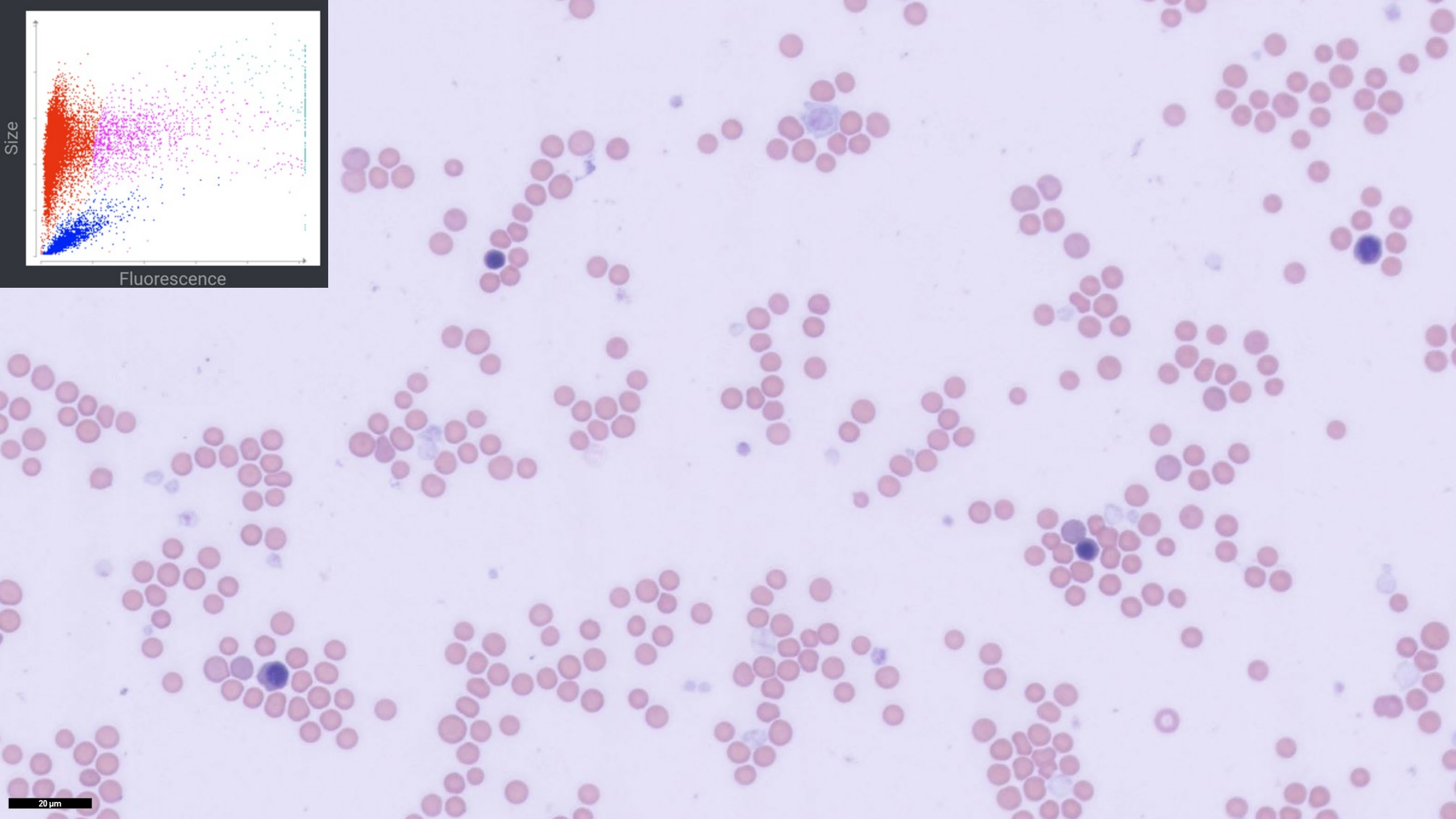
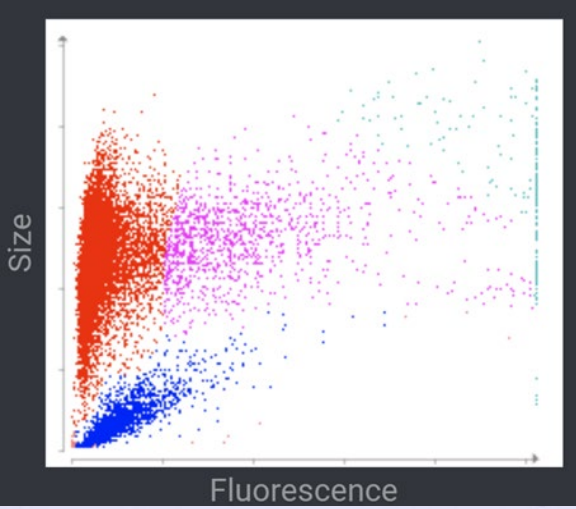


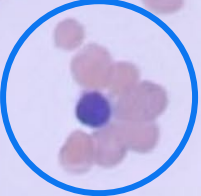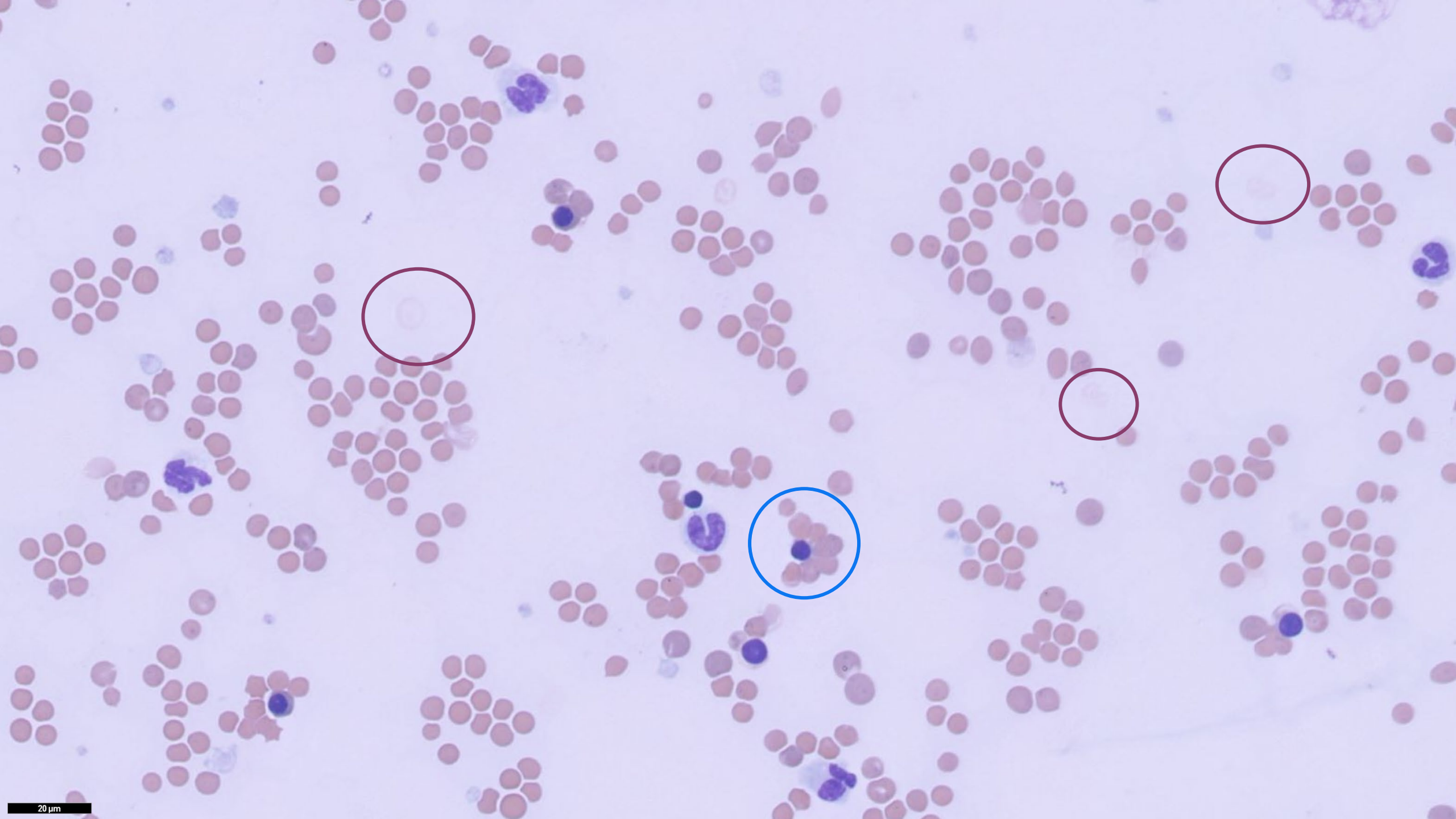
* Confirm with dot plot and/or blood film review.

Immature and/or toxic neutrophils likely present - Consider inflammation.

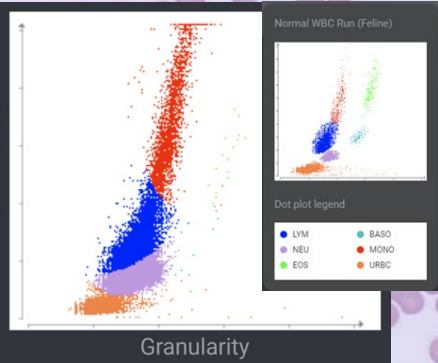
Anemia with reticulocytosis - Likely regenerative anemia.

Normal PCT - Likely adequate platelet mass.

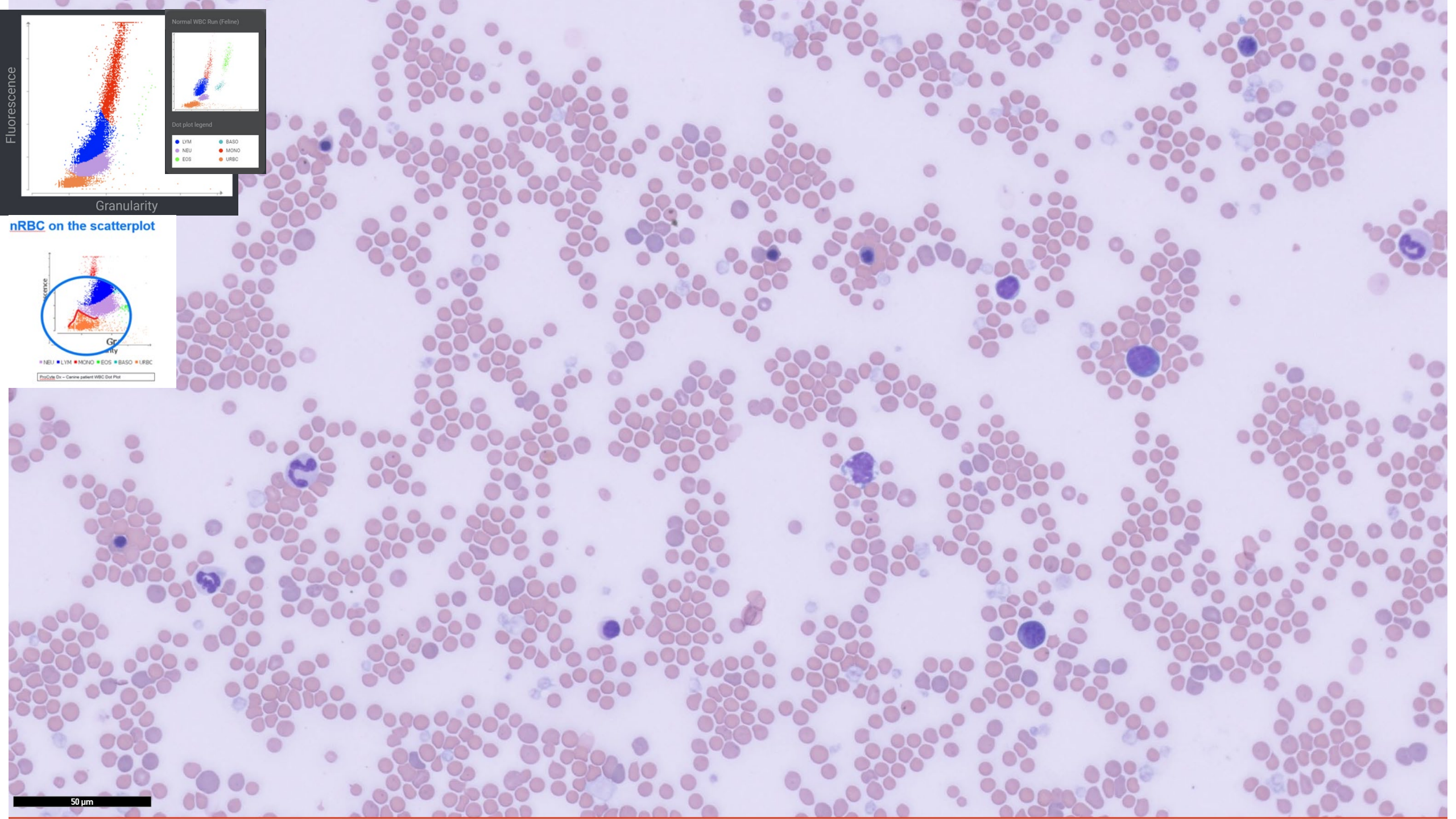
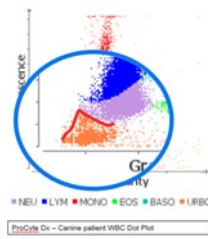




Fluorescence



nRBC on the scatterplot



50 μm

Charlie

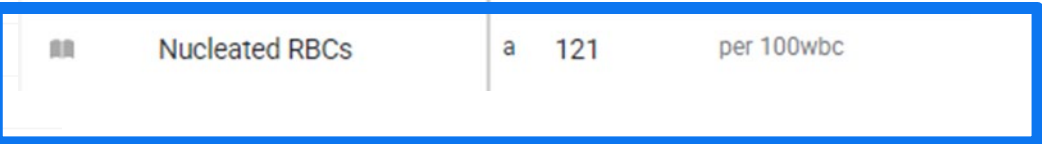
+ 8Y

+ FN

+ DSH

Haematology		13/05/2026	10:55
RBC	2.25	6.54 - 12.20 x10 ¹² /L	
Haematocrit	0.141	0.303 - 0.523 L/L	
Haemoglobin	39	98 - 162 g/L	
MCV	62.7	35.9 - 53.1 fL	
MCH	17.3	11.8 - 17.3 pg	
MCHC	277	281 - 358 g/L	
RDW	27.8	15.0 - 27.0 %	
% Reticulocytes	6.0	%	
Reticulocytes	134.8	3.0 - 50.0 K/ μ L	
Reticulocyte Haemoglobin	20.5	13.2 - 20.8 pg	
WBC	24.91	2.87 - 17.02 x10 ⁹ /L	
% Neutrophils	*47	%	
% Lymphocytes	*39.5	%	
% Monocytes	*12.7	%	
% Eosinophils	0.1	%	
% Basophils	0.0	%	
Neutrophils	*11.88	2.30 - 10.29 x10 ⁹ /L	
Bands	*Suspected		
Lymphocytes	*9.83	0.92 - 6.88 x10 ⁹ /L	
Monocytes	*3.17	0.05 - 0.67 x10 ⁹ /L	
Eosinophils	0.02	0.17 - 1.57 x10 ⁹ /L	
Basophils	0.01	0.01 - 0.26 x10 ⁹ /L	
Platelets	142	151 - 600 x10 ⁹ /L	
MPV	18.6	11.4 - 21.6 fL	
Plateletcrit	0.26	0.17 - 0.86 %	

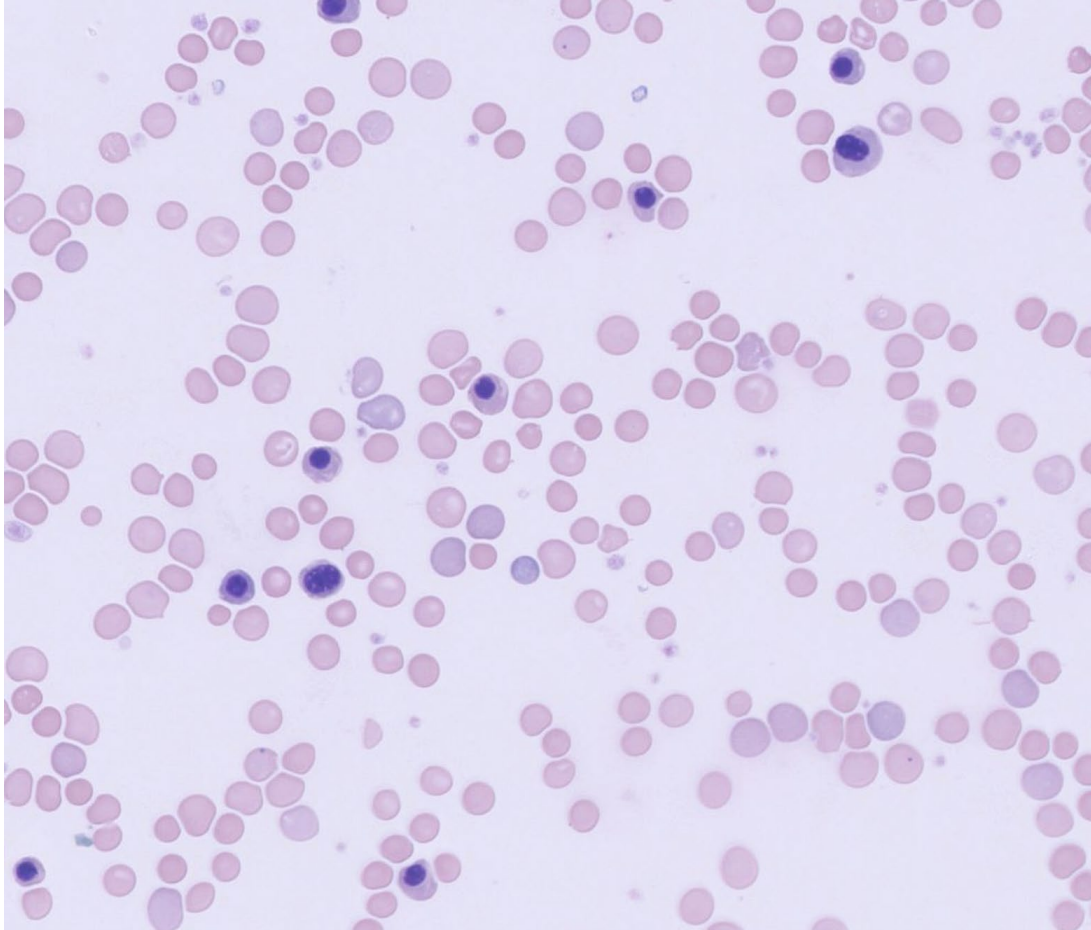
Haematology		14/05/2026	03:41
% Neutrophils	56.0	%	
% Lymphocytes	27.0	%	
% Monocytes	17.0	%	
% Eosinophils	0.0	%	
% Basophils	0.0	%	
Nucleated RBCs	a 121	per 100wbc	



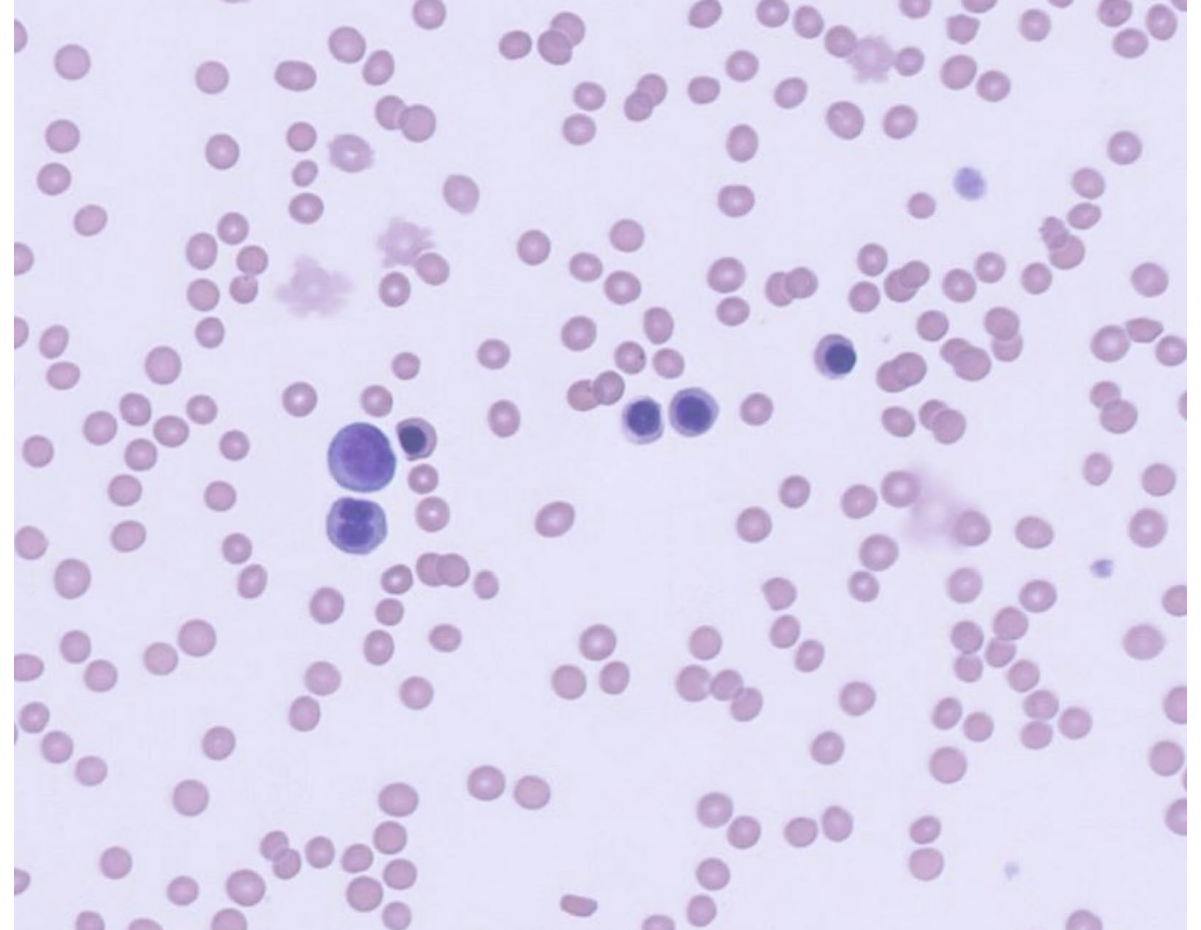
Immunology		13/05/2026	23:43
Coombs' (37° C)	Positive result in Neutral Gel control		

Nucleated RBCs

As part of regeneration



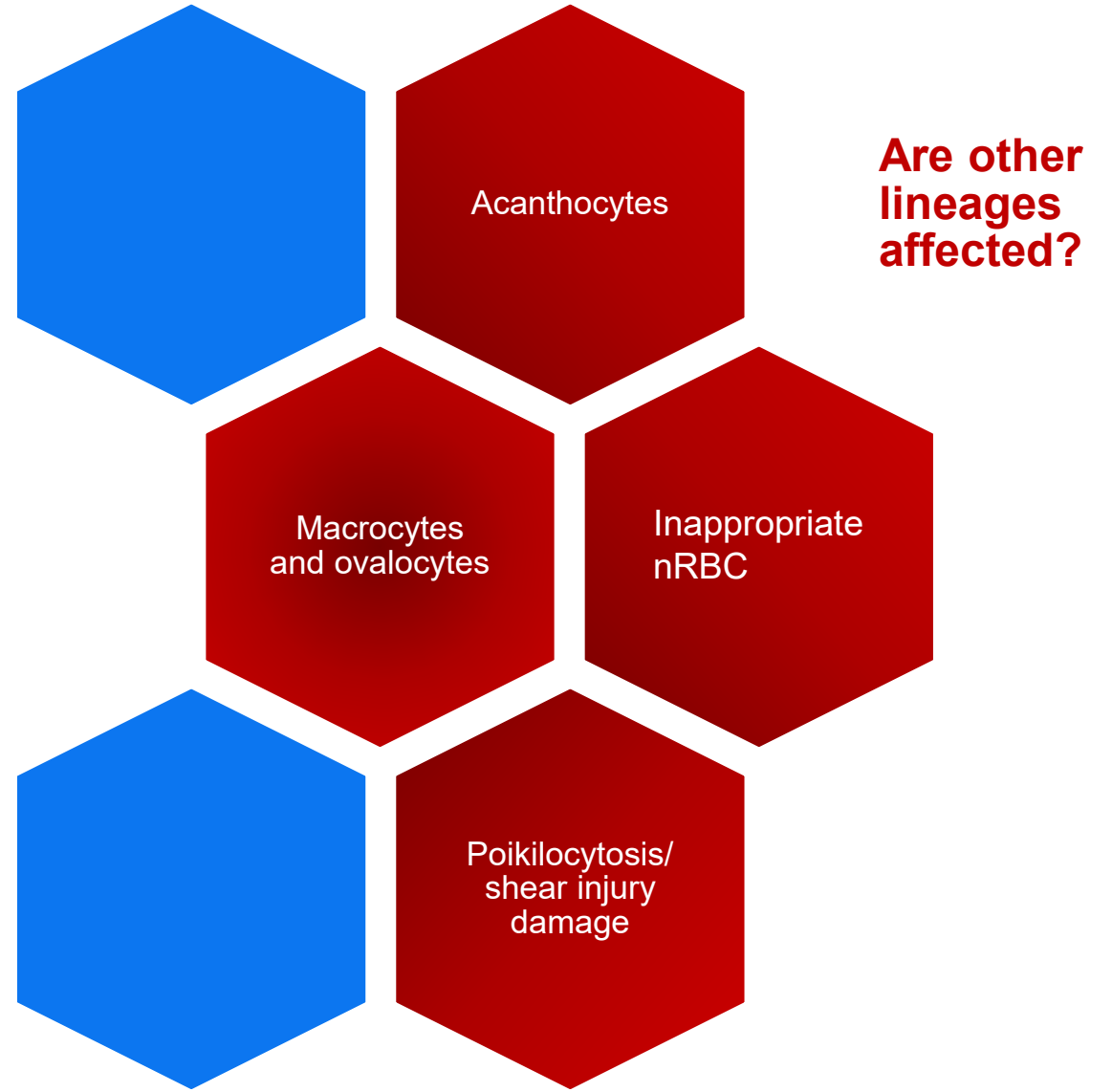
Inappropriate rubricytosis



Anaemia

Non-regenerative

Chronic Disease
Bone Marrow Disease
Renal Disease
Per-acute blood loss
Vector borne disease/retroviruses



Brian

+ 9 Y

+ MN

+ Maine Coon

+ Initial presentation

+ Respiratory signs

+ Responded to symptomatic treatment

+ Repeat assessment in Jan



Haematology	02/01/2026				17/11/2025	
	17:29	17:26	17:23	17:13	10:38	10:23
RBC	9.10	9.50	9.71	9.71	7.58	9.35
Haematocrit	0.068	0.071	0.07	0.071	0.064	0.078
Haemoglobin	54	57	56	56	48	54
MCV	7.5	7.5	7.2	7.3	8.4	8.3
MCH	5.9	6.0	5.8	5.8	6.3	5.8
MCHC	794	803	800	789	750	692
Reticulocytes	8.2	7.6	4.9	2.9	14.4	73.9

Manual PCV run inhouse 02.01.26
20%

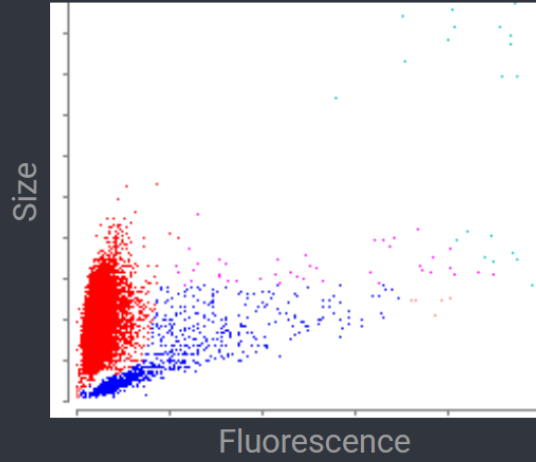


Manual PCV 10/01 referral lab

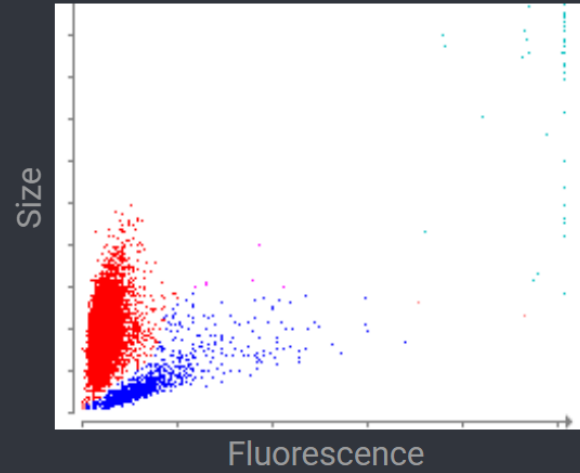
Haematology	10/01/2026 07:59	09/01/2026 15:01	02/01/2026 17:29	02/01/2026 17:26	02/01/2026 17:23	02/01/2026 17:13	17/11/2025 10:38	17/11/2025 10:23
RBC	9.57	10.94	9.10	9.50	9.71	9.71	7.58	9.35
Haematocrit	a 0.220	0.074	0.068	0.071	0.07	0.071	0.064	0.078
Haemoglobin	59	61	54	57	56	56	48	54
MCV	23.0	6.8	7.5	7.5	7.2	7.3	8.4	8.3
MCH	6.2	5.6	5.9	6.0	5.8	5.8	6.3	5.8
MCHC	268	824	794	803	800	789	750	692
Reticulocytes	b 8.6	1.1	8.2	7.6	4.9	2.9	14.4	73.9

Manual PCV run inhouse 02.01.26
20%

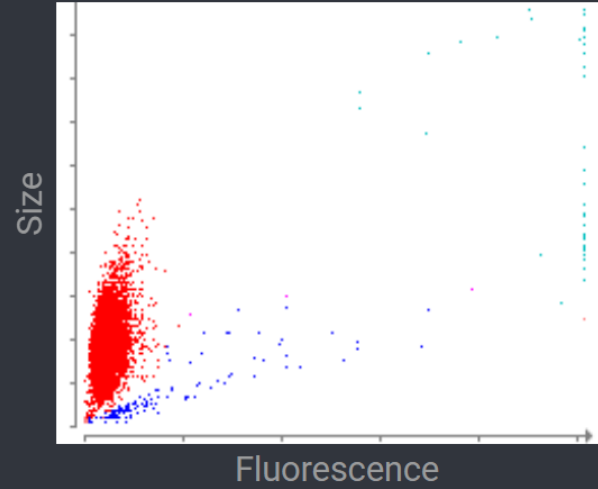
17 Nov 2025
1 of 1



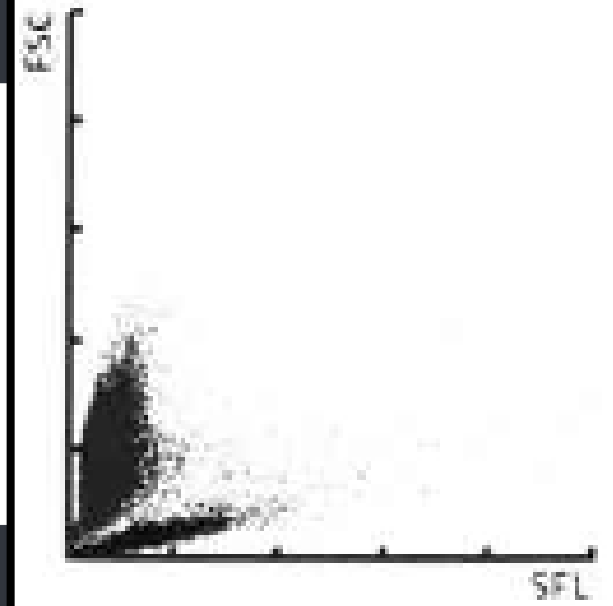
2 Jan 2026
1 of 1



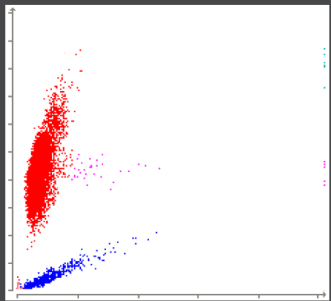
9 Jan 2026
1 of 1



KEI - EXI SSC



Normal RBC Run (Feline)



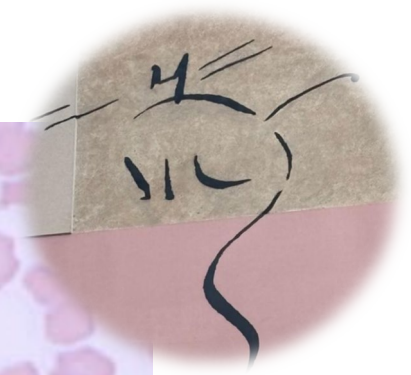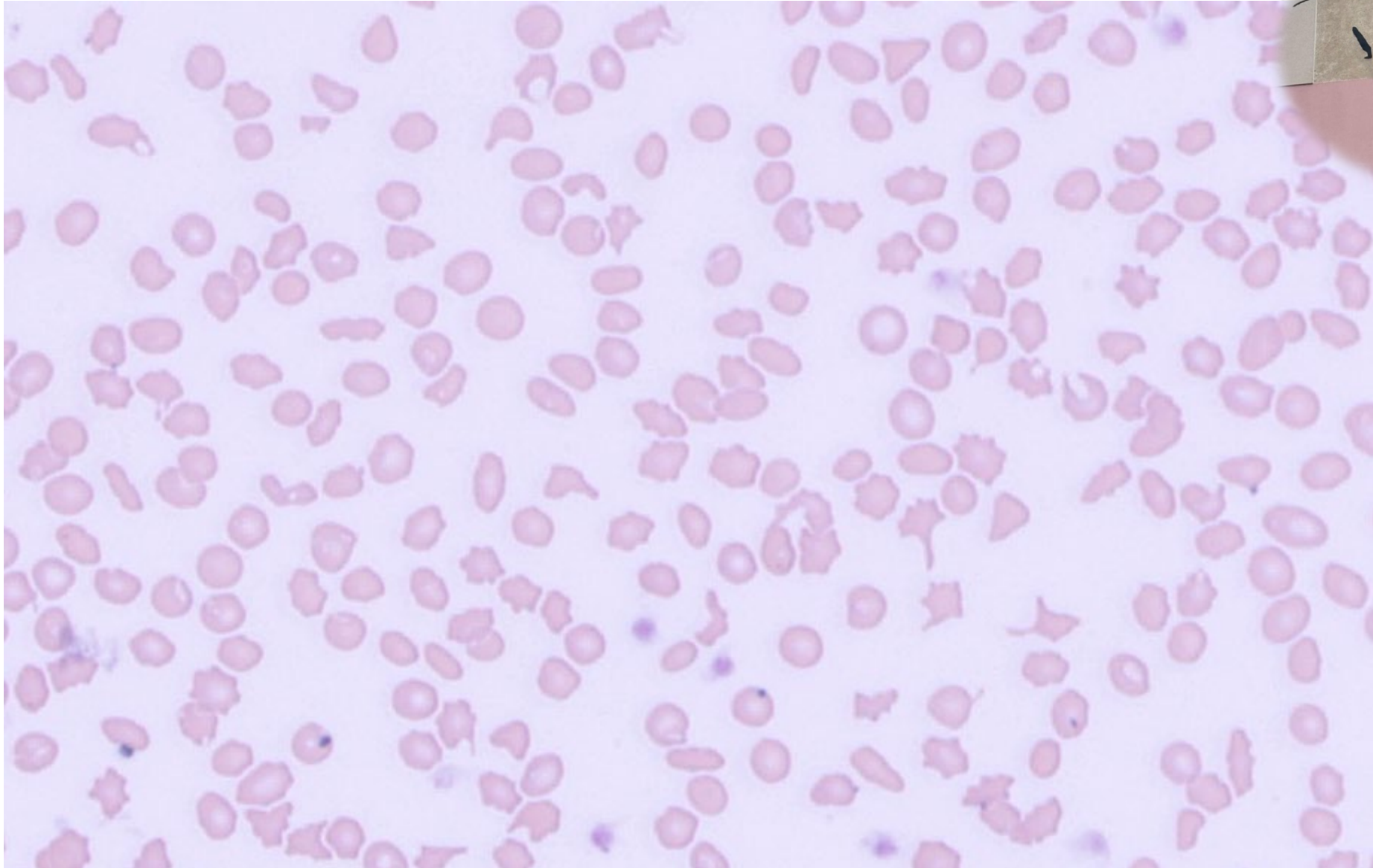
Dot plot legend



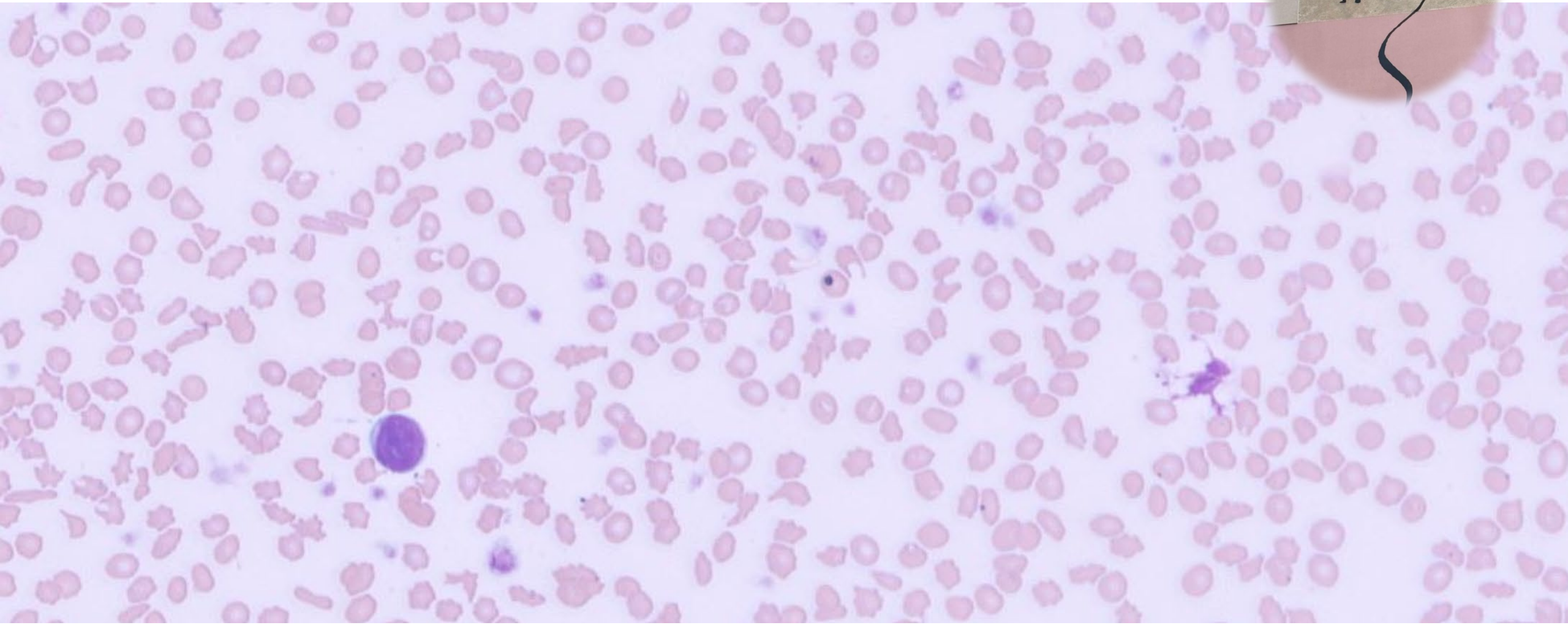


Haematology

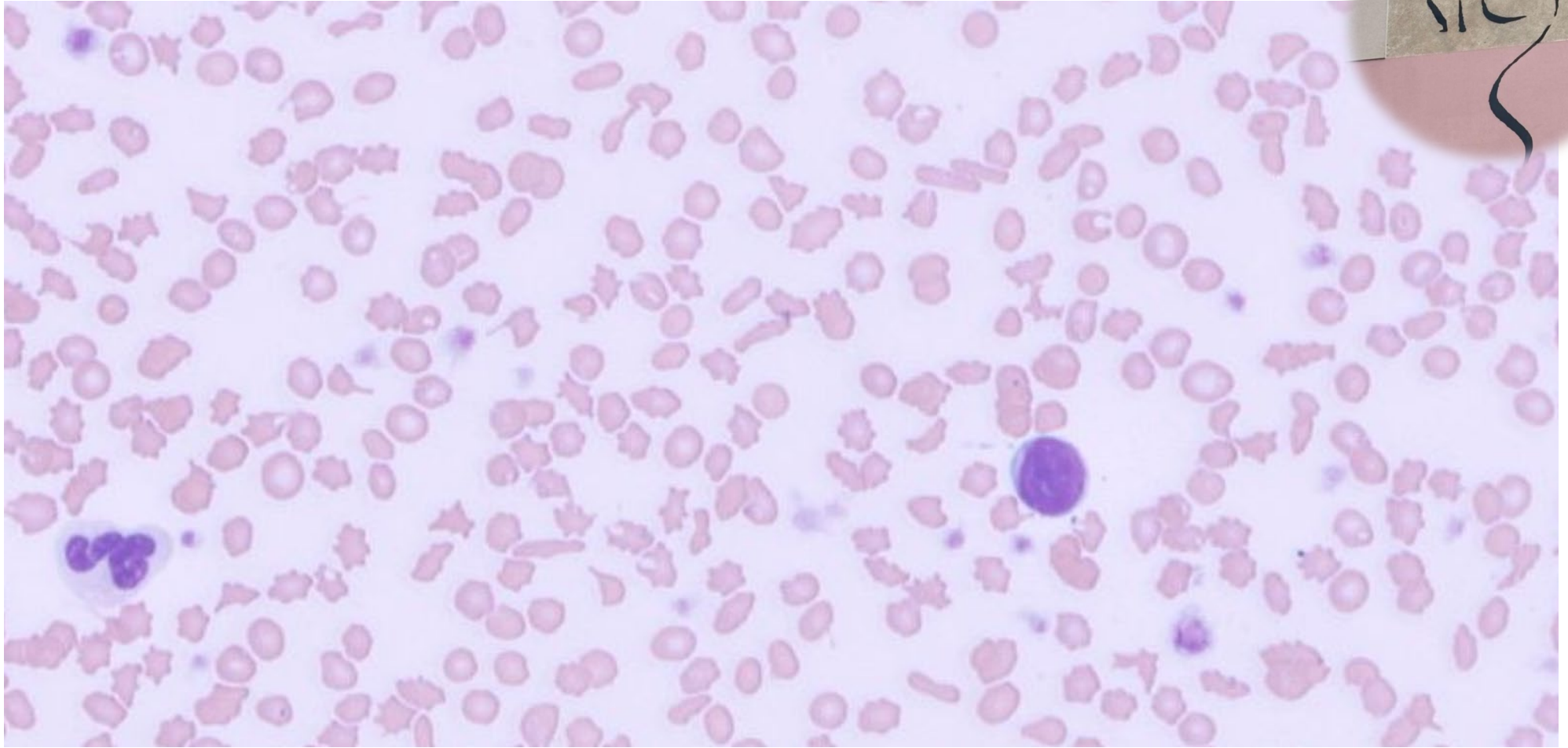
	10/01/2026 07:59	09/01/2026 15:01	02/01/2026 17:29	02/01/2026 17:26	02/01/2026 17:23	02/01/2026 17:13	17/11/2025 10:38	17/11/2025 10:23
RBC	9.57	10.94	9.10	9.50	9.71	9.71	7.58	9.35
Haematocrit	a 0.220	0.074	0.068	0.071	0.07	0.071	0.064	0.078
Haemoglobin	59	61	54	57	56	56	48	54
MCV	23.0	6.8	7.5	7.5	7.2	7.3	8.4	8.3
MCH	6.2	5.6	5.9	6.0	5.8	5.8	6.3	5.8
MCHC	268	824	794	803	800	789	750	692
Reticulocytes	b 8.6	1.1	8.2	7.6	4.9	2.9	14.4	73.9



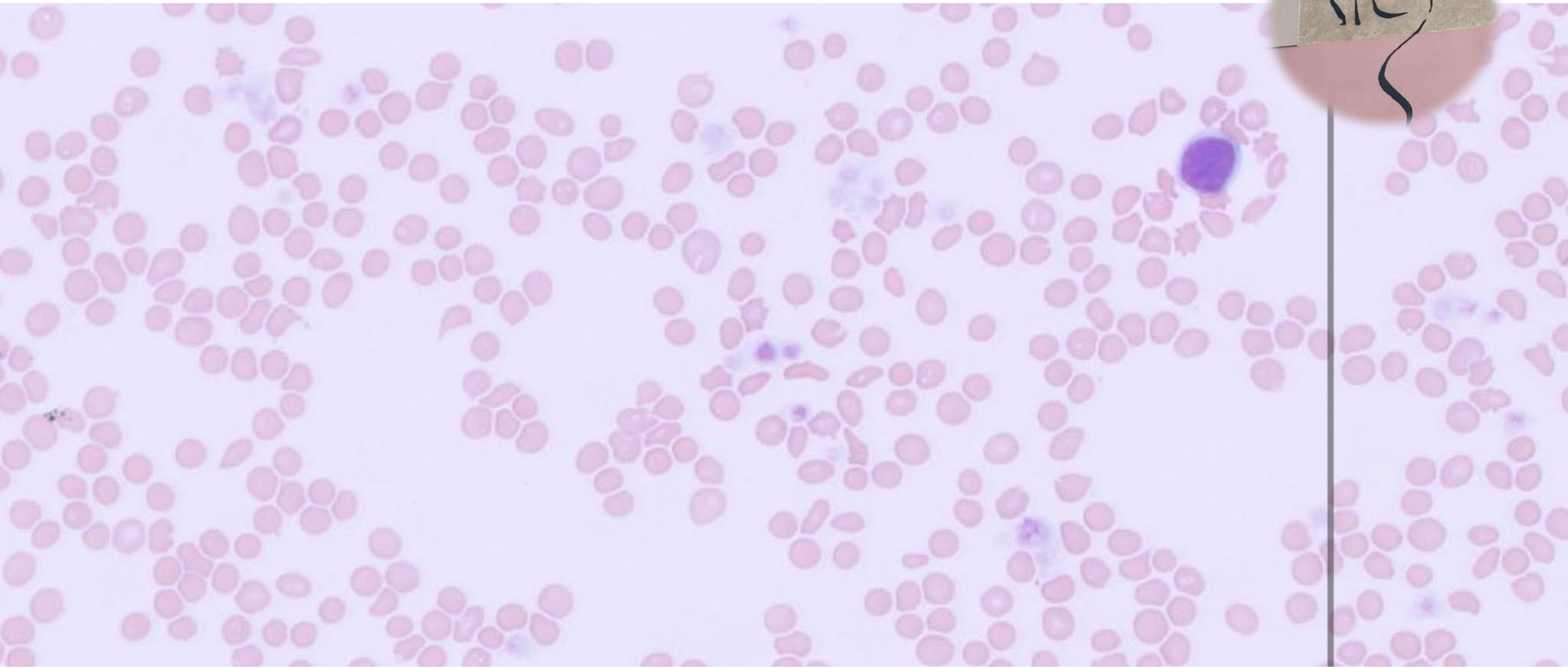
Slide courtesy of Dr Deirdre Coleman



Slide courtesy of Dr Deirdre Coleman



Slide courtesy of Dr Deirdre Coleman



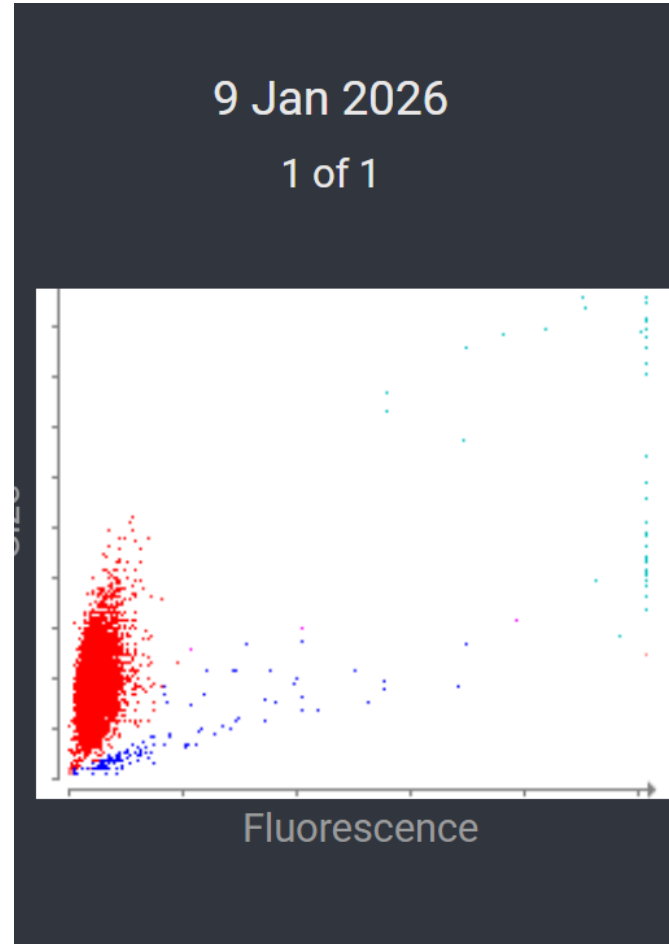
Brian – Marked poikilocytosis affecting results

Tier 1

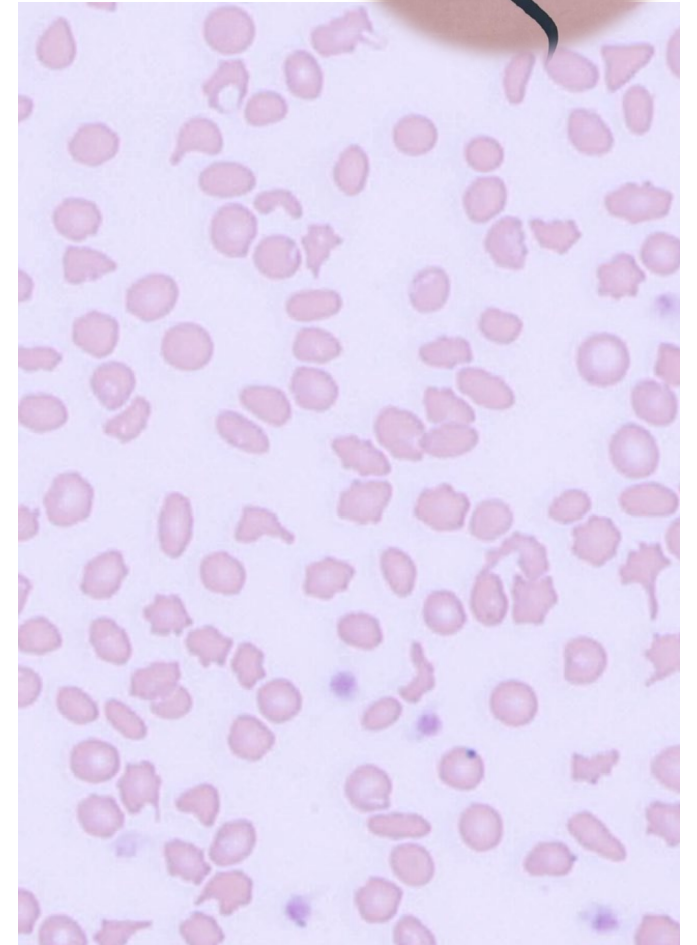
Haematology		09/01/2026 10:01
RBC	10.94	6.54 - 12.20 x10 ¹² /L
Haematocrit	0.074	0.303 - 0.523 L/L
Haemoglobin	61	98 - 162 g/L
MCV	6.8	35.9 - 53.1 fL
MCH	5.6	11.8 - 17.3 pg
MCHC	824	281 - 358 g/L
RDW	*48.7	15.0 - 27.0 %
% Reticulocytes	0.0	%
Reticulocytes	1.1	3.0 - 50.0 K/ μ L
Reticulocyte Haemoglobin	11.5	13.2 - 20.8 pg

Manual PCV ~20%

Tier 2



Tier 3



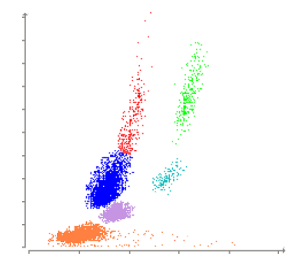
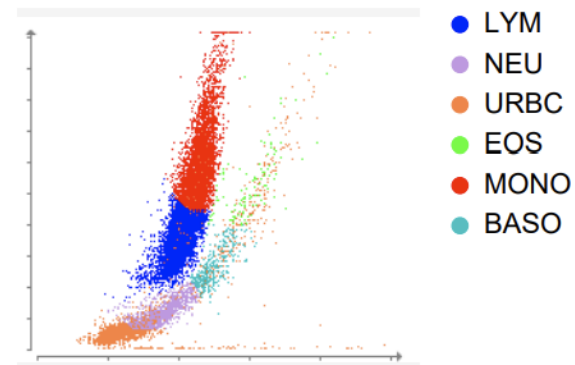
If there is HTC/HGB mismatch – do a Manual PCV and Check the smear!

Nefeli



- 6Y FN
- Urgent weekend case
- History of lethargy, anorexia, ascites, jaundice/48 hours.
- Abdominal ultrasound - moderate amount of free fluid (chylous?), large mass in mid/caudal abdomen consistent with mesenteric lymph nodes, liver diffusely enlarged and hyperechoic.

■	WBC	*17.78	2.87 - 17.02 x10 ⁹ /L	
■	% Neutrophils	*8.3	%	
■	% Lymphocytes	*46.2	%	
■	% Monocytes	*42.7	%	
■	% Eosinophils	*0.7	%	
■	% Basophils	-	---	%
■	Neutrophils	*1.47	2.30 - 10.29 x10 ⁹ /L	
■	Bands	*Suspected		
■	Lymphocytes	*8.21	0.92 - 6.88 x10 ⁹ /L	
■	Monocytes	*7.60	0.05 - 0.67 x10 ⁹ /L	
■	Eosinophils	*0.12	0.17 - 1.57 x10 ⁹ /L	
■	Basophils	-	---	0.01 - 0.26 x10 ⁹ /L

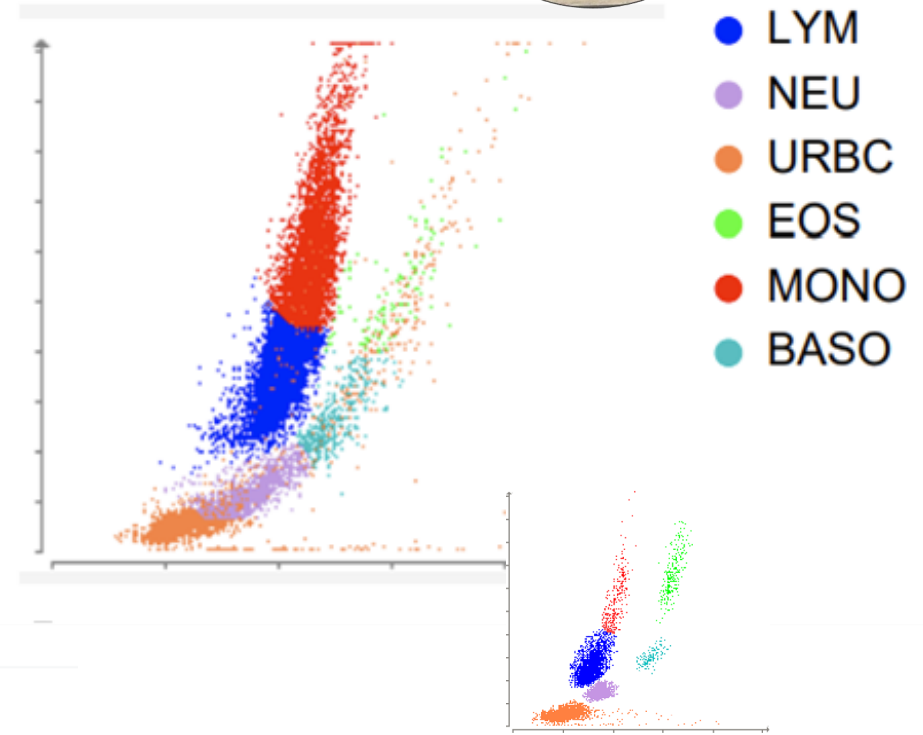


ProCyte Dx™ – Feline Normal WBC Dot Plot

Nefeli



☰	WBC	*17.78	2.87 - 17.02 x10 ⁹ /L	<input type="text" value=""/>
☰	% Neutrophils	*8.3	%	
☰	% Lymphocytes	*46.2	%	
☰	% Monocytes	*42.7	%	
☰	% Eosinophils	*0.7	%	
☰	% Basophils	-	---	%
☰	Neutrophils	*1.47	2.30 - 10.29 x10 ⁹ /L	<input type="text" value=""/>
☰	Bands	*Suspected		
☰	Lymphocytes	*8.21	0.92 - 6.88 x10 ⁹ /L	<input type="text" value=""/>
☰	Monocytes	*7.60	0.05 - 0.67 x10 ⁹ /L	<input type="text" value=""/>
☰	Eosinophils	*0.12	0.17 - 1.57 x10 ⁹ /L	<input type="text" value=""/>
☰	Basophils	-	---	0.01 - 0.26 x10 ⁹ /L



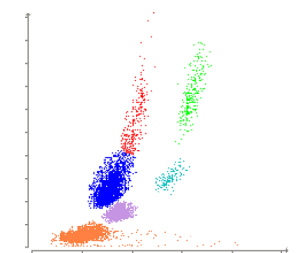
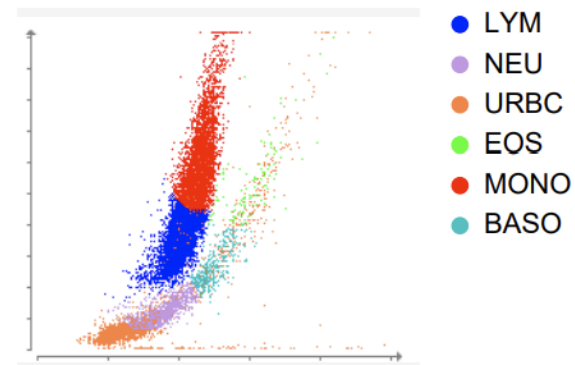
ProCyte Dx™ – Feline Normal WBC Dot Plot

Nefeli

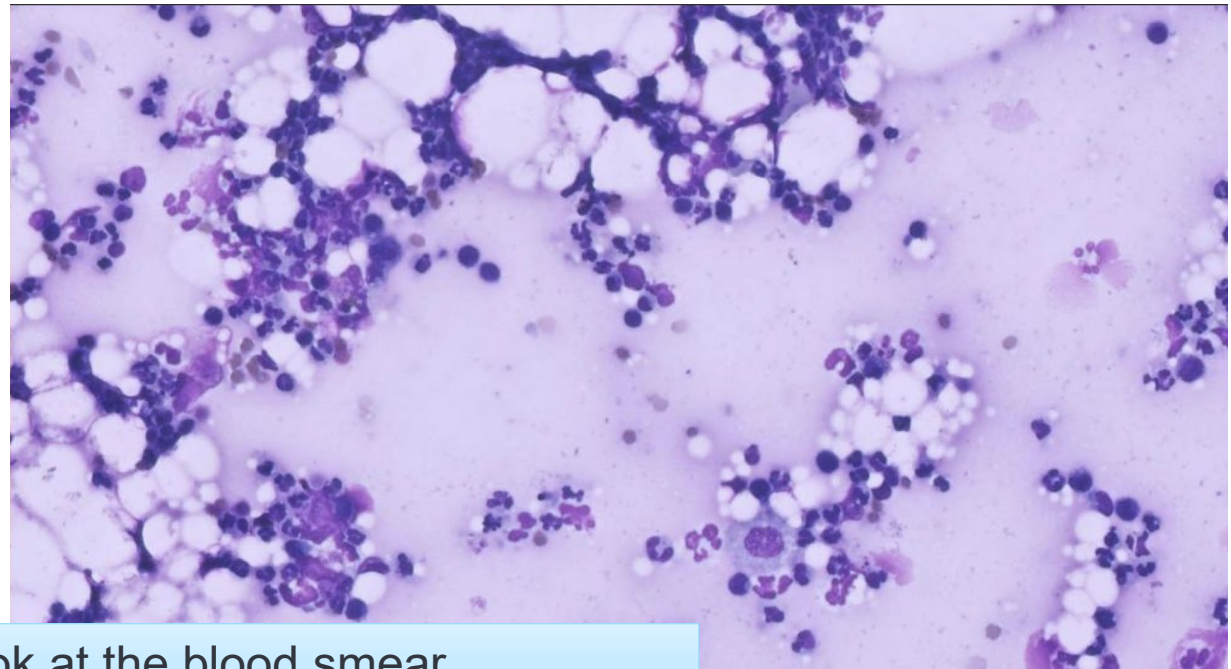
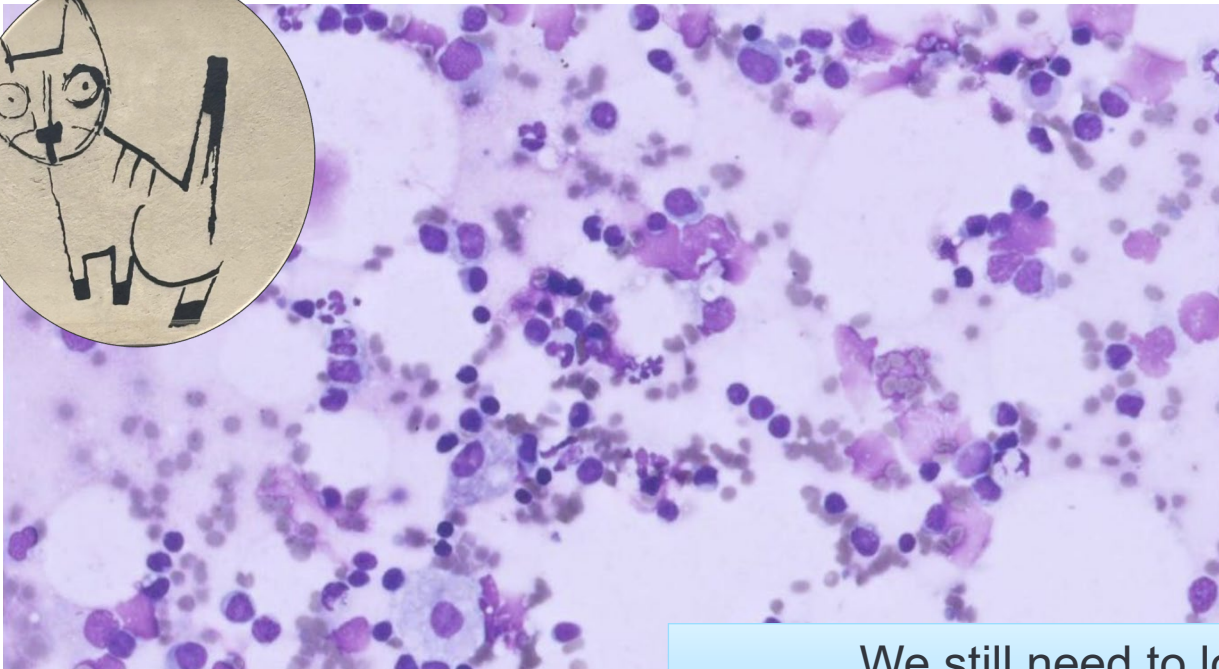
- 6Y FN
- History of lethargy, anorexia, ascites, jaundice/48 hours.
- Abdominal ultrasound - moderate amount of free fluid (chylous?), large mass in mid/caudal abdomen consistent with mesenteric lymph nodes, liver diffusely enlarged and hyperechoic.
- Ascitic fluid submitted for analysis.
- 1st site - liver, 2nd site - abdominal mass (lymph node)



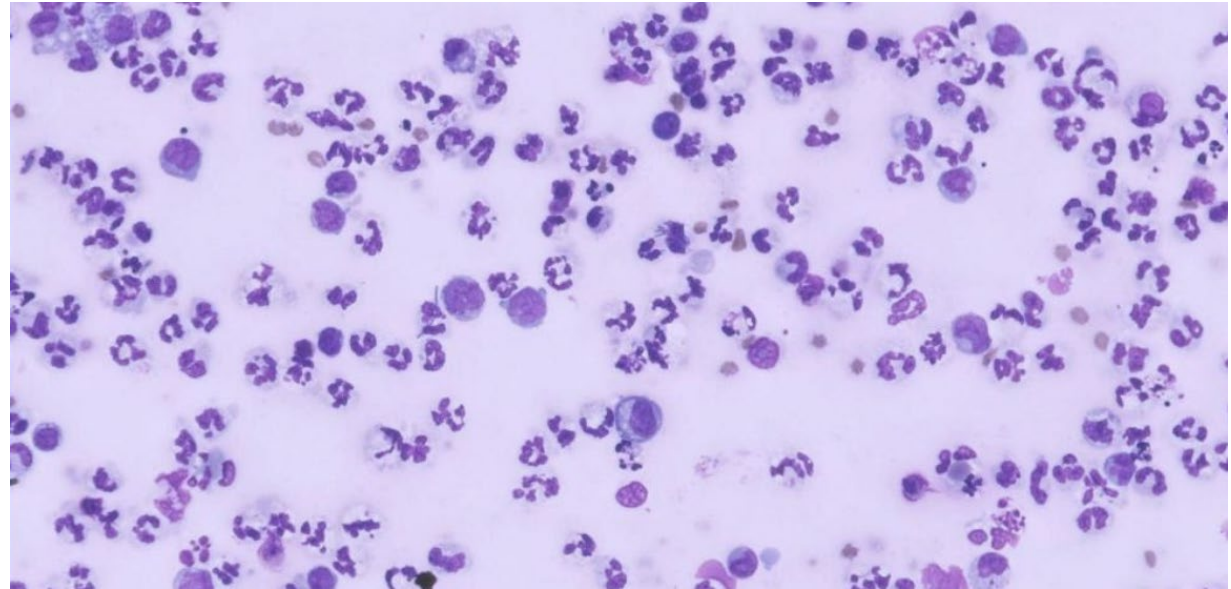
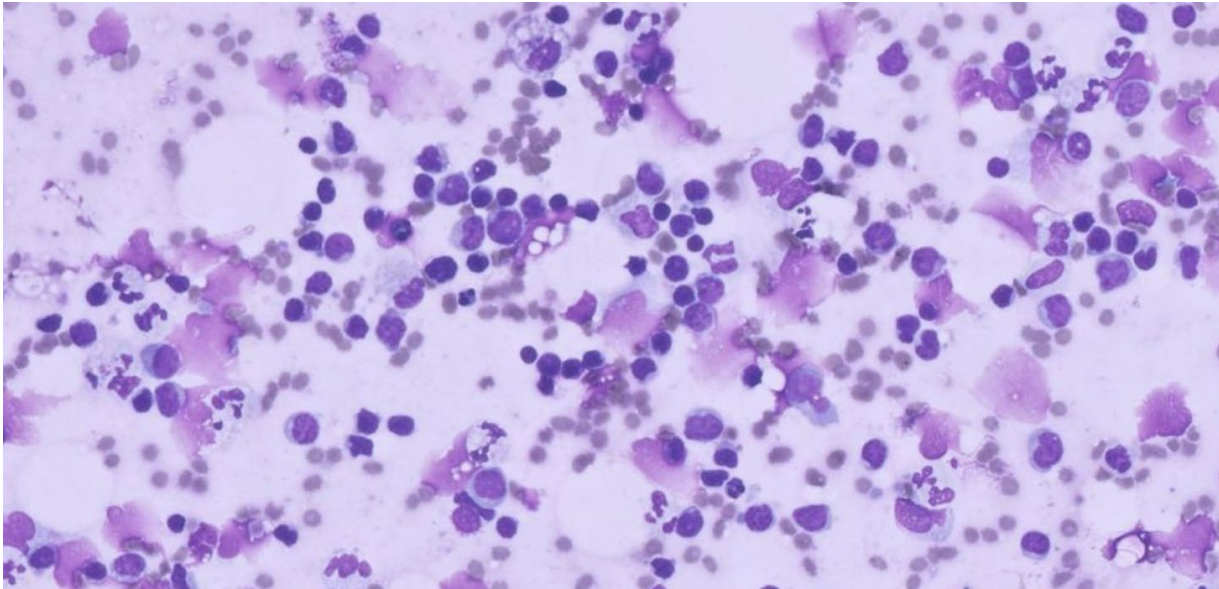
■	WBC	*17.78	2.87 - 17.02 x10 ⁹ /L	
■	% Neutrophils	*8.3	%	
■	% Lymphocytes	*46.2	%	
■	% Monocytes	*42.7	%	
■	% Eosinophils	*0.7	%	
■	% Basophils	-	---	%
■	Neutrophils	*1.47	2.30 - 10.29 x10 ⁹ /L	
■	Bands	*Suspected		
■	Lymphocytes	*8.21	0.92 - 6.88 x10 ⁹ /L	
■	Monocytes	*7.60	0.05 - 0.67 x10 ⁹ /L	
■	Eosinophils	*0.12	0.17 - 1.57 x10 ⁹ /L	
■	Basophils	-	---	0.01 - 0.26 x10 ⁹ /L



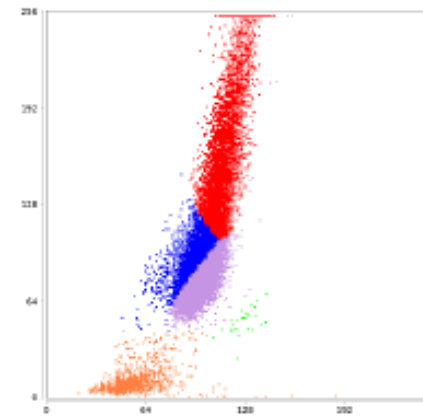
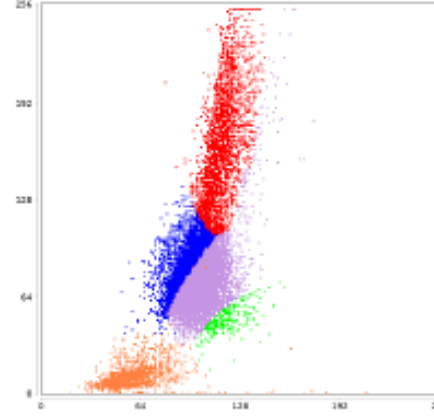
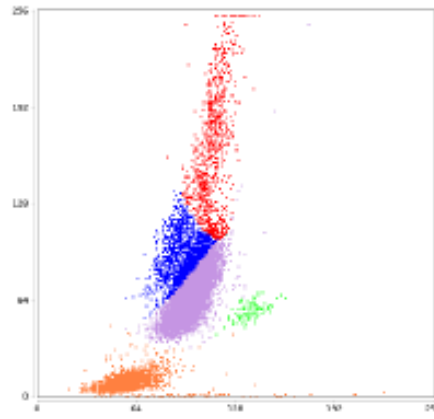
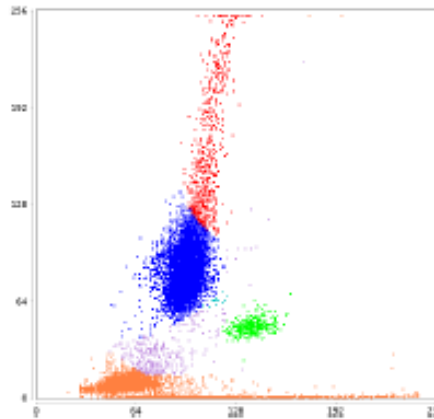
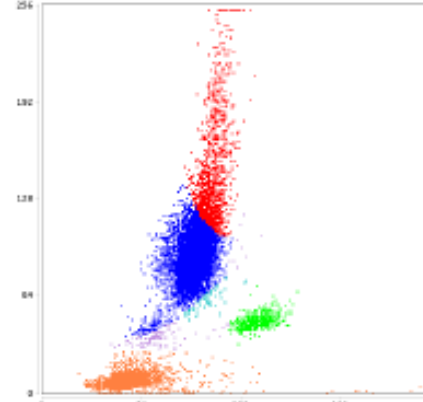
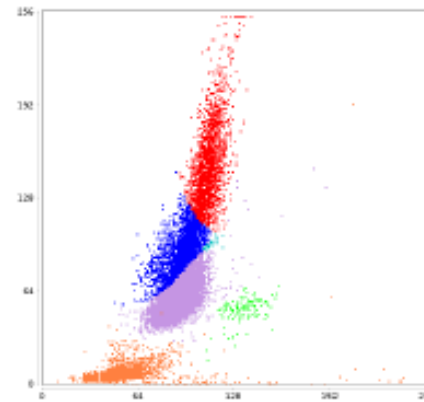
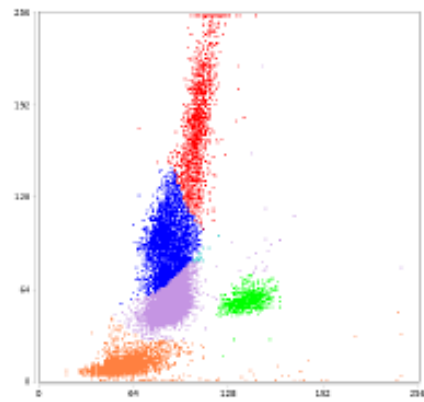
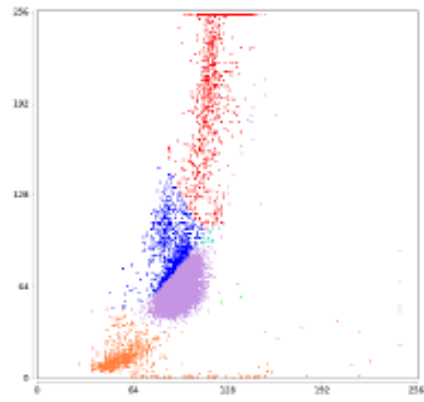
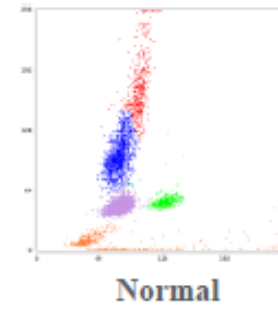
ProCyte Dx™ – Feline Normal WBC Dot Plot



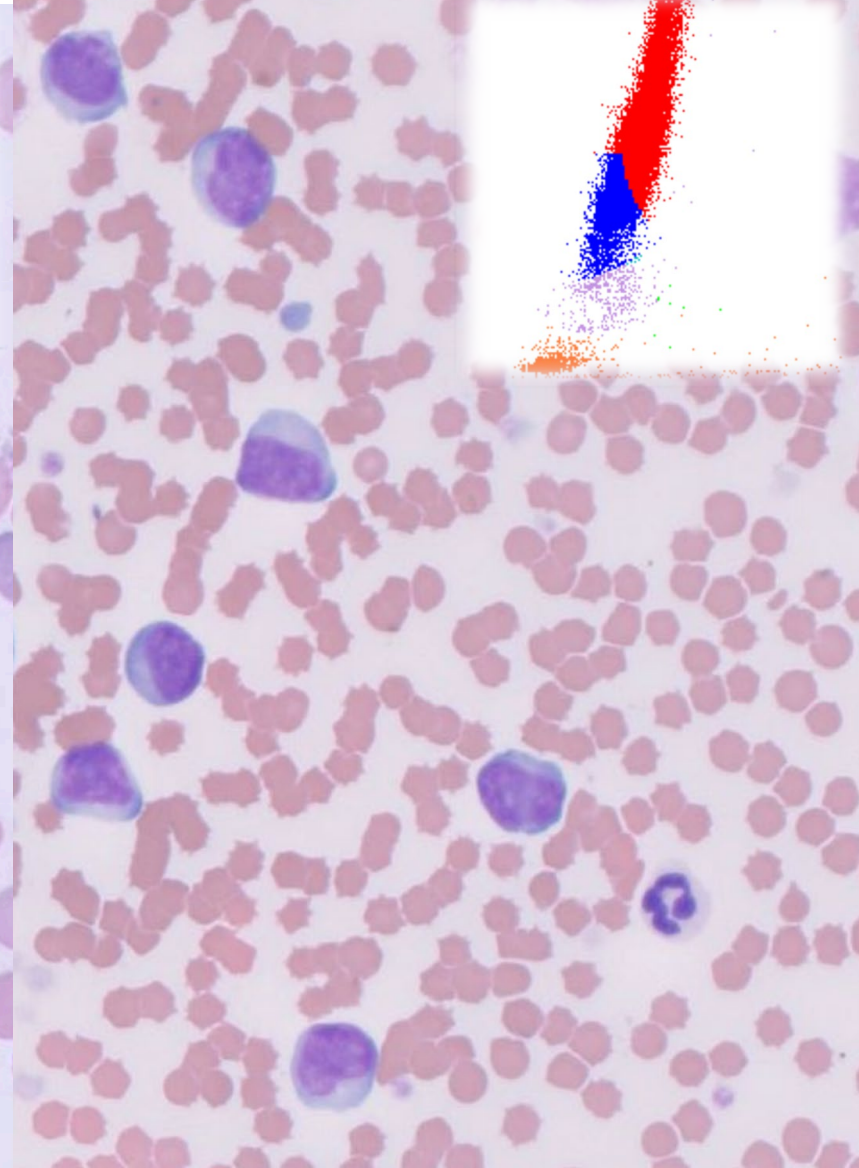
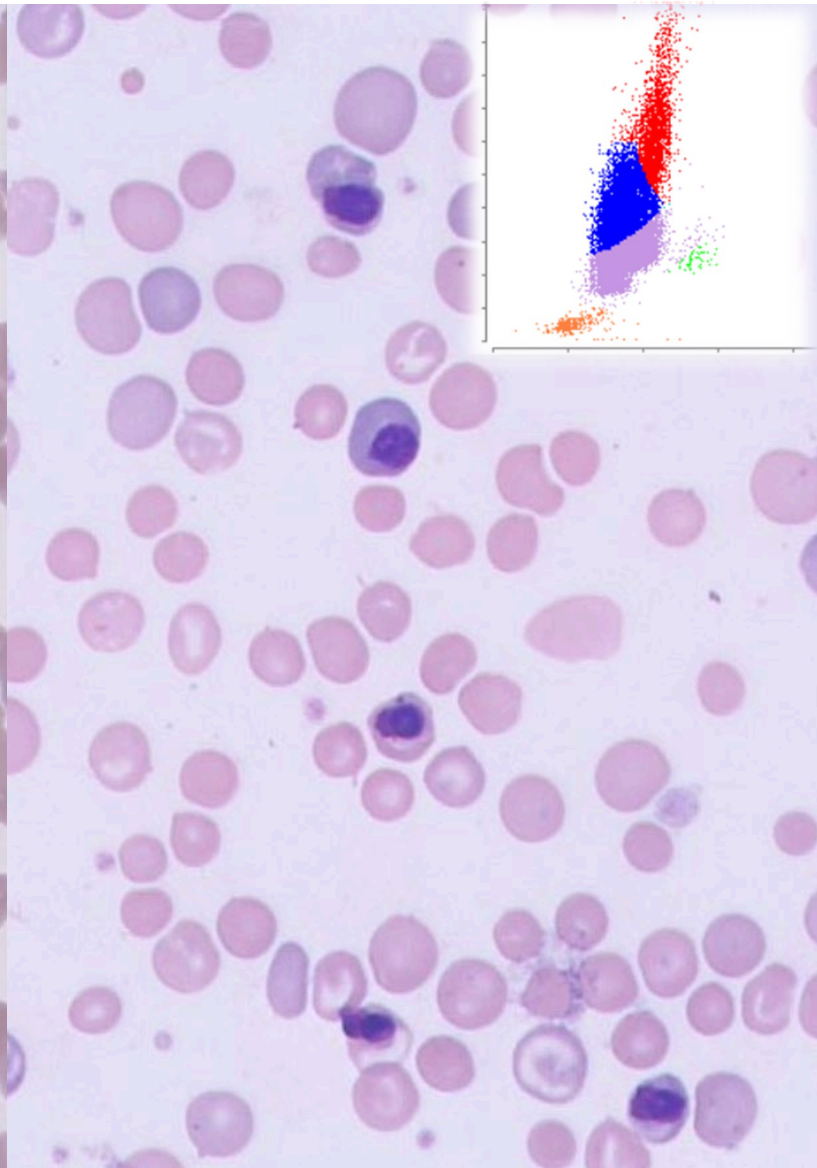
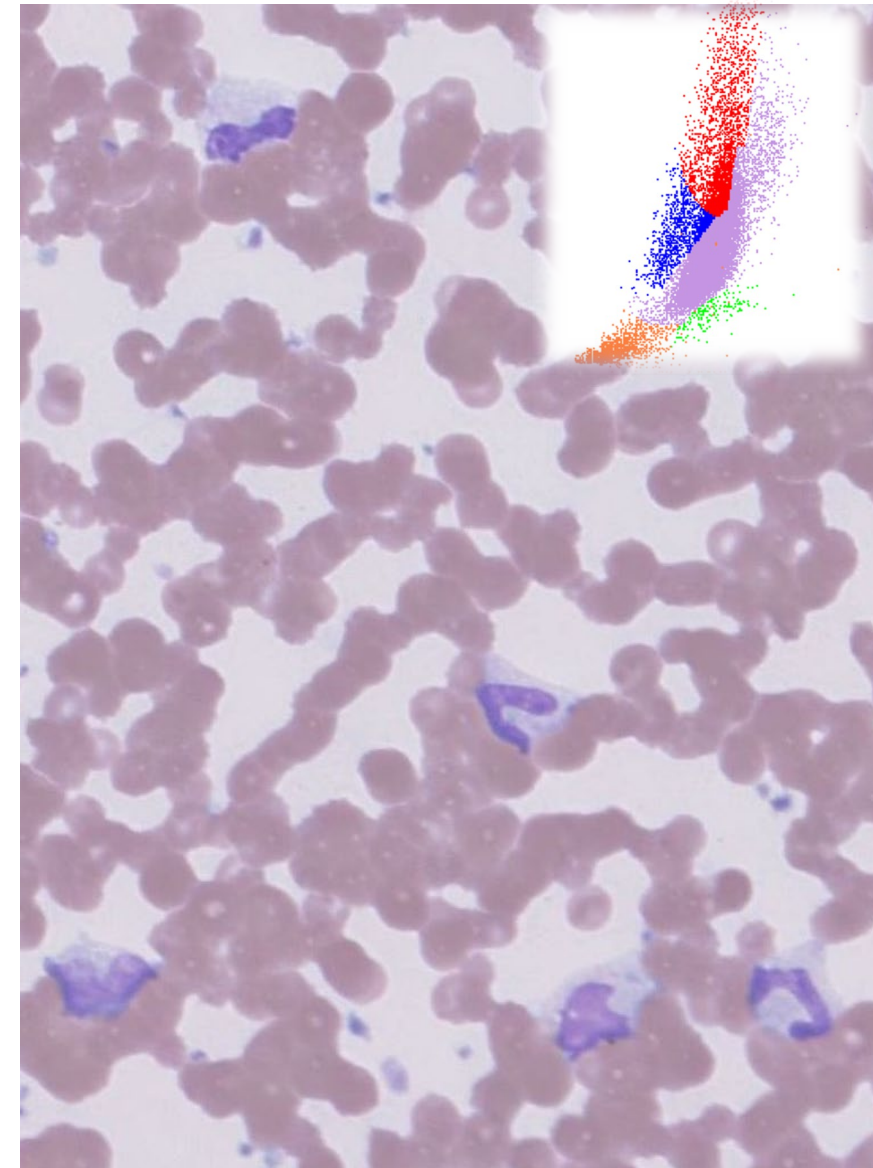
We still need to look at the blood smear....



ProCyte Dx™ – examples of left shift



White blood cell abnormalities... When the dot plots don't help

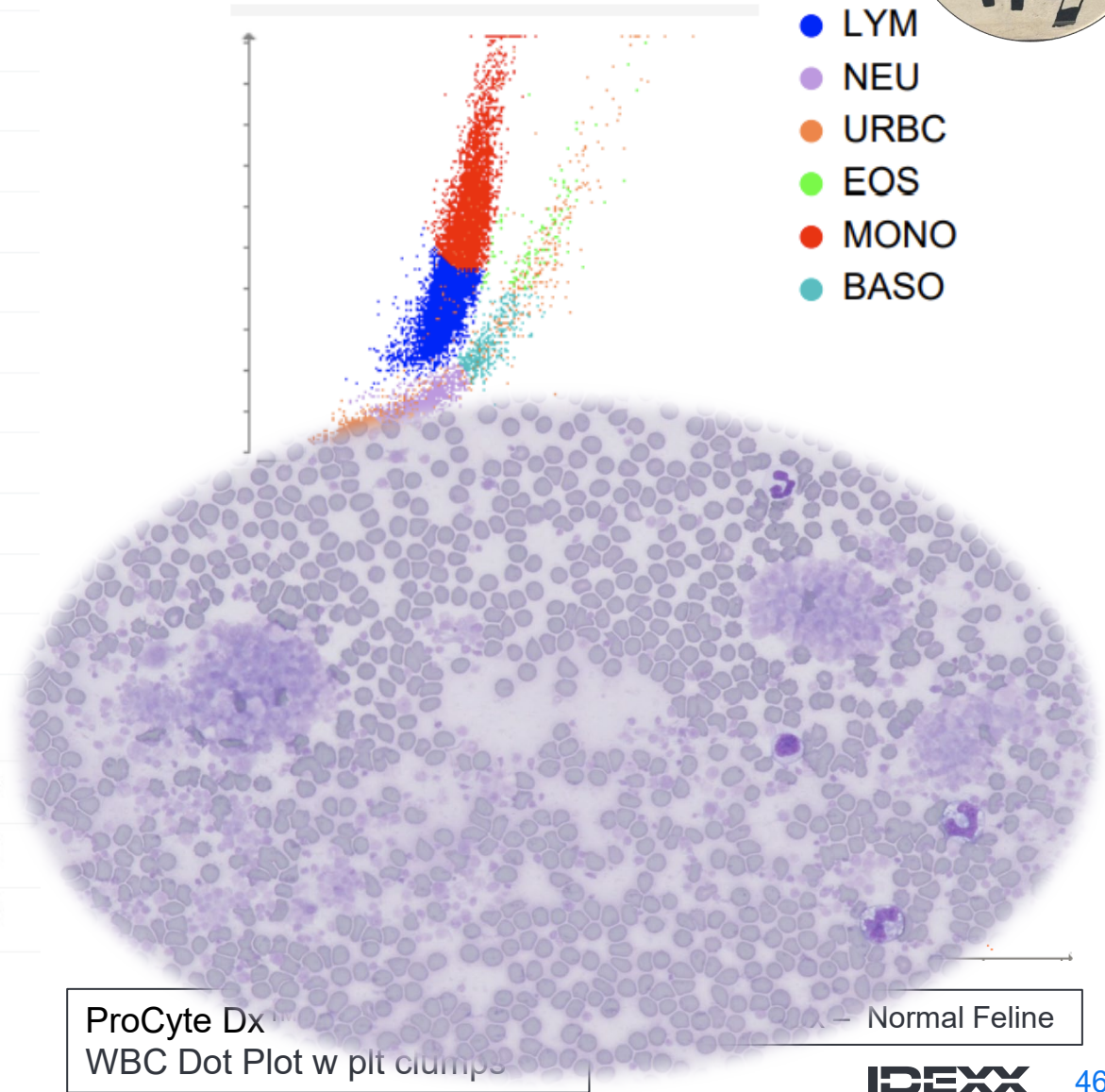


ProCyte Dx™ – Canine Patient WBC Dot Plots and respective blood smears

Nefeli – What else may be happening ...



WBC	*17.78	2.87 - 17.02 x10 ⁹ /L	
% Neutrophils	*8.3	%	
% Lymphocytes	*46.2	%	
% Monocytes	*42.7	%	
% Eosinophils	*0.7	%	
% Basophils	- ---	%	
Neutrophils	*1.47	2.30 - 10.29 x10 ⁹ /L	
Bands	*Suspected		
Lymphocytes	*8.21	0.92 - 6.88 x10 ⁹ /L	
Monocytes	*7.60	0.05 - 0.67 x10 ⁹ /L	
Eosinophils	*0.12	0.17 - 1.57 x10 ⁹ /L	
Basophils	- ---	0.01 - 0.26 x10 ⁹ /L	
Platelets	*74	151 - 600 x10 ⁹ /L	
MPV	*14.5	11.4 - 21.6 fL	
Plateletcrit	*0.11	0.17 - 0.86 %	



And then there are the unusual cases - Patch



- + 9 Y
- + MN
- + DSH

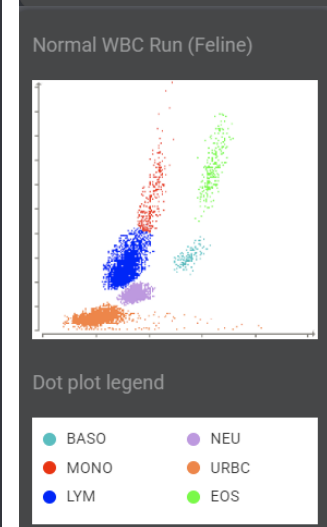
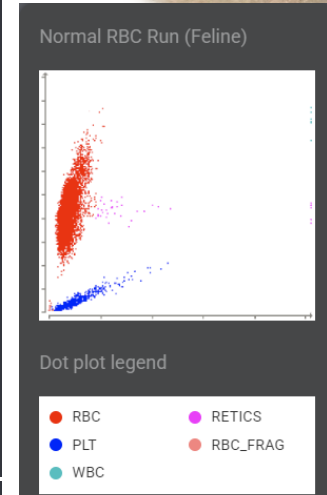
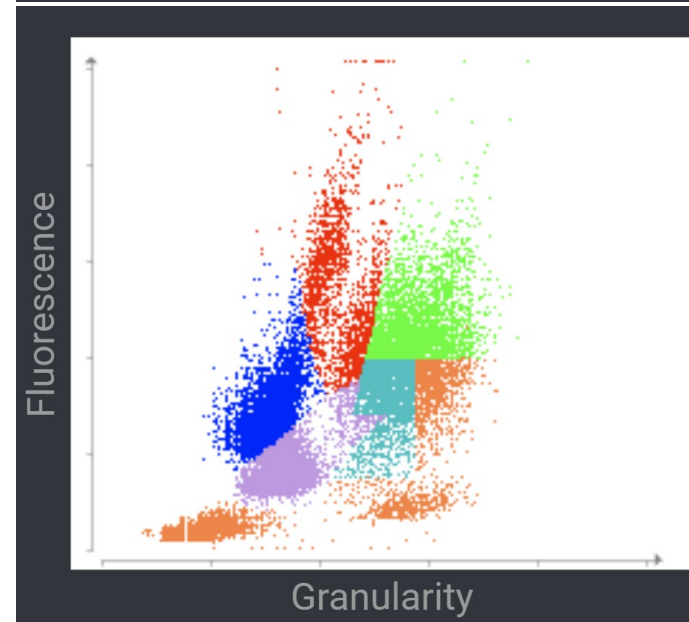
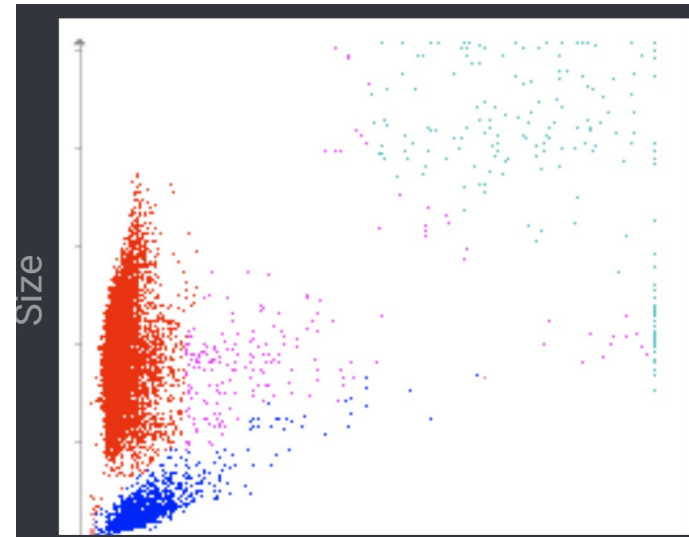
- + investigation of lethargy
- + Intermittent vomiting 4 mth
- + lost 500g in the last 4m (was 4.8- now 4.3kg)

Haematology		12/05/2026 14:42	
RBC	5.63	6.54 - 12.20 x10 ¹² /L	
Haematocrit	0.234	0.303 - 0.523 L/L	
Haemoglobin	76	98 - 162 g/L	
MCV	41.6	35.9 - 53.1 fL	
MCH	13.5	11.8 - 17.3 pg	
MCHC	325	281 - 358 g/L	
RDW	22.3	15.0 - 27.0 %	
% Reticulocytes	1.0	%	
Reticulocytes	53.5	3.0 - 50.0 K/ μ L	
Reticulocyte Haemoglobin	14.9	13.2 - 20.8 pg	
WBC	+36.40	2.87 - 17.02 x10 ⁹ /L	
% Neutrophils	+43.7	%	
% Lymphocytes	+21.2	%	
% Monocytes	+8.2	%	
% Eosinophils	+14.8	%	
% Basophils	+12.1	%	
Neutrophils	+15.91	2.30 - 10.29 x10 ⁹ /L	
Lymphocytes	+7.71	0.92 - 6.88 x10 ⁹ /L	
Monocytes	+3.00	0.05 - 0.67 x10 ⁹ /L	
Eosinophils	+5.38	0.17 - 1.57 x10 ⁹ /L	
Basophils	+4.40	0.01 - 0.26 x10 ⁹ /L	
Platelets	261	151 - 600 x10 ⁹ /L	
MPV	17.4	11.4 - 21.6 fL	
Plateletcrit	0.45	0.17 - 0.86 %	

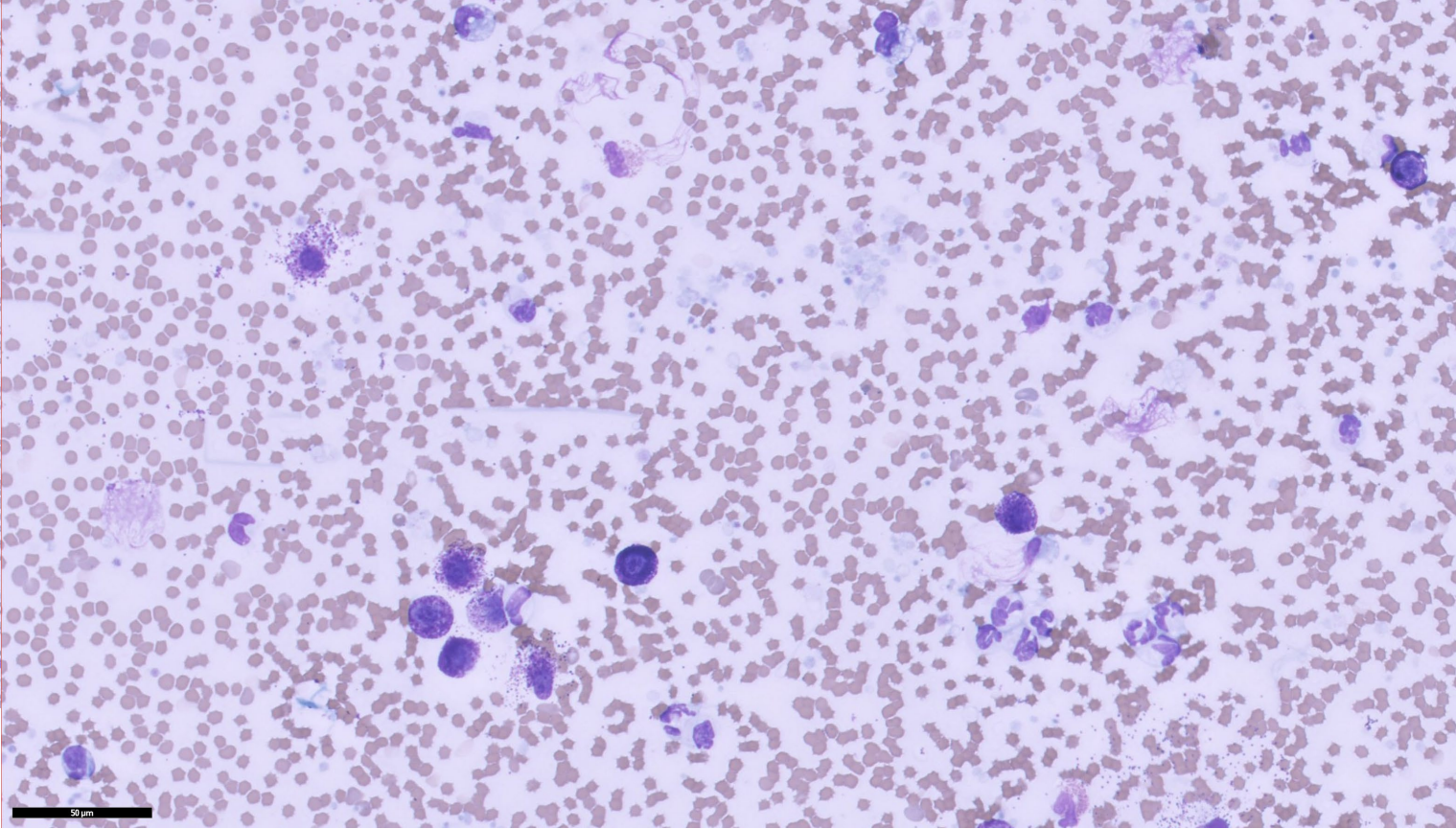
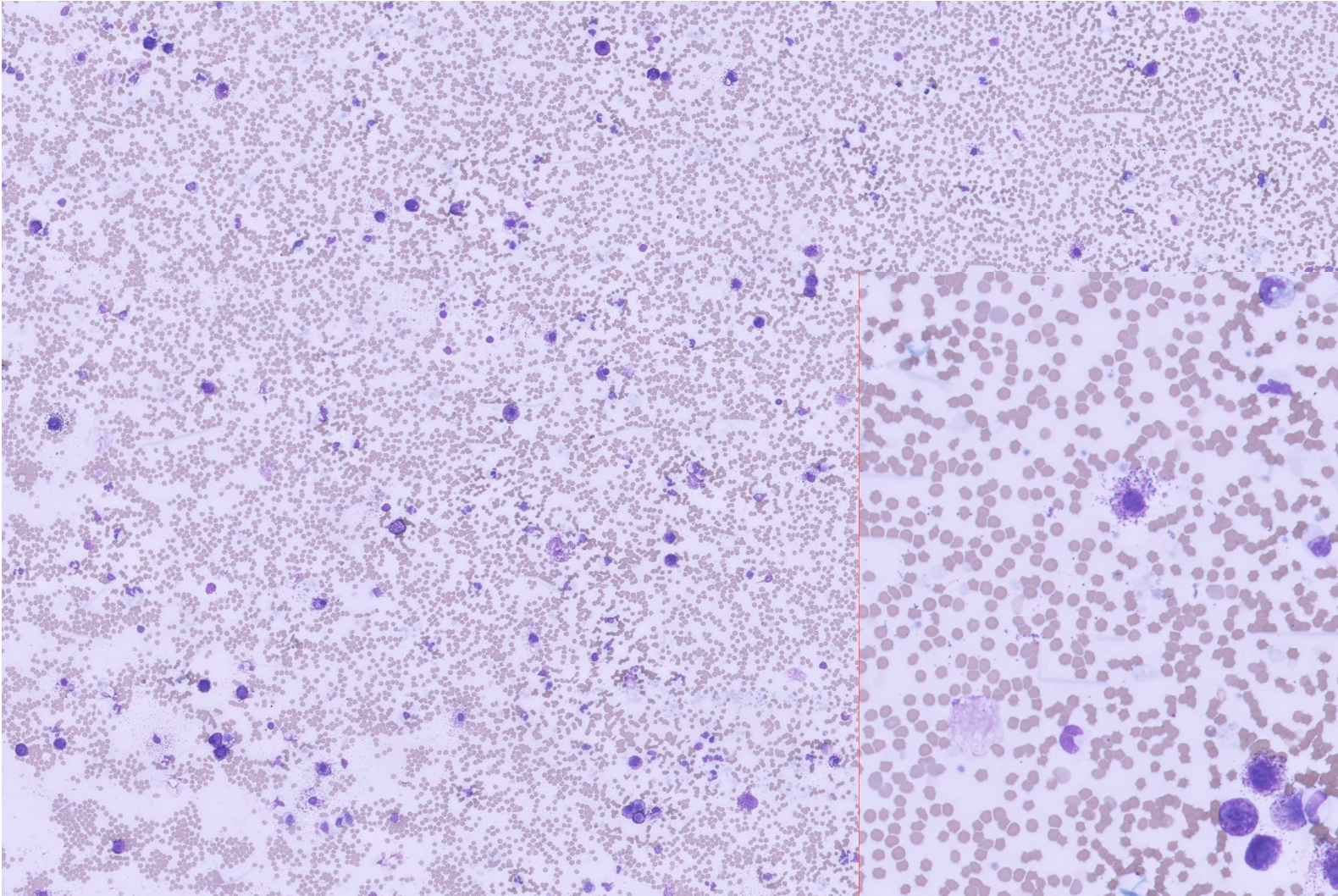
And then there are the unusual cases - Patch



Haematology		12/05/2026 14:42
RBC	5.63	6.54 - 12.20 x10 ¹² /L
Haematocrit	0.234	0.303 - 0.523 L/L
Haemoglobin	76	98 - 162 g/L
MCV	41.6	35.9 - 53.1 fL
MCH	13.5	11.8 - 17.3 pg
MCHC	325	281 - 358 g/L
RDW	22.3	15.0 - 27.0 %
% Reticulocytes	1.0	%
Reticulocytes	53.5	3.0 - 50.0 K/ μ L
Reticulocyte Haemoglobin	14.9	13.2 - 20.8 pg
WBC	*36.40	2.87 - 17.02 x10 ⁹ /L
% Neutrophils	*43.7	%
% Lymphocytes	*21.2	%
% Monocytes	*8.2	%
% Eosinophils	*14.8	%
% Basophils	*12.1	%
Neutrophils	*15.91	2.30 - 10.29 x10 ⁹ /L
Lymphocytes	*7.71	0.92 - 6.88 x10 ⁹ /L
Monocytes	*3.00	0.05 - 0.67 x10 ⁹ /L
Eosinophils	*5.38	0.17 - 1.57 x10 ⁹ /L
Basophils	*4.40	0.01 - 0.26 x10 ⁹ /L
Platelets	261	151 - 600 x10 ⁹ /L
MPV	17.4	11.4 - 21.6 fL
Plateletcrit	0.45	0.17 - 0.86 %



And then there are the unusual cases - Patch



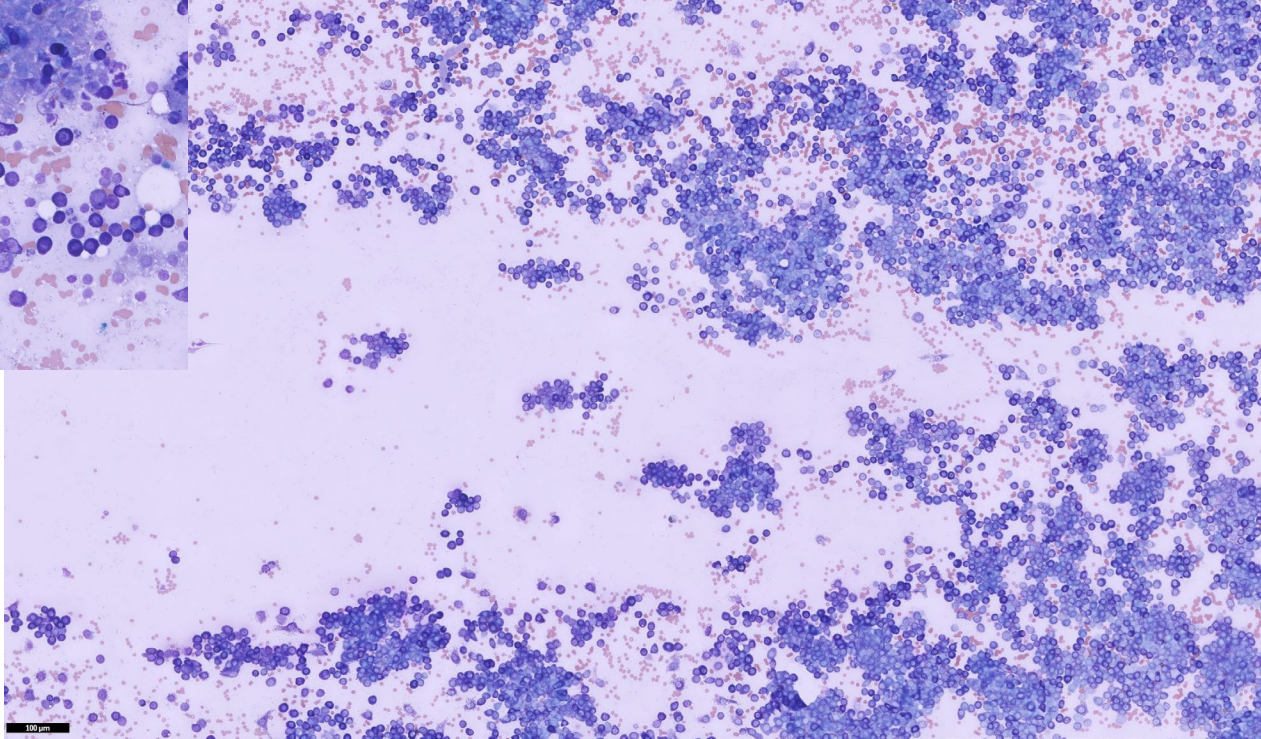
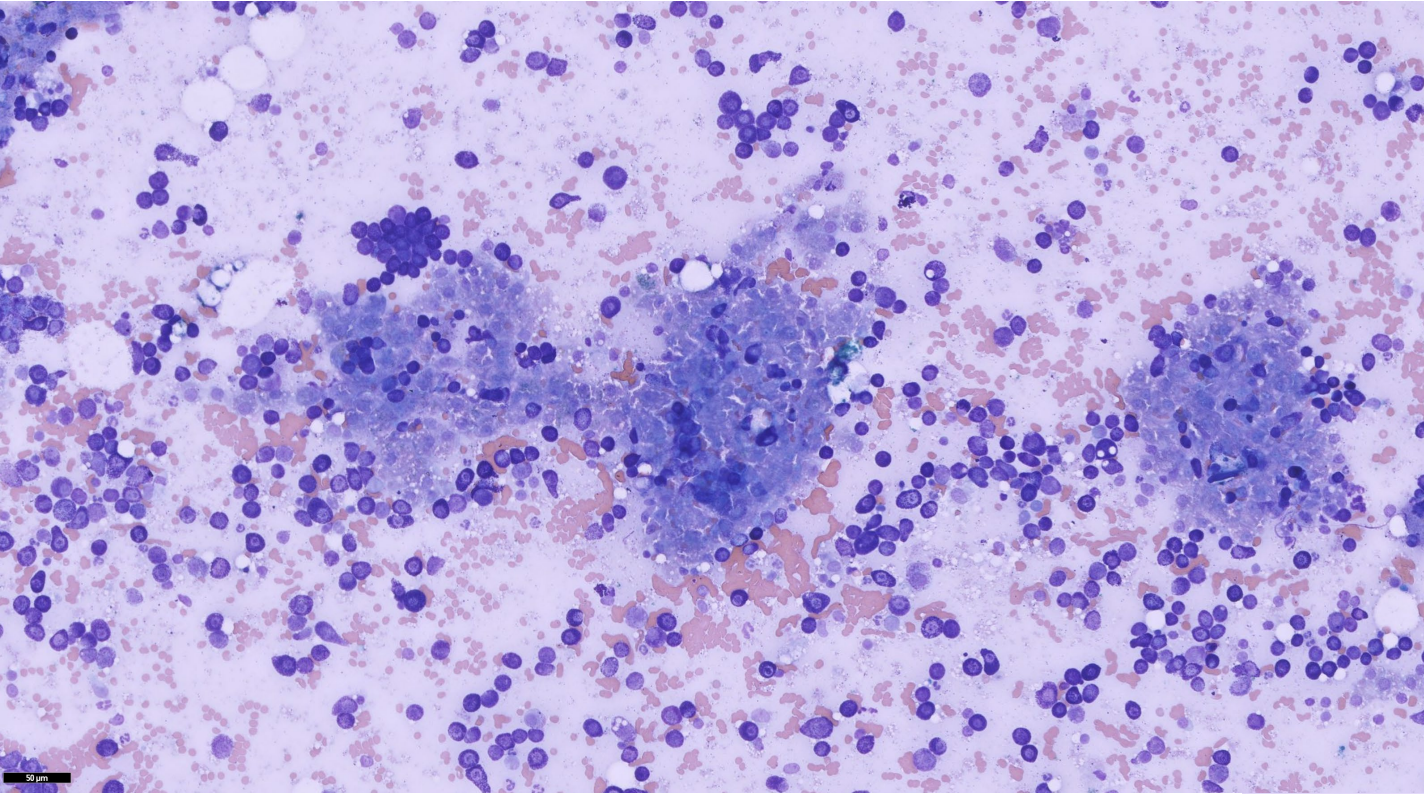
And then there are the unusual cases - Patch



Haematology		12/05/2026 14:42	
RBC	5.63	6.54 - 12.20 x10 ¹² /L	
Haematocrit	0.234	0.303 - 0.523 L/L	
Haemoglobin	76	98 - 162 g/L	
MCV	41.6	35.9 - 53.1 fL	
MCH	13.5	11.8 - 17.3 pg	
MCHC	325	281 - 358 g/L	
RDW	22.3	15.0 - 27.0 %	
% Reticulocytes	1.0	%	
Reticulocytes	53.5	3.0 - 50.0 K/ μ L	
Reticulocyte Haemoglobin	14.9	13.2 - 20.8 pg	
WBC	*36.40	2.87 - 17.02 x10 ⁹ /L	
% Neutrophils	*43.7	%	
% Lymphocytes	*21.2	%	
% Monocytes	*8.2	%	
% Eosinophils	*14.8	%	
% Basophils	*12.1	%	
Neutrophils	*15.91	2.30 - 10.29 x10 ⁹ /L	
Lymphocytes	*7.71	0.92 - 6.88 x10 ⁹ /L	
Monocytes	*3.00	0.05 - 0.67 x10 ⁹ /L	
Eosinophils	*5.38	0.17 - 1.57 x10 ⁹ /L	
Basophils	*4.40	0.01 - 0.26 x10 ⁹ /L	
Platelets	261	151 - 600 x10 ⁹ /L	
MPV	17.4	11.4 - 21.6 fL	
Plateletcrit	0.45	0.17 - 0.86 %	

Haematology		13/05/2026 08:13	
% Neutrophils	36.0	%	
% Lymphocytes	22.0	%	
% Monocytes	2.0	%	
% Eosinophils	2.0	%	
% Basophils	0.0	%	
% Mast Cells	38.0	%	
Blood Film Evaluation	<p>No morphological abnormalities detected in red blood cells and there is no increase in polychromasia. Leukocytosis with many mast cells seen. Neutrophil morphology appears normal. Estimation of free platelets (>8 platelets seen per HPF) suggesting platelet numbers are normal.</p>		

Patch – Liver and Spleen aspirates



And then there are the unusual cases - Nala

+ 10 Y

+ FE

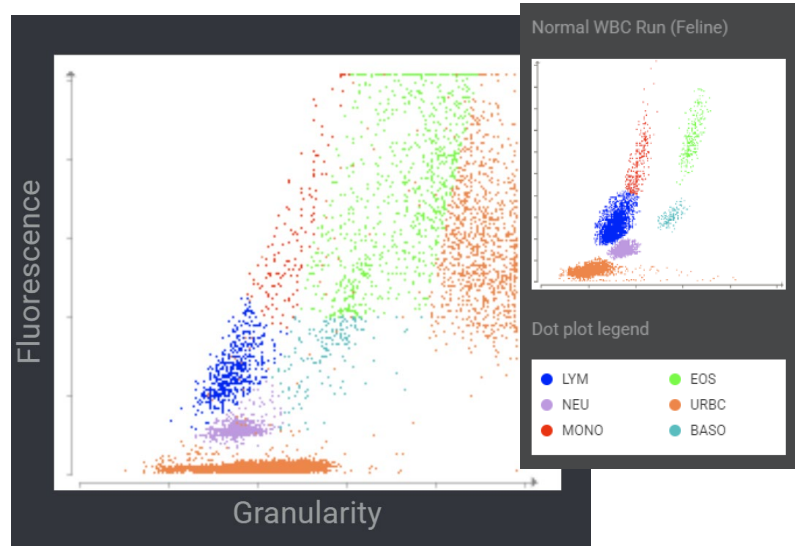
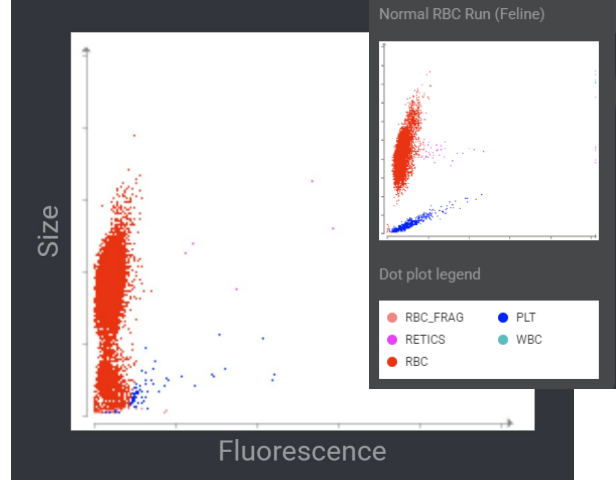
+ DSH

+ Hyperthyroidism check



Haematology		08/05/2026 14:13
RBC	2.63	6.54 - 12.20 x10 ¹² /L
Haematocrit	0.103	0.303 - 0.523 L/L
Haemoglobin	47	98 - 162 g/L
MCV	39.2	35.9 - 53.1 fL
MCH	17.9	11.8 - 17.3 pg
MCHC	456	281 - 358 g/L
RDW	23.7	15.0 - 27.0 %
% Reticulocytes	0.0	%
Reticulocytes	0.8	3.0 - 50.0 K/ μ L
Reticulocyte Haemoglobin	16.7	13.2 - 20.8 pg
WBC	*2.69	2.87 - 17.02 x10 ⁹ /L
% Neutrophils	*30.5	%
% Lymphocytes	*22.3	%
% Monocytes	*5.6	%
% Eosinophils	*34.9	%
% Basophils	-	%
Neutrophils	*0.82	2.30 - 10.29 x10 ⁹ /L
Lymphocytes	*0.60	0.92 - 6.88 x10 ⁹ /L
Monocytes	*0.15	0.05 - 0.67 x10 ⁹ /L
Eosinophils	*0.94	0.17 - 1.57 x10 ⁹ /L
Basophils	-	0.01 - 0.26 x10 ⁹ /L
Platelets	*2	151 - 600 x10 ⁹ /L
MPV	*15.5	11.4 - 21.6 fL
Plateletcrit	*0.00	0.17 - 0.86 %

Haematology		08/05/2026 14:13
RBC	2.63	6.54 - 12.20 x10 ¹² /L
Haematocrit	0.103	0.303 - 0.523 L/L
Haemoglobin	47	98 - 162 g/L
MCV	39.2	35.9 - 53.1 fL
MCH	17.9	11.8 - 17.3 pg
MCHC	456	281 - 358 g/L
RDW	23.7	15.0 - 27.0 %
% Reticulocytes	0.0	%
Reticulocytes	0.8	3.0 - 50.0 K/ μ L
Reticulocyte Haemoglobin	16.7	13.2 - 20.8 pg
WBC	*2.69	2.87 - 17.02 x10 ⁹ /L
% Neutrophils	*30.5	%
% Lymphocytes	*22.3	%
% Monocytes	*5.6	%
% Eosinophils	*34.9	%
% Basophils	-	%
Neutrophils	*0.82	2.30 - 10.29 x10 ⁹ /L
Lymphocytes	*0.60	0.92 - 6.88 x10 ⁹ /L
Monocytes	*0.15	0.05 - 0.67 x10 ⁹ /L
Eosinophils	*0.94	0.17 - 1.57 x10 ⁹ /L
Basophils	-	0.01 - 0.26 x10 ⁹ /L
Platelets	*2	151 - 600 x10 ⁹ /L
MPV	*15.5	11.4 - 21.6 fL
Plateletcrit	*0.00	0.17 - 0.86 %



PLT Aggregates Detected

* Confirm with dot plot and/or blood film review.

Anemia without reticulocytosis - Likely non-regenerative anemia; consider pre-regenerative anemia.

Platelet aggregates are detected. Platelet count may be higher than reported.

Increased MCHC or MCH - Consider hemolysis (including sample collection/handling), lipemia, and Heinz bodies.

In House

IDEXX Referral Laboratory

Haematology

08/05/2026 14:13

RBC	2.63	6.54 - 12.20 x10 ¹² /L
Haematocrit	0.103	0.303 - 0.523 L/L
Haemoglobin	47	98 - 162 g/L
MCV	39.2	35.9 - 53.1 fL
MCH	17.9	11.8 - 17.3 pg
MCHC	456	281 - 358 g/L
RDW	23.7	15.0 - 27.0 %
% Reticulocytes	0.0	%
Reticulocytes	0.8	3.0 - 50.0 K/ μ L
Reticulocyte Haemoglobin	16.7	13.2 - 20.8 pg
WBC	+2.69	2.87 - 17.02 x10 ⁹ /L
% Neutrophils	+30.5	%
% Lymphocytes	+22.3	%
% Monocytes	+5.6	%
% Eosinophils	+34.9	%
% Basophils	-	%
Neutrophils	+0.82	2.30 - 10.29 x10 ⁹ /L
Lymphocytes	+0.60	0.92 - 6.88 x10 ⁹ /L
Monocytes	+0.15	0.05 - 0.67 x10 ⁹ /L
Eosinophils	+0.94	0.17 - 1.57 x10 ⁹ /L
Basophils	-	0.01 - 0.26 x10 ⁹ /L
Platelets	+2	151 - 600 x10 ⁹ /L
MPV	+15.5	11.4 - 21.6 fL
Plateletcrit	+0.00	0.17 - 0.86 %

Haematology

10/05/2026 03:15

RBC	2.76	6.50 - 11.50 x10 ¹² /L
Haematocrit	a 0.105	0.310 - 0.510 L/L
Haemoglobin	b 55	106 - 167 g/L
MCV	38.0	38.0 - 53.0 fL
MCH	19.9	12.0 - 17.0 pg
MCHC	524	291 - 357 g/L
RDW	1.7	0.0 - 70.0 K/ μ L
% Reticulocytes	c ~	%
Reticulocyte Haemoglobin	c ~	pg
WBC	d 4.5	3.9 - 19.0 x10 ⁹ /L
% Neutrophils	26.0	%
% Lymphocytes	11.0	%
% Monocytes	2.0	%
% Eosinophils	9.0	%
% Basophils	0.0	%
Neutrophils	52.0	%
Lymphocytes	1.17	2.60 - 15.20 x10 ⁹ /L
Monocytes	0.50	0.70 - 6.90 x10 ⁹ /L
Eosinophils	0.09	0.00 - 0.50 x10 ⁹ /L
Basophils	0.41	0.20 - 1.20 x10 ⁹ /L
Basophils	0.00	0.00 - 0.10 x10 ⁹ /L
Unclassified	2.34	x10 ⁹ /L
Platelets	266	100 - 440 x10 ⁹ /L

Normal RBC Run (Feline)

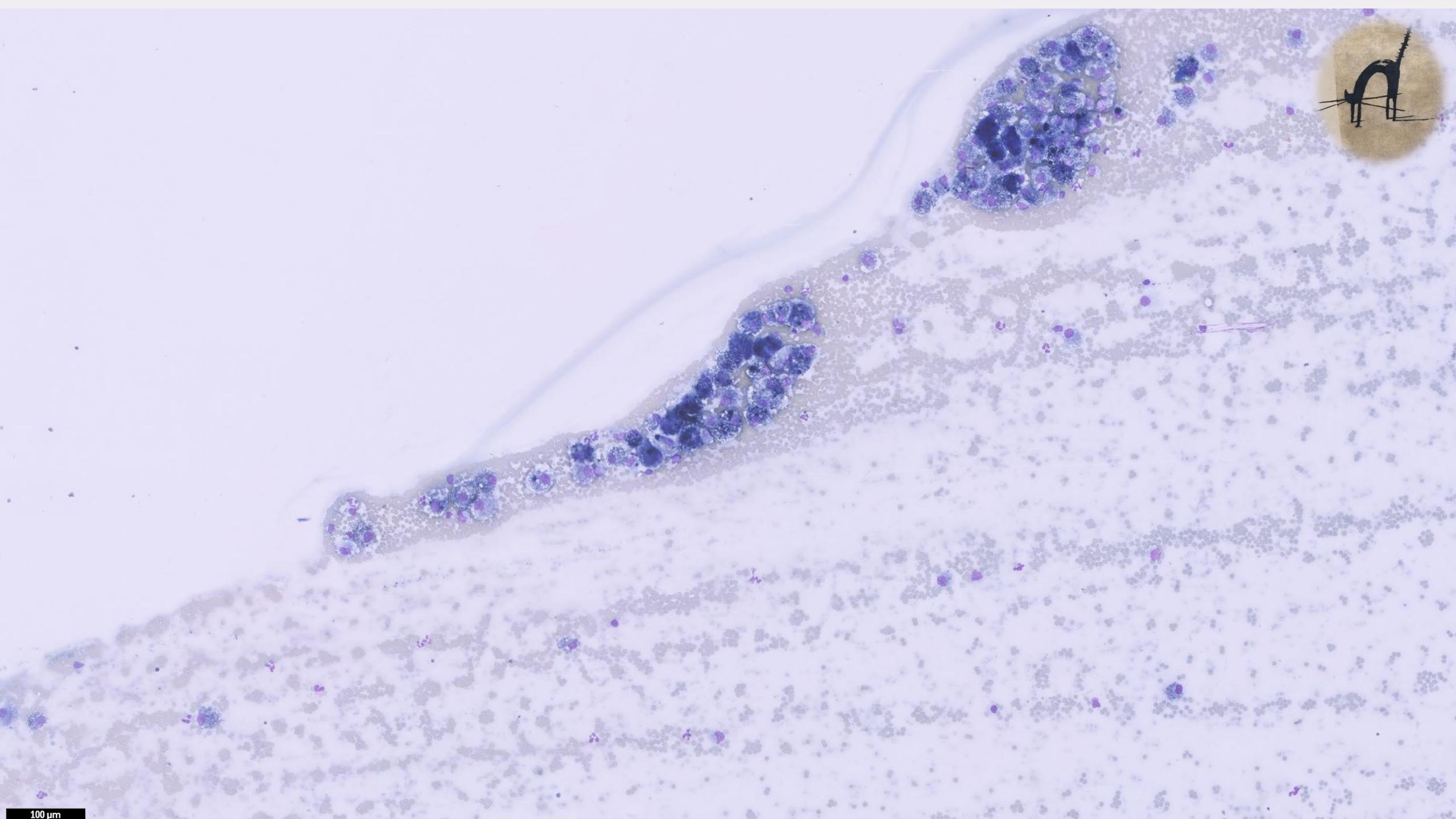
Dot plot legend

- RBC_FRAG (Red)
- RETICS (Pink)
- RBC (Orange)
- PLT (Blue)
- WBC (Teal)

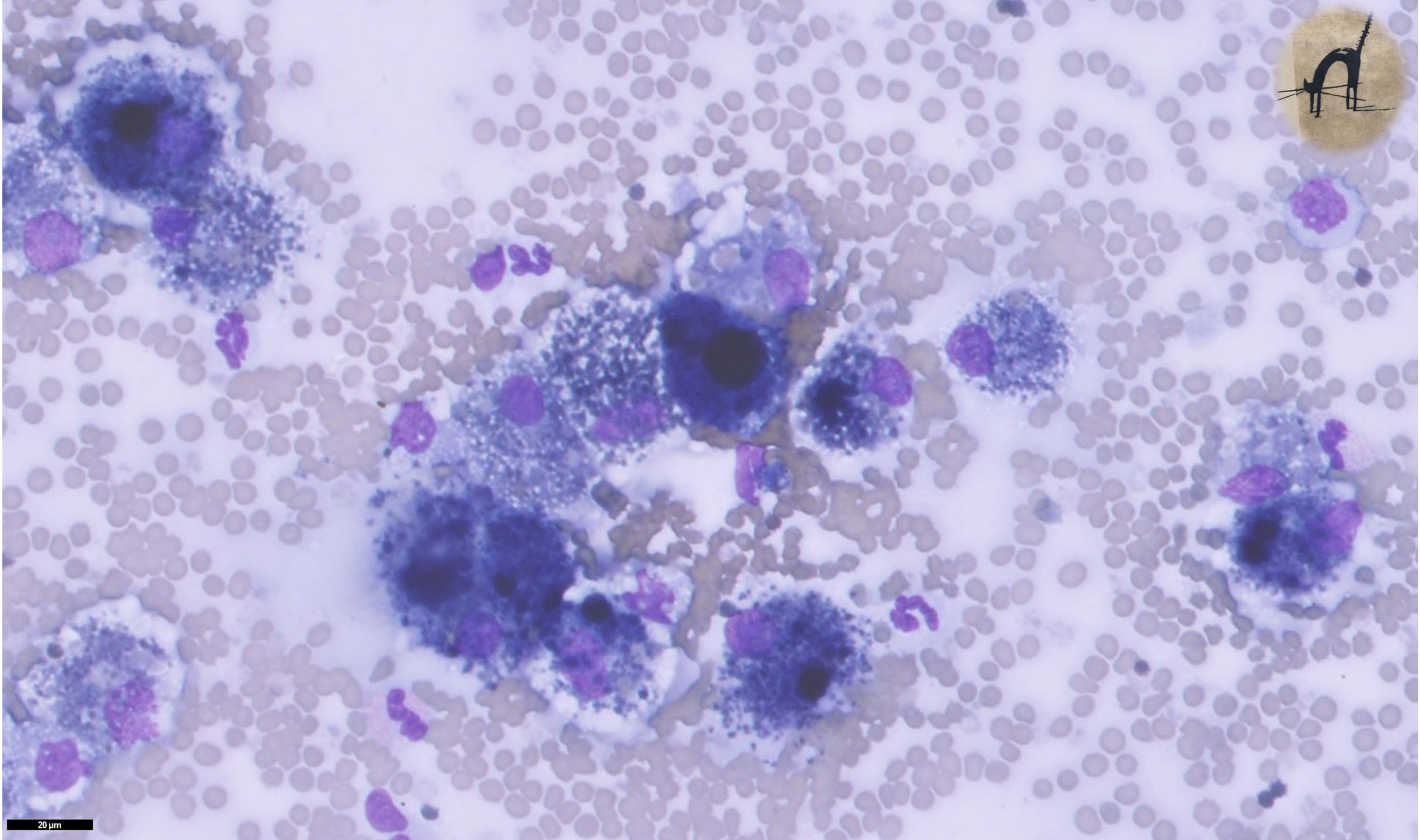
Normal WBC Run (Feline)

Dot plot legend

- LYM (Blue)
- NEU (Purple)
- MONO (Orange)
- EOS (Green)
- URBC (Red)
- BASO (Teal)

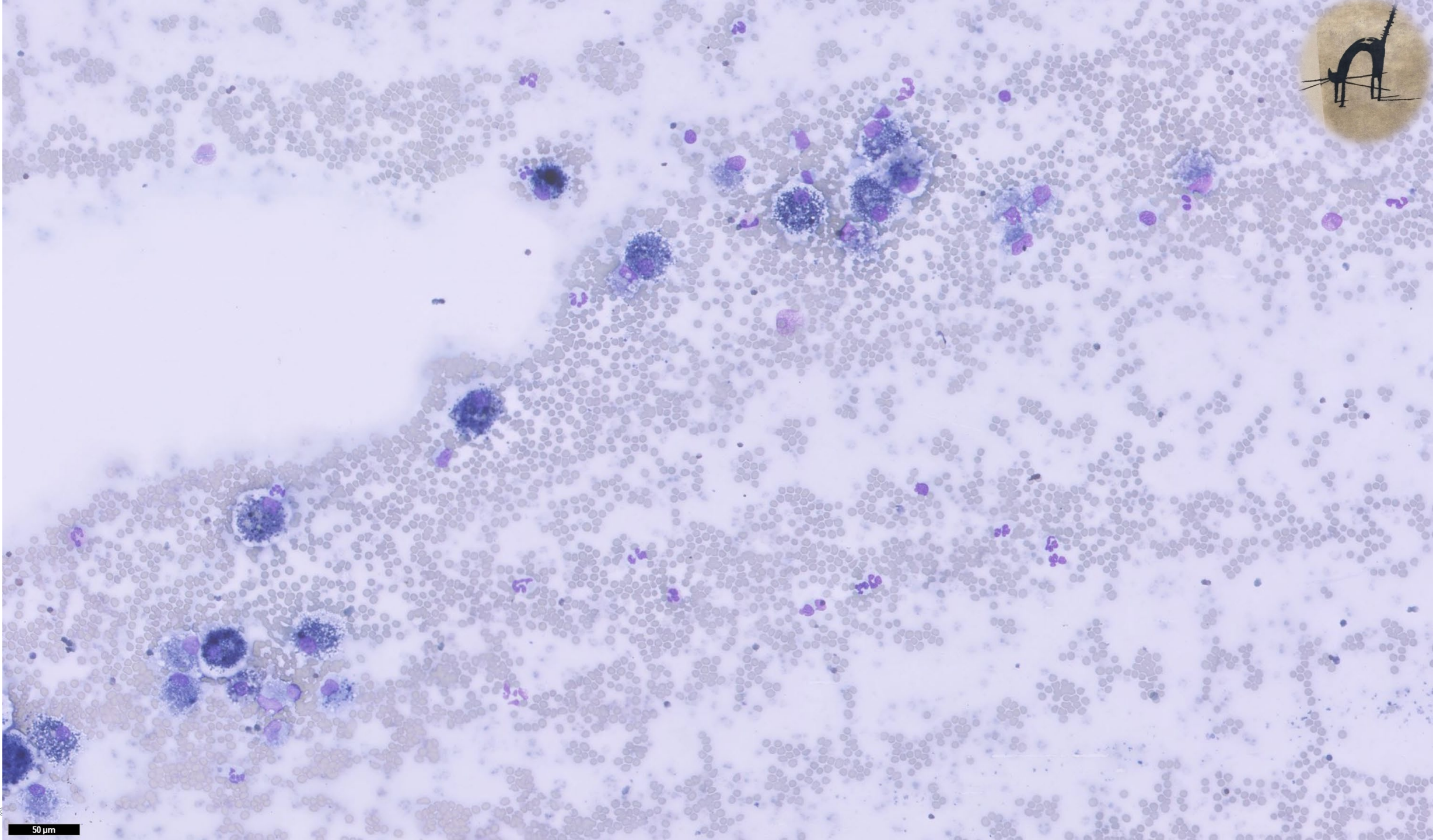


100 μ m



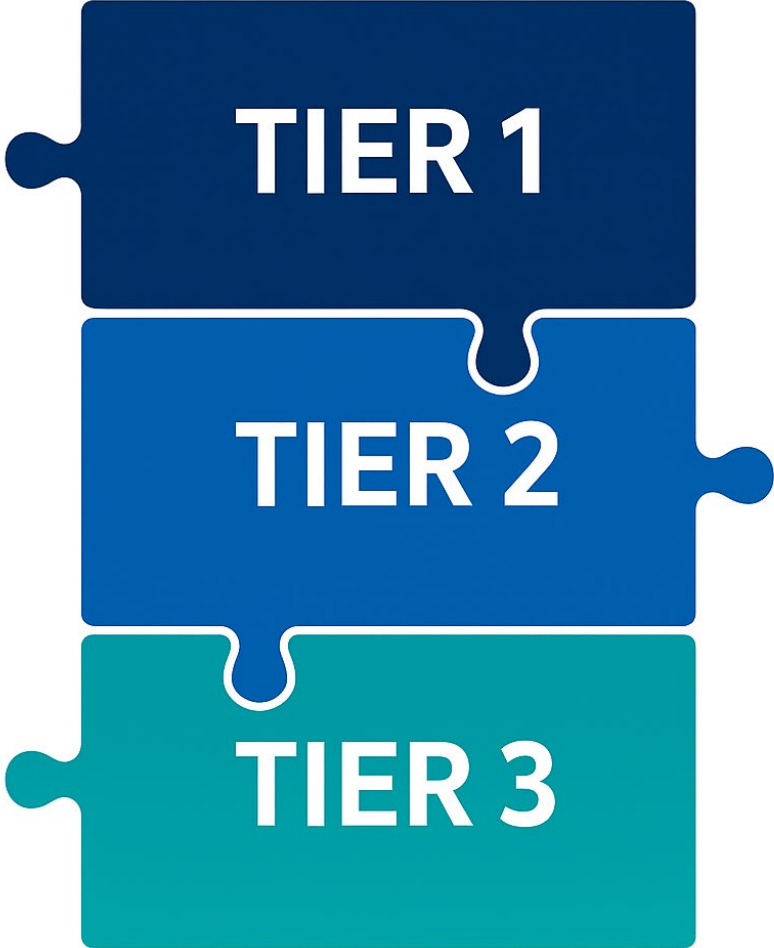
20 μ m

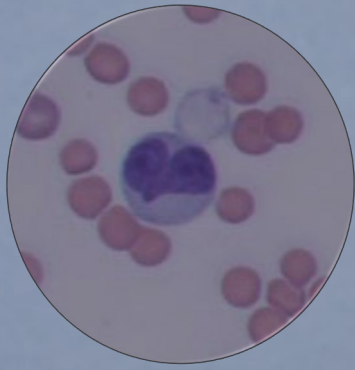
©



50 μ m

Take home message





Take home MSG

- Even with best analyzers...
Blood smear exam allows you to get more out of your CBC results
- Start with a good quality smear
- Have a systematic approach
- Cross check findings with analyzer and history
- If in doubt... refer...get us to help out!

IDEXX