

Cell-fies: practical use of AI powered blood cell morphology to guide clinical decisions

Presenters: Marta Costa

Alice Tamborini

Date: 11th June 2026

IDEXX

Disclosure:

Marta Costa and Alice Tamborini are Full-time
Employees of IDEXX



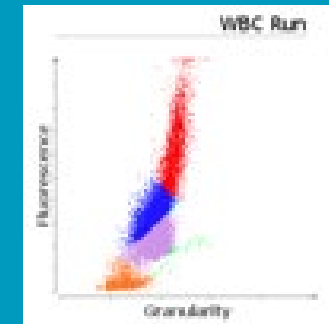
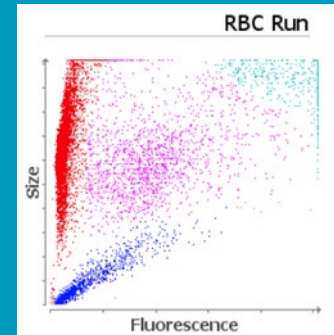
The information contained herein is intended to provide general guidance only. As with any diagnosis or treatment you should use clinical discretion with each patient based on a complete evaluation of the patient, including history, physical exam and presentation, and laboratory data. With respect to any drug therapy or monitoring program, you should refer to applicable product insert(s) for complete description of dosage, indications, interactions, and cautions. Diagnosis, treatment, and monitoring should be patient specific and is the responsibility of the veterinarian providing primary care. (2026)

TIER 1

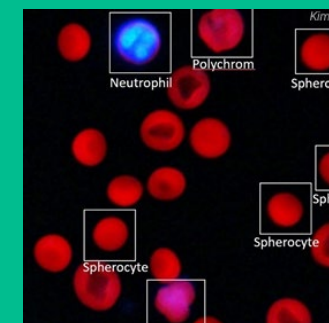
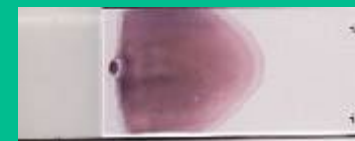RBC	1.09 Mj/L	5.65 - 8.87	LOW						
HCT	9.8 %	37.3 - 61.7	LOW						
HGB	3.9 g/dL	13.1 - 20.5	LOW						
MCV	89.9 fL	81.6 - 101.5	HIGH						
MCH	35.8 pg	21.2 - 25.9	HIGH						
MCHC	39.8 g/dL	32.0 - 37.9	HIGH						
RDW	*28.3 %	13.6 - 21.7	HIGH						
%RETIC	17.0 %								
RETIC	186.8 Kj/L	10.0 - 110.0	HIGH						
RETIC-HGB	25.8 pg	22.3 - 29.6							
WBC	43.20 Kj/L	5.05 - 16.76	HIGH						
%NEU	*66.2 %								
%LYM	*21.6 %								
%MONO	*8.9 %								
%EOS	0.2 %								
%BASO	0.1 %								
NEU	*29.88 Kj/L	2.95 - 11.84	HIGH						
BAND	*Suspected								
LYM	*9.34 Kj/L	1.05 - 5.10	HIGH						
MONO	*3.85 Kj/L	0.16 - 1.12	HIGH						
EOS	0.09 Kj/L	0.06 - 1.23							
BASO	0.03 Kj/L	0.00 - 0.10							
PLT	*60 Kj/L	148 - 484	LOW						
MPV	19.7 fL	8.7 - 13.2	HIGH						
PDW	---	9.1 - 19.4							
PCT	0.12 %	0.14 - 0.46	LOW						

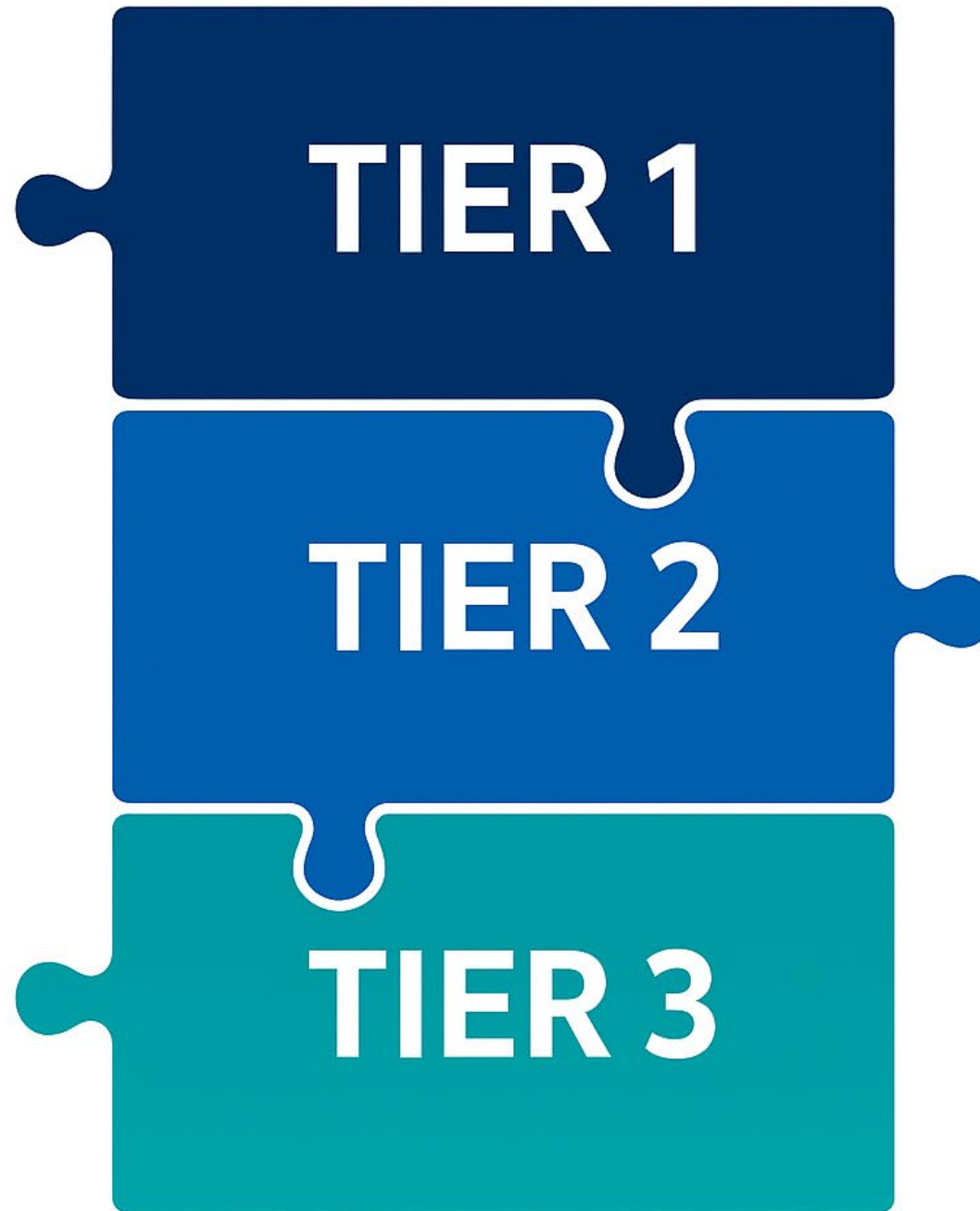
* Confirm with dot plot and/or blood film review.

TIER 2



TIER 3



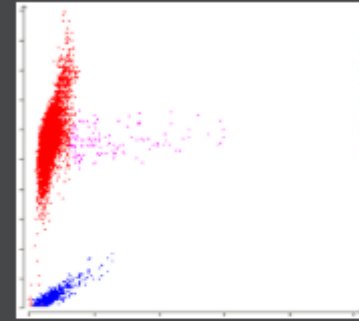


Jack, 3 years old, male entire, cross breed

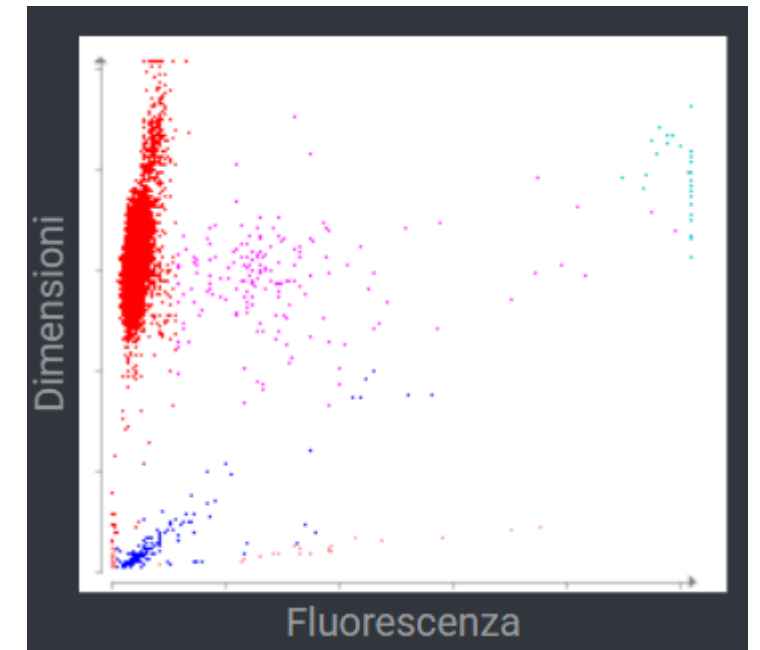

Haematology		09/03/2026 12:34	
RBC	5.12	5.65 - 8.87 x10 ¹² /L	
Haematocrit	0.323	0.373 - 0.617 L/L	
Haemoglobin	122	131 - 205 g/L	
MCV	63.1	61.6 - 73.5 fL	
MCH	23.8	21.2 - 25.9 pg	
MCHC	378	320 - 379 g/L	
RDW	13.7	13.6 - 21.7 %	
% Reticulocytes	0.7	%	
Reticulocytes	36.9	10.0 - 110.0 K/ μ L	
Reticulocyte Haemoglobin	24.0	22.3 - 29.6 pg	
Platelets	*17	148 - 484 x10 ⁹ /L	
PDW	-	9.1 - 19.4 fL	
MPV	15.1	8.7 - 13.2 fL	
Plateletcrit	0.03	0.14 - 0.46 %	



Analisi RBC di riferimento (Cane)



Legenda diagramma a punti



* Confirm with dot plot and/or blood film review.

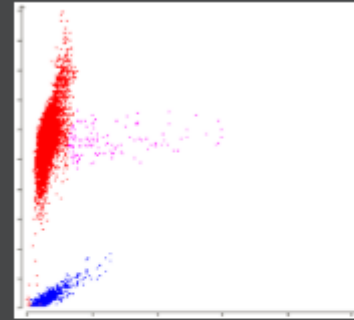
Jack, 3 years old, male entire, cross breed

Haematology		09/03/2026 12:34
RBC	5.12	5.65 - 8.87 x10 ¹² /L
Haematocrit	0.323	0.373 - 0.617 L/L
Haemoglobin	122	131 - 205 g/L
MCV	63.1	61.6 - 73.5 fL
MCH	23.8	21.2 - 25.9 pg
MCHC	378	320 - 379 g/L
RDW	13.7	13.6 - 21.7 %
% Reticulocytes	0.7	%
Reticulocytes	36.9	10.0 - 110.0 K/ μ L
Reticulocyte Haemoglobin	24.0	22.3 - 29.6 pg
Platelets	*17	148 - 484 x10 ⁹ /L
PDW	-	9.1 - 19.4 fL
MPV	15.1	8.7 - 13.2 fL
Plateletcrit	0.03	0.14 - 0.46 %

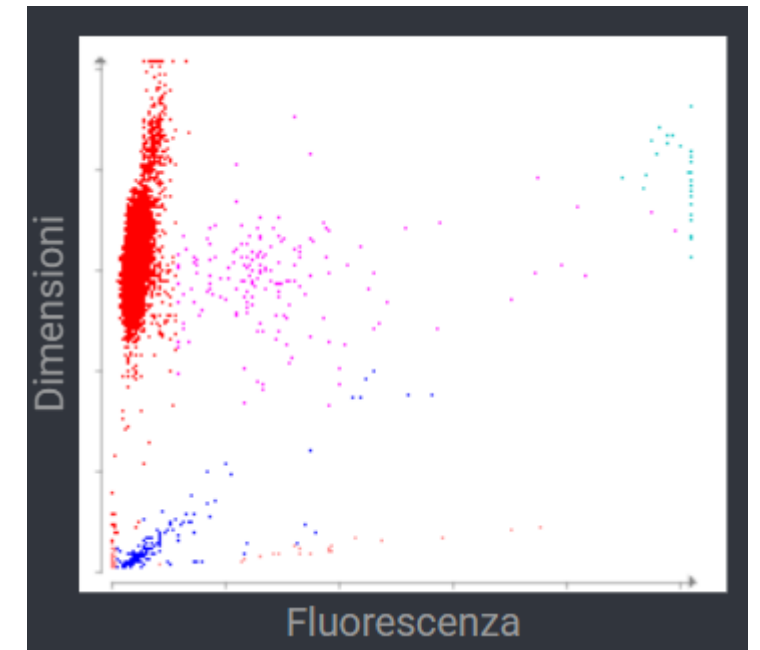
* Confirm with dot plot and/or blood film review.



Analisi RBC di riferimento (Cane)



Legenda diagramma a punti

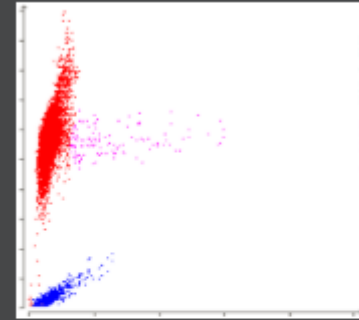


Jack, 3 years old, male entire, cross breed

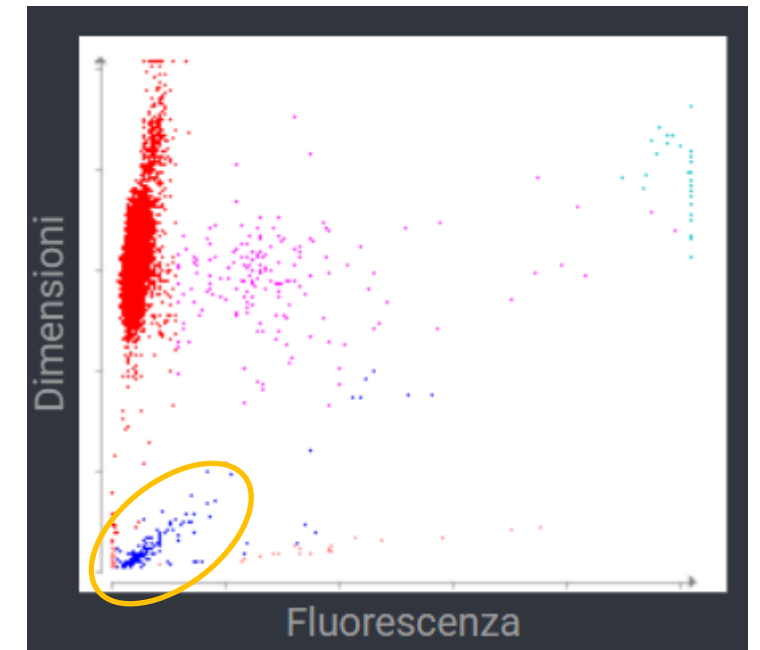
Haematology		09/03/2026 12:34	
RBC	5.12	5.65 - 8.87 x10 ¹² /L	
Haematocrit	0.323	0.373 - 0.617 L/L	
Haemoglobin	122	131 - 205 g/L	
MCV	63.1	61.6 - 73.5 fL	
MCH	23.8	21.2 - 25.9 pg	
MCHC	378	320 - 379 g/L	
RDW	13.7	13.6 - 21.7 %	
% Reticulocytes	0.7	%	
Reticulocytes	36.9	10.0 - 110.0 K/ μ L	
Reticulocyte Haemoglobin	24.0	22.3 - 29.6 pg	
Platelets	*17	148 - 484 x10 ⁹ /L	
PDW	-	9.1 - 19.4 fL	
MPV	15.1	8.7 - 13.2 fL	
Plateletcrit	0.03	0.14 - 0.46 %	



Analisi RBC di riferimento (Cane)



Legenda diagramma a punti




* Confirm with dot plot and/or blood film review.

Jack, 3 years old, male entire, cross breed



Haematology		09/03/2026 16:45
RBC	a	5.12 5.65 - 8.87 x10 ¹² /L
Haematocrit	b	0.323 0.373 - 0.617 L/L
% Reticulocytes		0.7 %
Reticulocytes	c	36.9 10.0 - 110.0 K/ μ L
Platelet Estimate		<50 K/uL (Markedly decreased)
Diagnostic Considerations		<p>Agglutination and spherocytes were not detected.</p> <p>This platelet estimate incorporates enumeration of individual platelets and platelets within clumps. With the exception of canine patients with congenital macrothrombocytopenia, markedly decreased platelet counts (less than 50 K/uL) place the patient at risk of bleeding from surgery/trauma or spontaneously (especially if there is a concurrent platelet function defect or platelets are less than 30 K/uL). Evaluate the patient for petechia and ecchymoses. Consider immune-mediated thrombocytopenia (primary and secondary) for markedly decreased platelet counts. If this finding is unexpected, please redraw a new sample to rule out artifactual thrombocytopenia (e.g., clot in the blood tube).</p> <p>There is no evidence of RBC regeneration in response to the anemia at this time. Consider pre-regenerative anemia or causes of nonregenerative anemia. Continue monitoring the CBC for development of a regenerative response.</p>



Jack, 3 years old, male entire, cross breed



Haematology		09/03/2026 16:45
RBC	a	5.12 5.65 - 8.87 x10 ¹² /L
Haematocrit	b	0.323 0.373 - 0.617 L/L
% Reticulocytes		0.7 %
Reticulocytes	c	36.9 10.0 - 110.0 K/ μ L

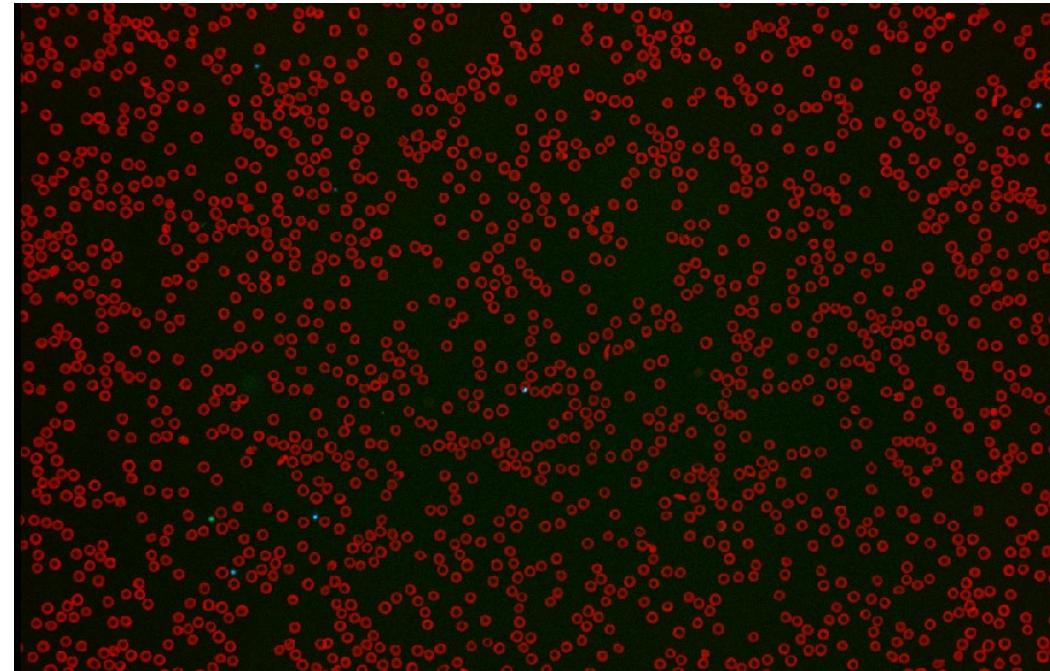
Platelet Estimate	<50 K/uL (Markedly decreased)
-------------------	-------------------------------

Diagnostic Considerations


Agglutination and spherocytes were not detected.

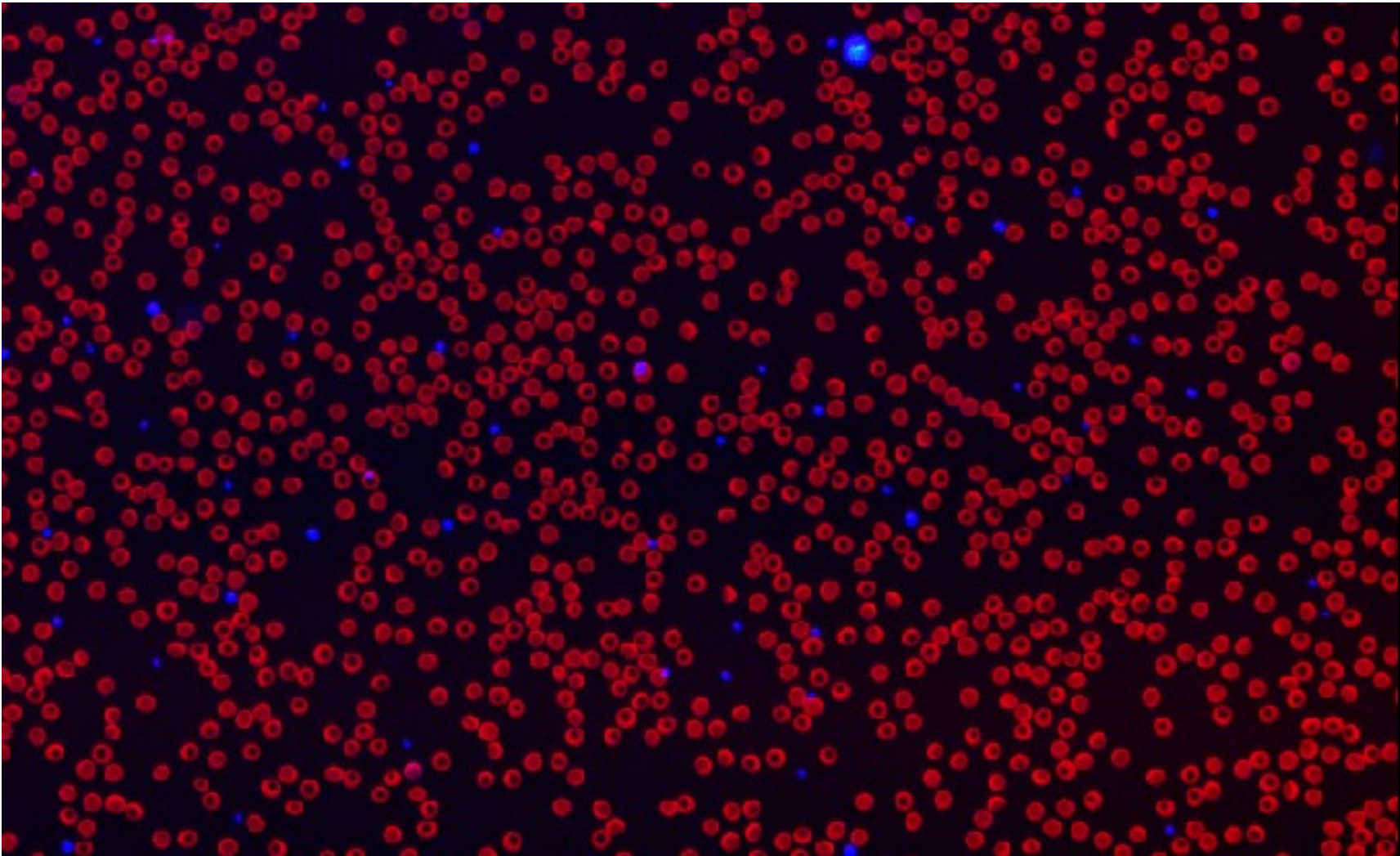
This platelet estimate incorporates enumeration of individual platelets and platelets within clumps. With the exception of canine patients with congenital macrothrombocytopenia, markedly decreased platelet counts (less than 50 K/uL) place the patient at risk of bleeding from surgery/trauma or spontaneously (especially if there is a concurrent platelet function defect or platelets are less than 30 K/uL). Evaluate the patient for petechia and ecchymoses. Consider immune-mediated thrombocytopenia (primary and secondary) for markedly decreased platelet counts. If this finding is unexpected, please redraw a new sample to rule out artifactual thrombocytopenia (e.g., clot in the blood tube).

There is no evidence of RBC regeneration in response to the anemia at this time. Consider pre-regenerative anemia or causes of nonregenerative anemia. Continue monitoring the CBC for development of a regenerative response.

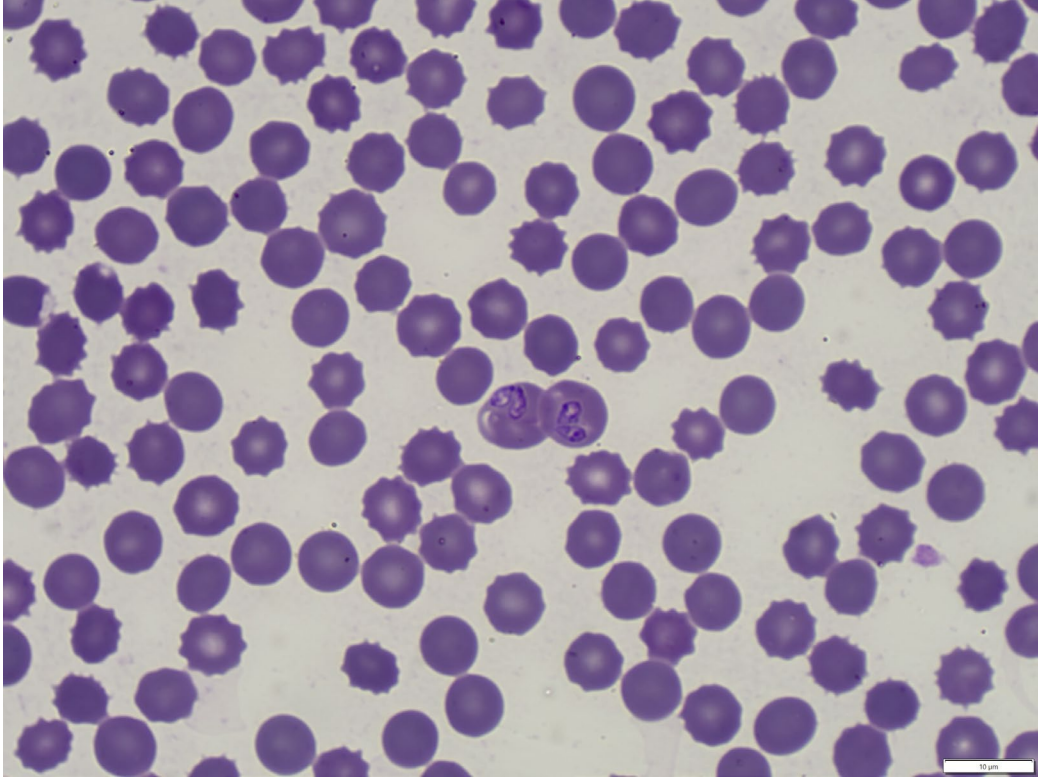


Jack, 3 years old, male entire, cross breed





Jack, 3 years old, male entire, cross breed

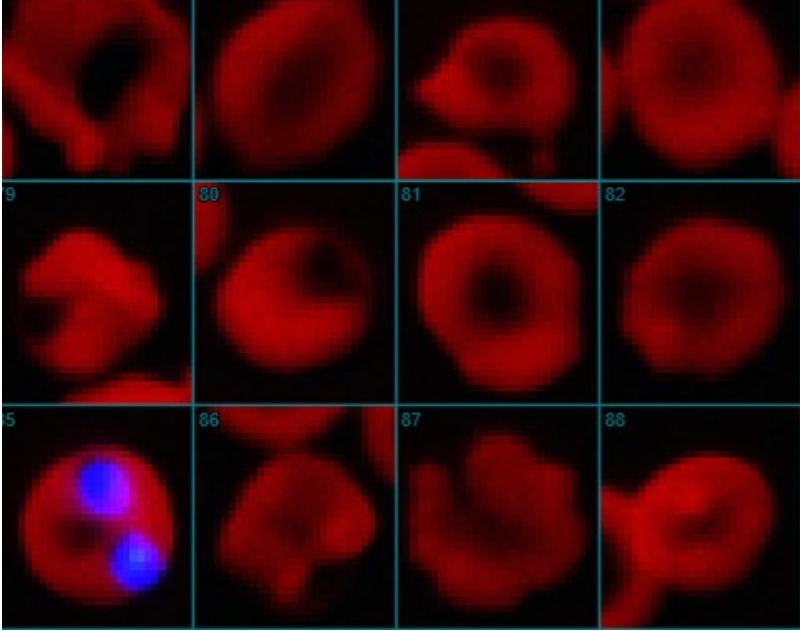
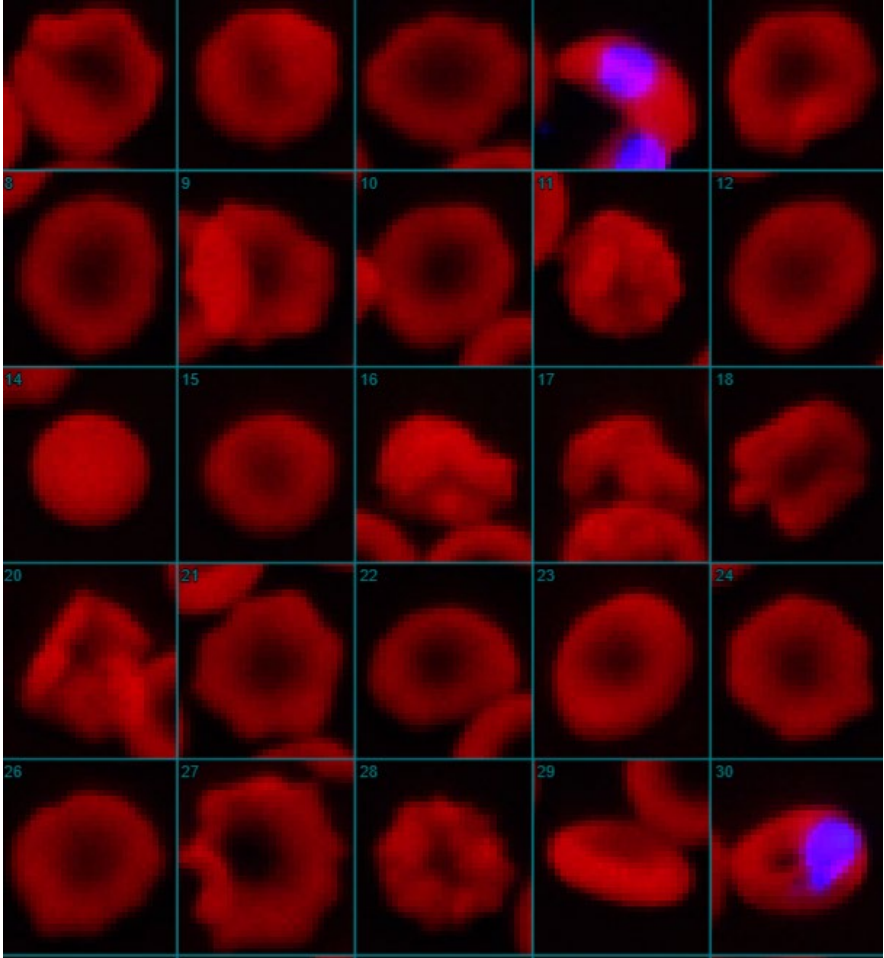


Courtesy of Esther Torrent, IDEXX

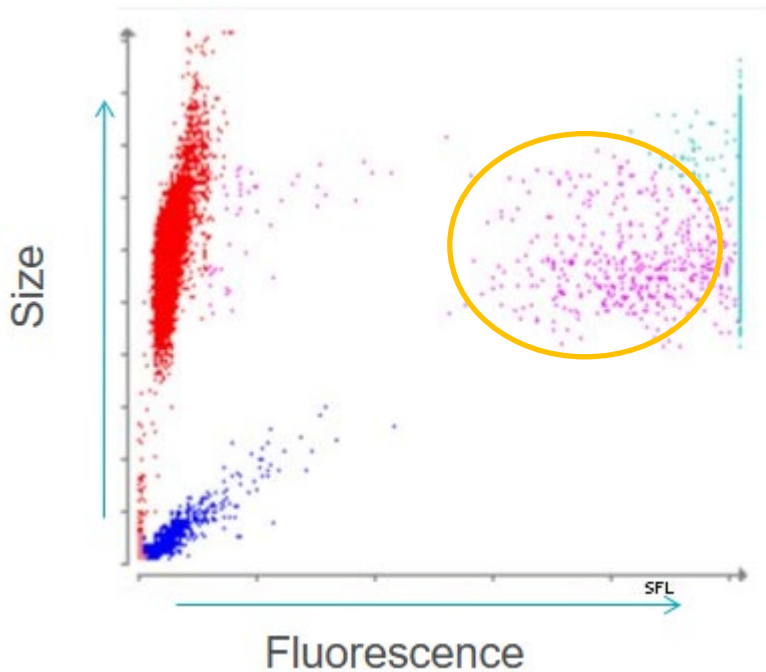
Babesia spp. RealPCR™

- Babesia spp. (DNA) real-time PCR
- Babesia canis canis (DNA) real-time PCR ✓
- Babesia canis rossi (DNA) real-time PCR ✗
- Babesia canis vogeli (DNA) real-time PCR ✗
- Babesia conradae (DNA) real-time PCR ✗
- Babesia gibsoni (DNA) real-time PCR ✗

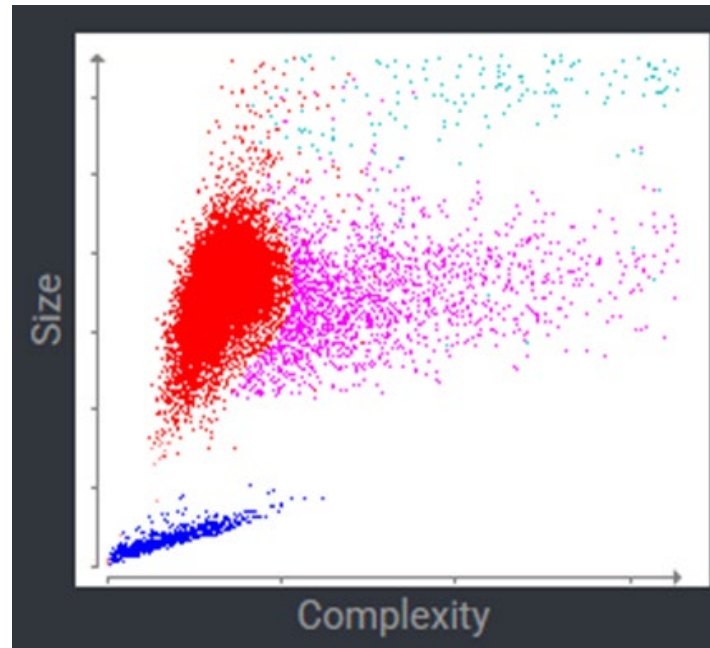
Jack, 3 years old, male entire, cross breed



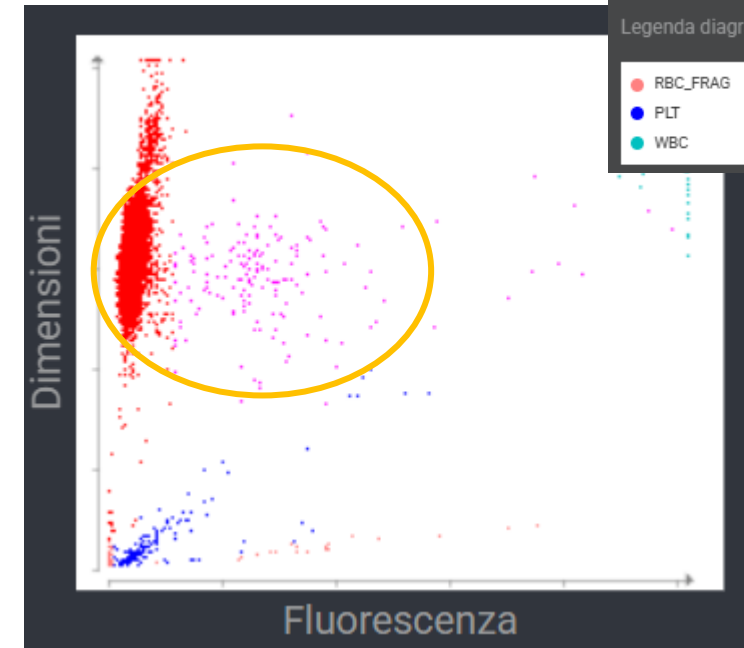
Spurious reticulocyte counts



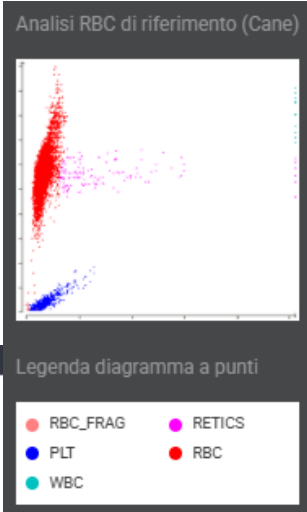
Case of Babesiosis



Regenerative anaemia



Jack's Dot plot



Spurious reticulocyte profile in dogs with large form babesiosis: a retrospective study (VCP, 2016)

Tvedten H. What is your diagnosis? Discrepancy between Sysmex XT-2000iV reticulocyte count and polychromasia. (VCP 2011)

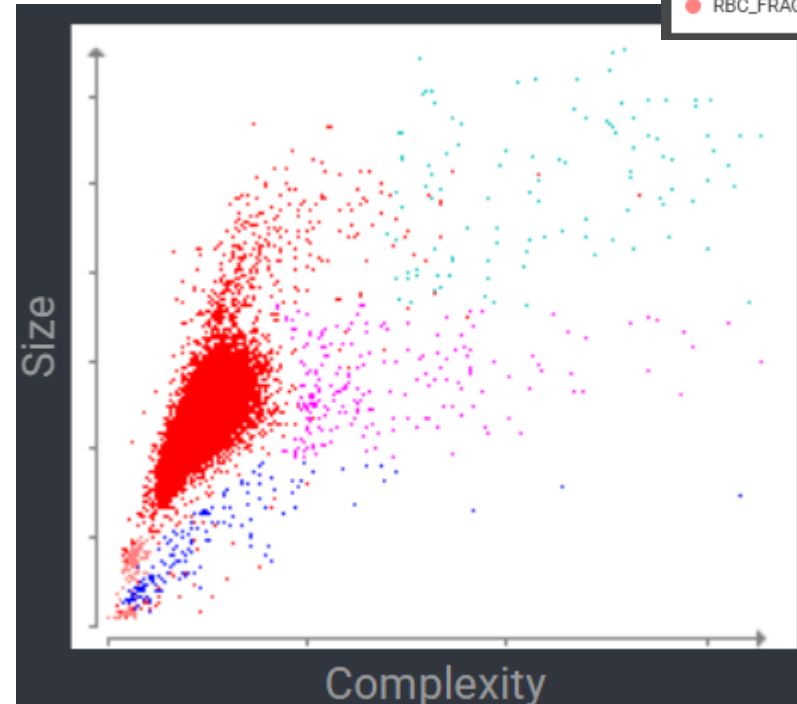
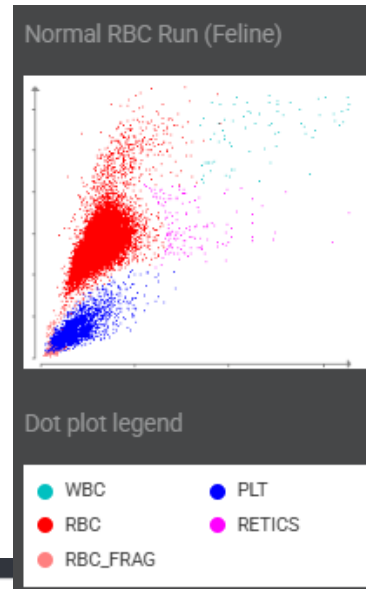
Analytic errors in Sysmex-generated hematology results in blood from a dog with chronic lymphocytic leukemia (VCP2015)

Missy, 1 year old, FE DSH

Haematology		29/08/2025	12:50
RBC	9.19	6.54 - 12.20 x10 ¹² /L	
Haematocrit	0.46	0.303 - 0.523 L/L	
Haemoglobin	151	98 - 162 g/L	
MCV	50.1	35.9 - 53.1 fL	
MCH	16.4	11.8 - 17.3 pg	
MCHC	327	281 - 358 g/L	
RDW	21.5	15.0 - 27.0 %	
% Reticulocytes	0.3	%	
Reticulocytes	25.0	3.0 - 50.0 K/ μ L	
Platelets	*17	151 - 600 x10 ⁹ /L	
MPV	-	11.4 - 21.6 fL	
Plateletcrit	-	0.17 - 0.86 %	

* Confirm with dot plot and/or blood film review.

Platelet aggregates are detected. Platelet count may be higher than reported.

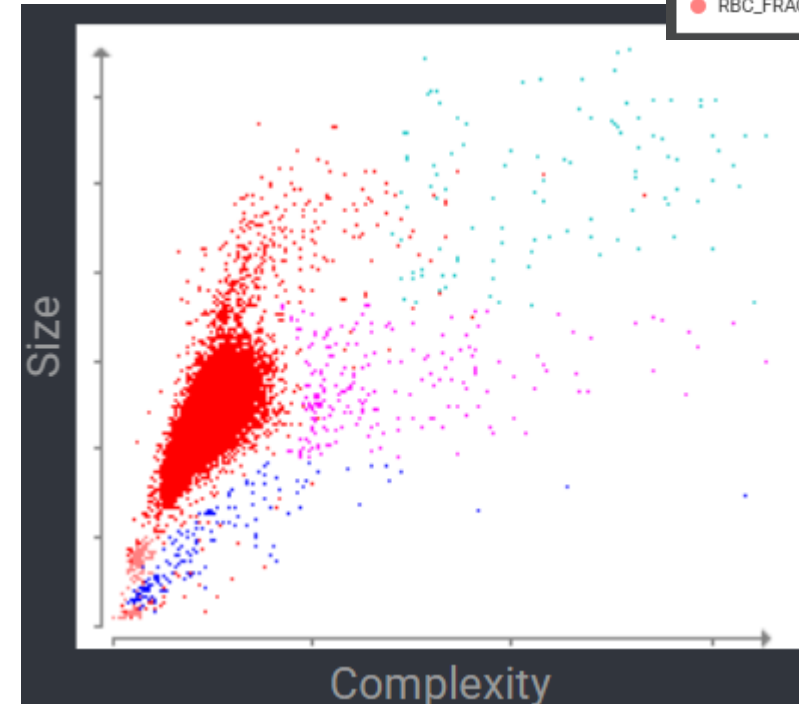
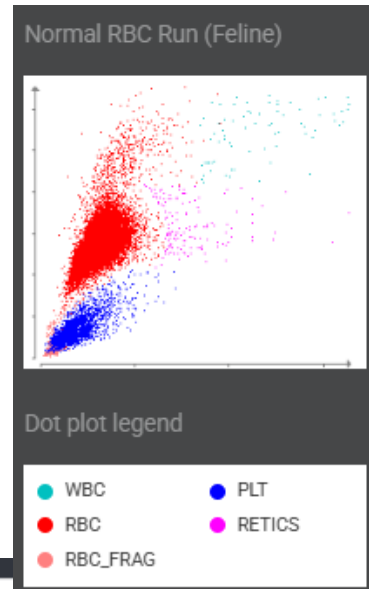


Missy, 1 year old, FE DSH

Haematology		29/08/2025	12:50
RBC	9.19	6.54 - 12.20 x10 ¹² /L	
Haematocrit	0.46	0.303 - 0.523 L/L	
Haemoglobin	151	98 - 162 g/L	
MCV	50.1	35.9 - 53.1 fL	
MCH	16.4	11.8 - 17.3 pg	
MCHC	327	281 - 358 g/L	
RDW	21.5	15.0 - 27.0 %	
% Reticulocytes	0.3	%	
Reticulocytes	25.0	3.0 - 50.0 K/ μ L	
Platelets	*17	151 - 600 x10 ⁹ /L	
MPV	-	11.4 - 21.6 fL	
Plateletcrit	-	0.17 - 0.86 %	

* Confirm with dot plot and/or blood film review.

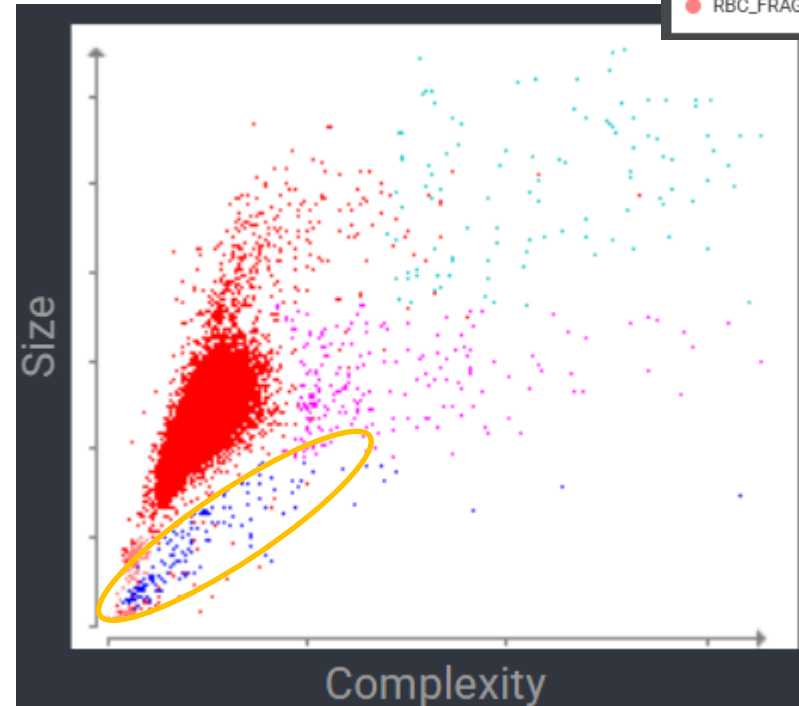
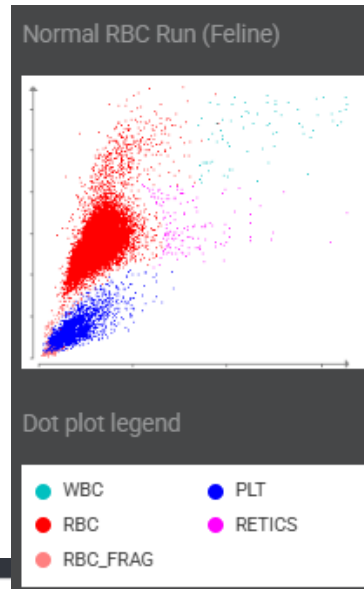
Platelet aggregates are detected. Platelet count may be higher than reported.



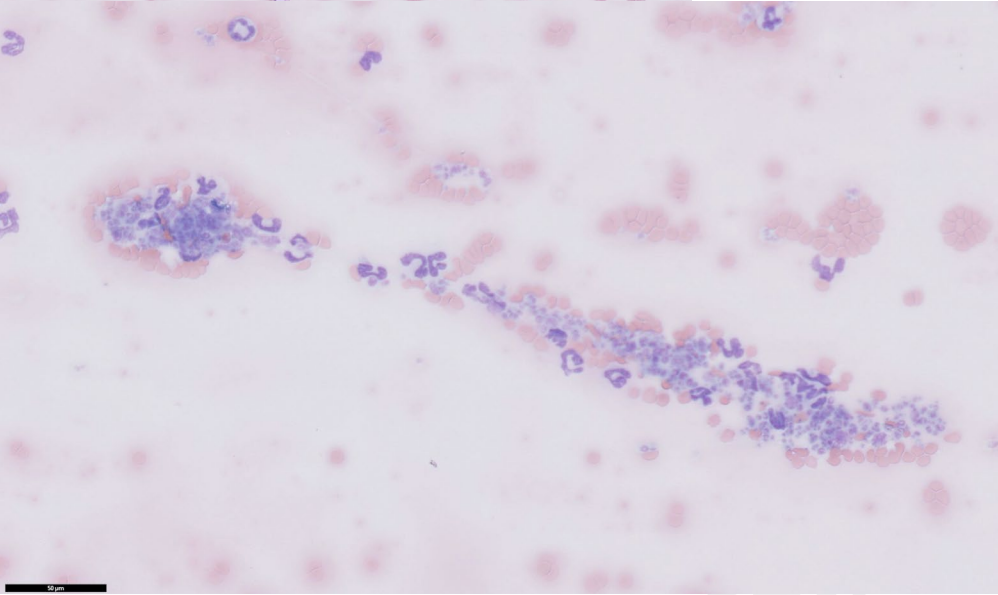
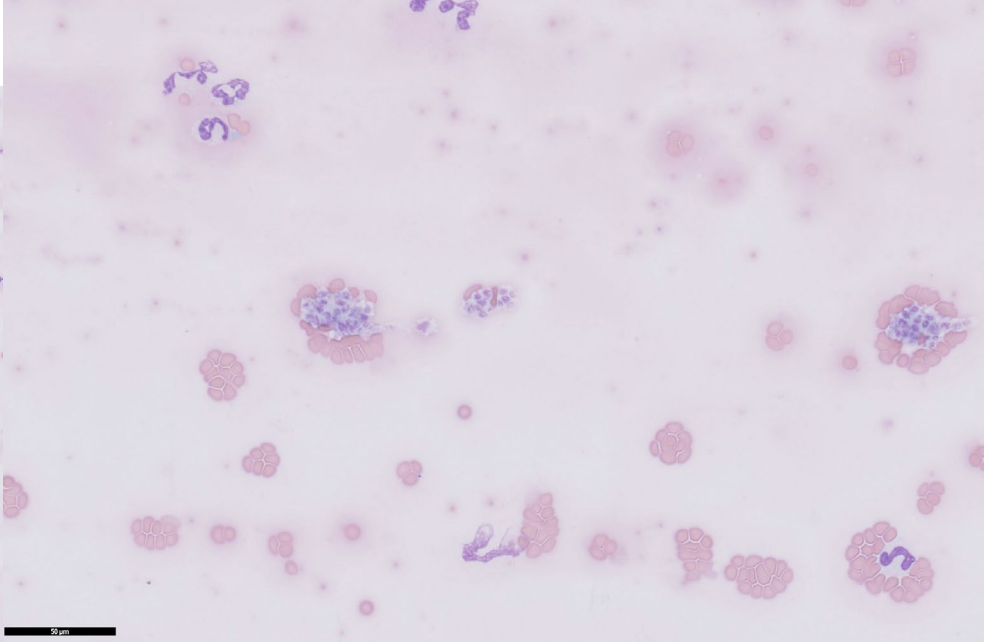
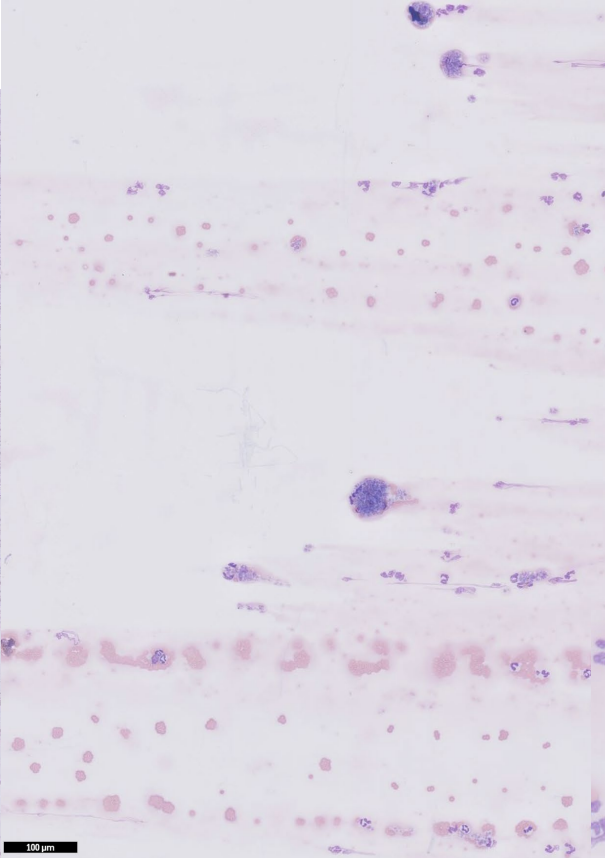
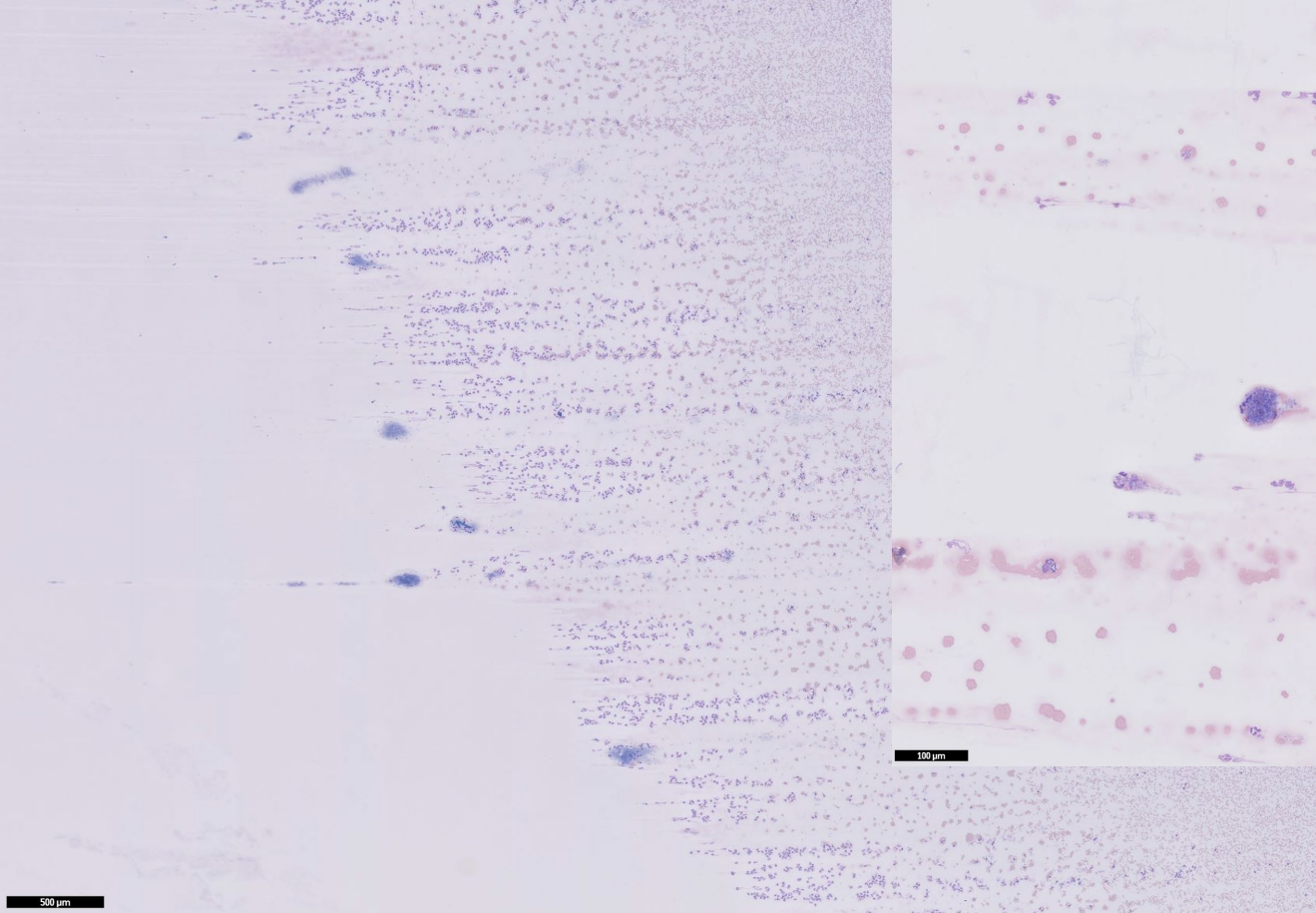
Missy, 1 year old, FE DSH

Haematology		29/08/2025	12:50
RBC	9.19	6.54 - 12.20 x10 ¹² /L	
Haematocrit	0.46	0.303 - 0.523 L/L	
Haemoglobin	151	98 - 162 g/L	
MCV	50.1	35.9 - 53.1 fL	
MCH	16.4	11.8 - 17.3 pg	
MCHC	327	281 - 358 g/L	
RDW	21.5	15.0 - 27.0 %	
% Reticulocytes	0.3	%	
Reticulocytes	25.0	3.0 - 50.0 K/ μ L	
Platelets	*17	151 - 600 x10 ⁹ /L	
MPV	-	11.4 - 21.6 fL	
Plateletcrit	-	0.17 - 0.86 %	

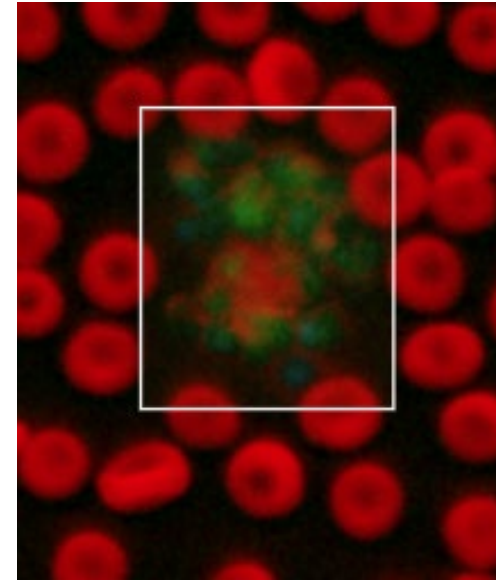

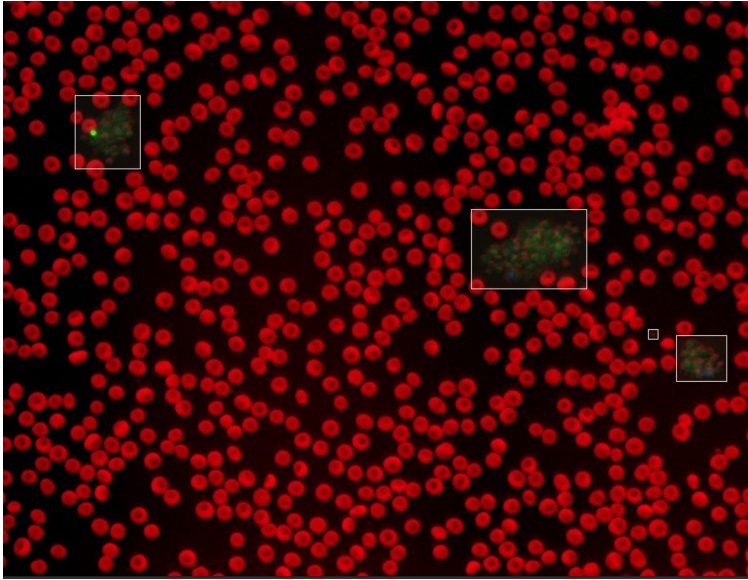
* Confirm with dot plot and/or blood film review.
 Platelet aggregates are detected. Platelet count may be higher than reported.



Missy, 1 year old, FE DSH



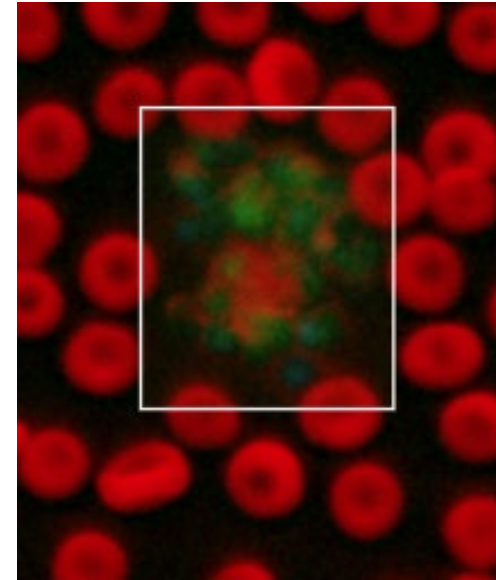

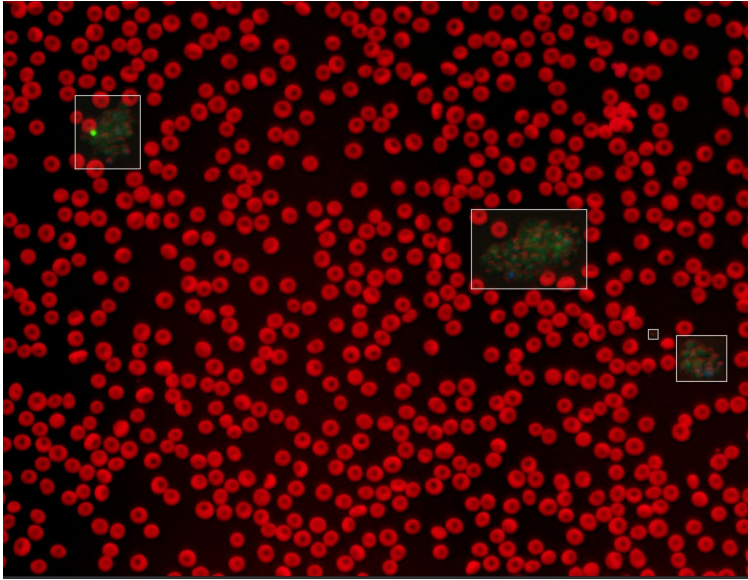
Missy, 1 year old, FE DSH



Platelet Estimate >150 K/uL
 (Adequate)

Diagnostic Considerations This platelet estimate incorporates enumeration of individual platelets and platelets within clumps. Platelet count is above 150 K/uL.

Missy, 1 year old, FE DSH



Platelet Estimate >150 K/uL
 (Adequate)

Diagnostic Considerations This platelet estimate incorporates enumeration of individual platelets and platelets within clumps. Platelet count is above 150 K/uL.

Milo, 3 months old, male entire, beagle



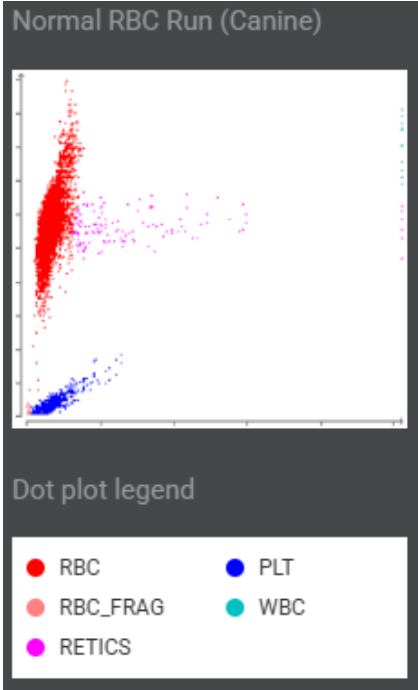
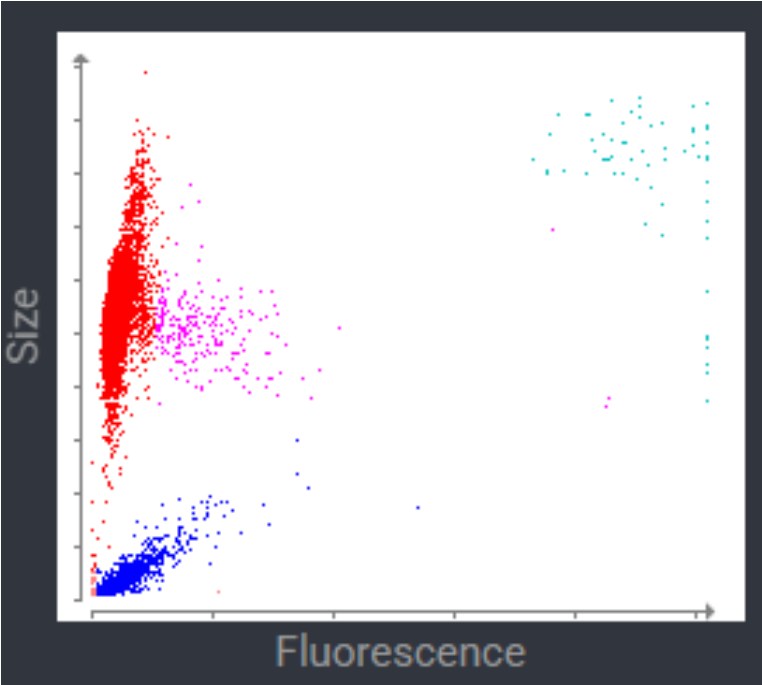
Haematology		31/10/2025 11:19	31/10/2025 10:36	
▣ ▾ RBC	a	5.53	5.53	5.65 - 8.87 x10 ¹² /L
▣ ▾ Haematocrit	b	0.33	0.33	0.373 - 0.617 L/L
▣ ▾ Haemoglobin			117	131 - 205 g/L
▣ ▾ MCV			59.7	61.6 - 73.5 fL
▣ ▾ MCH			21.2	21.2 - 25.9 pg
▣ ▾ MCHC			355	320 - 379 g/L
▣ ▾ RDW			15.4	13.6 - 21.7 %
▣ % Reticulocytes		1.1	1.1	%
▣ ▾ Reticulocytes	c	58.6	58.6	10.0 - 110.0 K/μL
▣ ▾ Reticulocyte Haemoglobin			20.2	22.3 - 29.6 pg

Milo, 3 months old, male entire, beagle

Haematology		31/10/2025 11:19	31/10/2025 10:36	
▣ ▾ RBC	a	5.53	5.53	5.65 - 8.87 x10 ¹² /L
▣ ▾ Haematocrit	b	0.33	0.33	0.373 - 0.617 L/L
▣ ▾ Haemoglobin			117	131 - 205 g/L
▣ ▾ MCV			59.7	61.6 - 73.5 fL
▣ ▾ MCH			21.2	21.2 - 25.9 pg
▣ ▾ MCHC			355	320 - 379 g/L
▣ ▾ RDW			15.4	13.6 - 21.7 %
▣ % Reticulocytes		1.1	1.1	%
▣ ▾ Reticulocytes	c	58.6	58.6	10.0 - 110.0 K/ μ L
▣ ▾ Reticulocyte Haemoglobin			20.2	22.3 - 29.6 pg



Milo, 3 months old, male entire, beagle

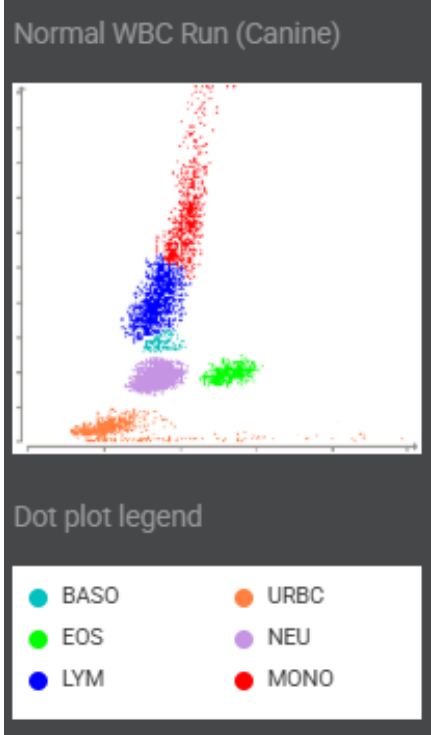
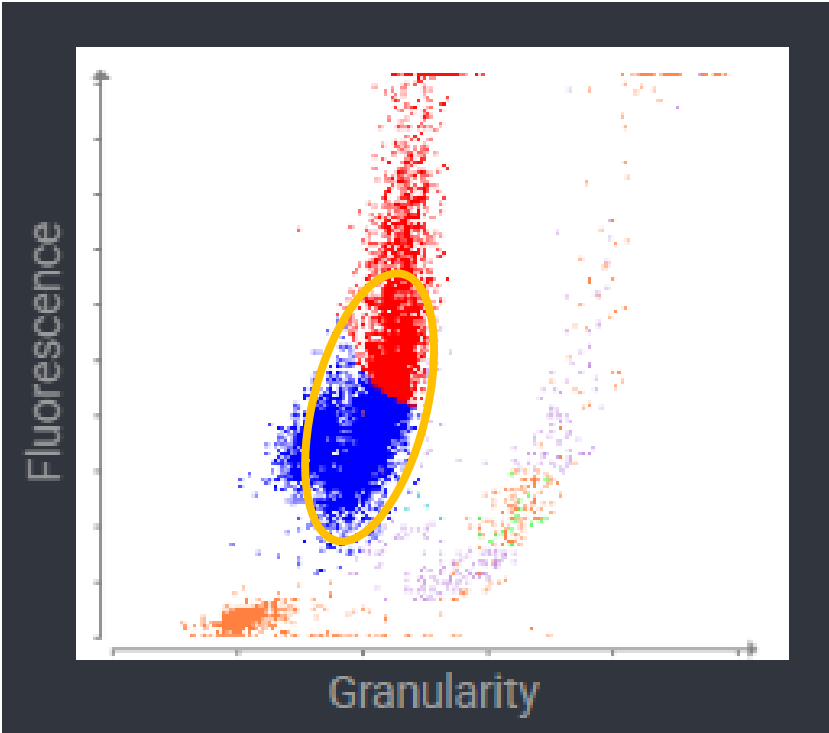


Milo, 3 months old, male entire, beagle

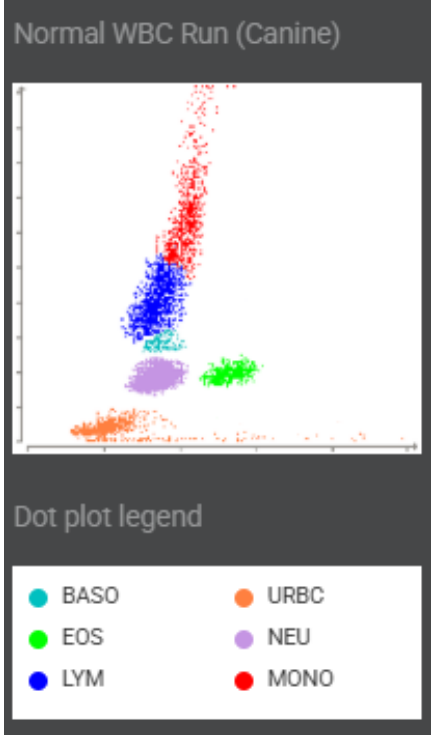
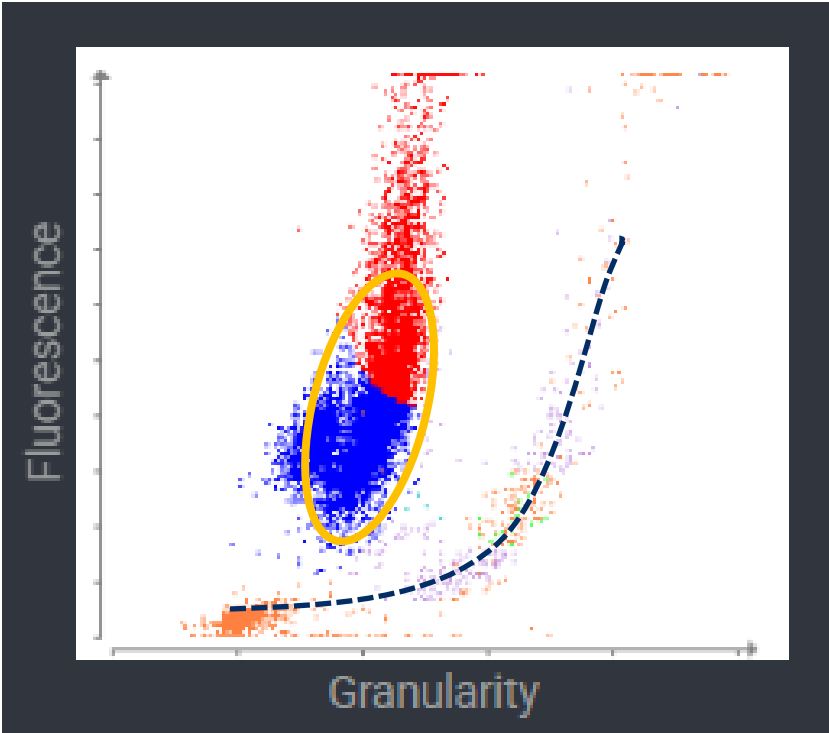


WBC	d	11.16	*11.16	5.05 - 16.76 x10 ⁹ /L	
% Neutrophils		70.8	*2.3	%	
% Immature Neutrophils		4.2			
% Lymphocytes		15.0	*63.4	%	
% Monocytes		9.1	*34.1	%	
% Eosinophils		0.9	*0.2	%	
% Basophils		0.1	*0.0	%	
Neutrophils		7.90	*0.26	2.95 - 11.64 x10 ⁹ /L	
Bands			*Suspected		
Immature Neutrophils		0.46			
Lymphocytes		1.67	*7.08	1.05 - 5.10 x10 ⁹ /L	
Monocytes		1.01	*3.80	0.16 - 1.12 x10 ⁹ /L	
Eosinophils		0.11	*0.02	0.06 - 1.23 x10 ⁹ /L	
Basophils		0.01	*0.00	0.00 - 0.10 x10 ⁹ /L	
Platelets			*250	148 - 484 x10 ⁹ /L	
Platelet Estimate		>150 x10 ⁹ /L (Adequate)			
PDW			*16.9	9.1 - 19.4 fL	
MPV			*14.1	8.7 - 13.2 fL	
Plateletcrit			*0.35	0.14 - 0.46 %	

Milo, 3 months old, male entire, beagle



Milo, 3 months old, male entire, beagle



Milo, 3 months old, male entire, beagle



Haematology		31/10/2025 11:19	31/10/2025 10:36	
RBC	a	5.53	5.53	5.65 - 8.87 x10 ¹² /L
Haematocrit	b	0.33	0.33	0.373 - 0.617 L/L
Haemoglobin			117	131 - 205 g/L
MCV			59.7	61.6 - 73.5 fL
MCH			21.2	21.2 - 25.9 pg
MCHC			355	320 - 379 g/L
RDW			15.4	13.6 - 21.7 %
% Reticulocytes		1.1	1.1	%
Reticulocytes	c	58.6	58.6	10.0 - 110.0 K/ μ L
Reticulocyte Haemoglobin			20.2	22.3 - 29.6 pg

Milo, 3 months old, male entire, beagle



Haematology		31/10/2025 11:19	31/10/2025 10:36	
RBC	a	5.53	5.53	5.65 - 8.87 x10 ¹² /L
Haematocrit	b	0.33	0.33	0.373 - 0.617 L/L
Haemoglobin			117	131 - 205 g/L
MCV			59.7	61.6 - 73.5 fL
MCH			21.2	21.2 - 25.9 pg
MCHC			355	320 - 379 g/L
RDW			15.4	13.6 - 21.7 %
% Reticulocytes		1.1	1.1	%
Reticulocytes	c	58.6	58.6	10.0 - 110.0 K/ μ L
Reticulocyte Haemoglobin			20.2	22.3 - 29.6 pg

- a. Results imported from ProCyte.
- b. Results imported from ProCyte.
- c. Results imported from ProCyte.

Agglutination and spherocytes were not detected.

Milo, 3 months old, male entire, beagle

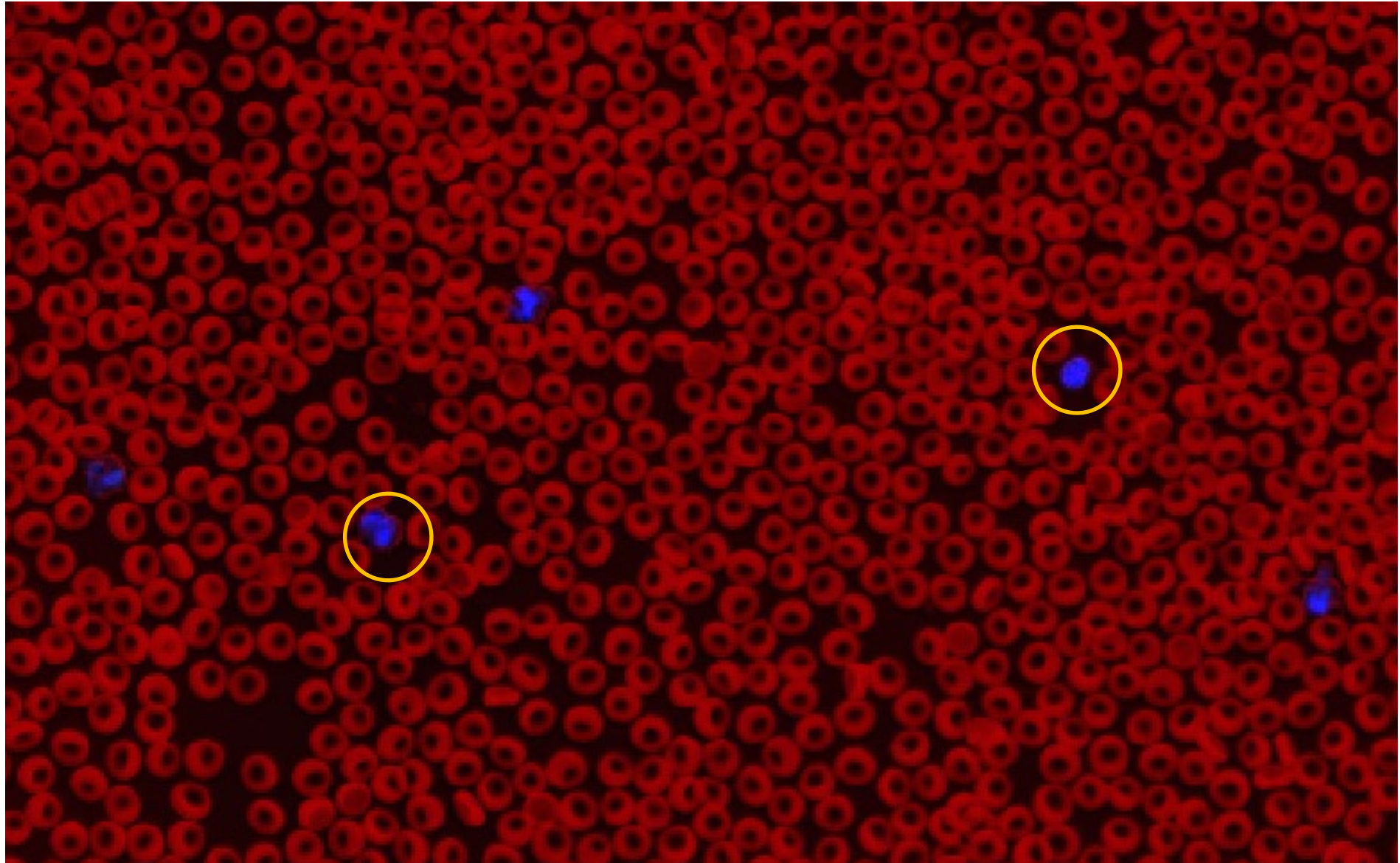



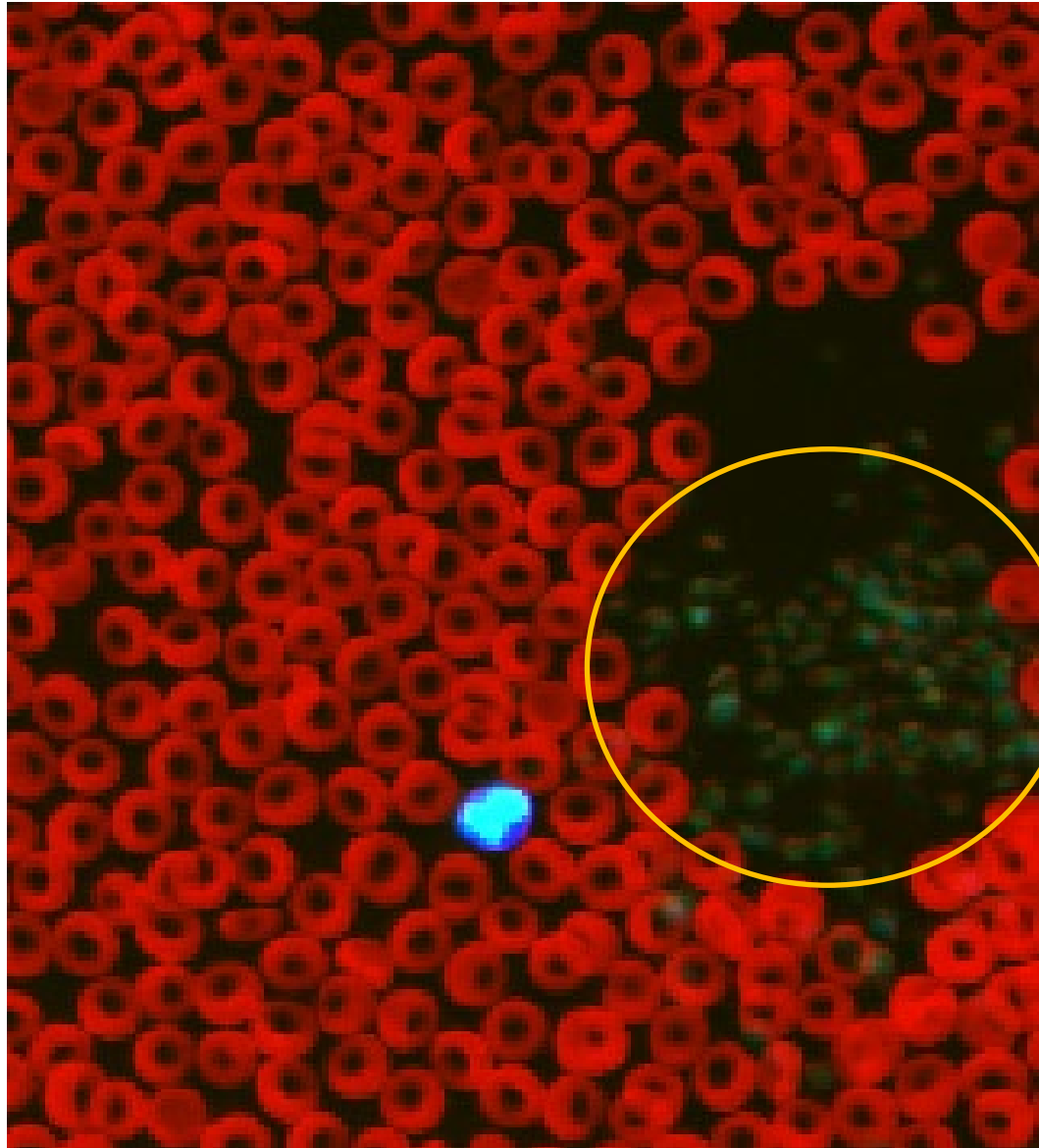
WBC	d 11.16	*11.16	5.05 - 16.76 x10 ⁹ /L	
% Neutrophils	70.8	*2.3	%	
% Immature Neutrophils	4.2			
% Lymphocytes	15.0	*63.4	%	
% Monocytes	9.1	*34.1	%	
% Eosinophils	0.9	*0.2	%	
% Basophils	0.1	*0.0	%	
Neutrophils	7.90	*0.26	2.95 - 11.64 x10 ⁹ /L	
Bands		*Suspected		
Immature Neutrophils	0.46			
Lymphocytes	1.67	*7.08	1.05 - 5.10 x10 ⁹ /L	
Monocytes	1.01	*3.80	0.16 - 1.12 x10 ⁹ /L	
Eosinophils	0.11	*0.02	0.06 - 1.23 x10 ⁹ /L	
Basophils	0.01	*0.00	0.00 - 0.10 x10 ⁹ /L	
Platelets		*250	148 - 484 x10 ⁹ /L	
Platelet Estimate	>150 x10 ⁹ /L (Adequate)			
PDW		*16.9	9.1 - 19.4 fL	
MPV		*14.1	8.7 - 13.2 fL	
Plateletcrit		*0.35	0.14 - 0.46 %	

Milo, 3 months old, male entire, beagle



WBC	d 11.16	*11.16	5.05 - 16.76 x10 ⁹ /L	
% Neutrophils	70.8	*2.3	%	
% Immature Neutrophils	4.2			
% Lymphocytes	15.0	*63.4	%	
% Monocytes	9.1	*34.1	%	
% Eosinophils	0.9	*0.2	%	
% Basophils	0.1	*0.0	%	
Neutrophils	7.90	*0.26	2.95 - 11.64 x10 ⁹ /L	
Bands		*Suspected		
Immature Neutrophils	0.46			
Lymphocytes	1.67	*7.08	1.05 - 5.10 x10 ⁹ /L	
Monocytes	1.01	*3.80	0.16 - 1.12 x10 ⁹ /L	
Eosinophils	0.11	*0.02	0.06 - 1.23 x10 ⁹ /L	
Basophils	0.01	*0.00	0.00 - 0.10 x10 ⁹ /L	
Platelets		*250	148 - 484 x10 ⁹ /L	
Platelet Estimate	>150 x10 ⁹ /L (Adequate)			
PDW		*16.9	9.1 - 19.4 fL	
MPV		*14.1	8.7 - 13.2 fL	
Plateletcrit		*0.35	0.14 - 0.46 %	





Milo, 3 months old, male entire, beagle



Milo, 3 months old, male entire, beagle

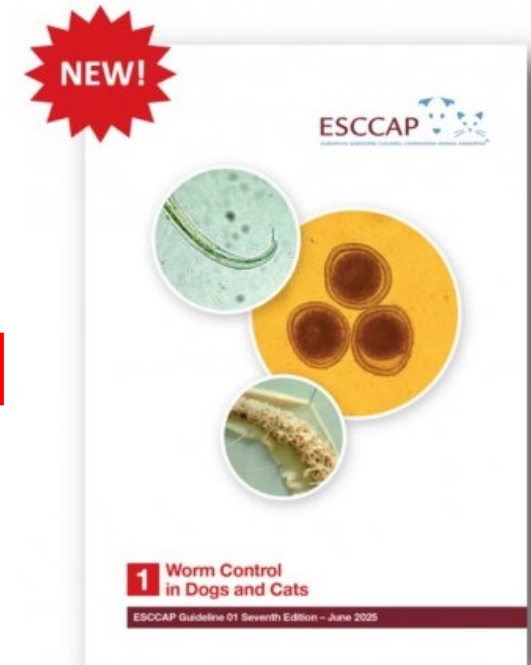FECAL DX® PROFILE

Cystoisospora Antigen ^b	Negative
Flea Tapeworm Antigen	Negative
Hookworm Antigen	Positive
Whipworm Antigen	Negative
Roundworm Antigen	Negative

Milo, 3 months old, male entire, beagle

FECAL DX® PROFILE

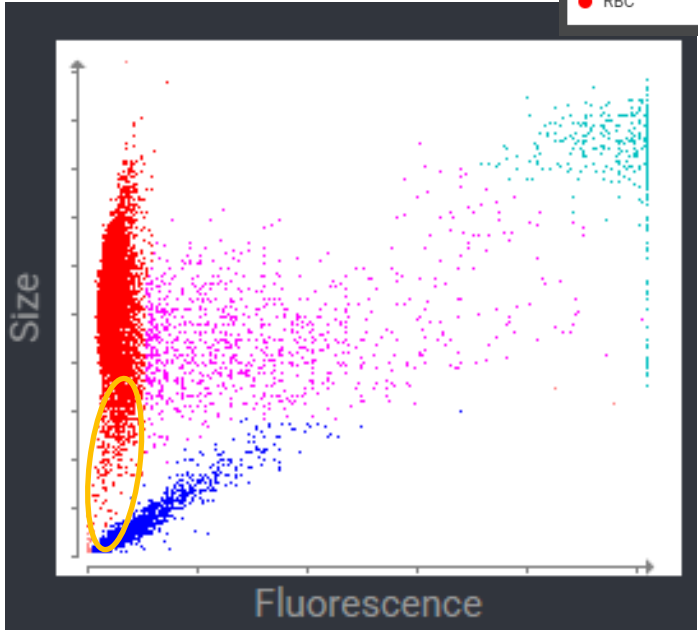
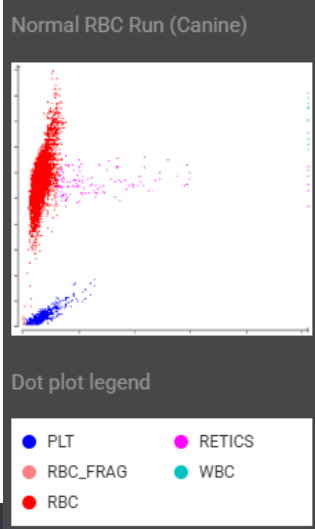
Cystoisospora Antigen ^b	Negative
Flea Tapeworm Antigen	Negative
Hookworm Antigen	Positive
Whipworm Antigen	Negative
Roundworm Antigen	Negative



Jimmy, 2 year-old, male neutered, mixed breed

Hematology		3/22/25 6:33 PM	3/22/25 6:24 PM	
RBC	3.59	3.59	5.65 - 8.87 x10 ¹² /L	
Hematocrit	0.264	0.264	0.373 - 0.617 L/L	
Hemoglobin	76	76	131 - 205 g/L	
MCV		73.5	61.6 - 73.5 fL	
MCH		21.2	21.2 - 25.9 pg	
MCHC	288	288	320 - 379 g/L	
RDW		21.0	13.6 - 21.7 %	
Spherocytes	25.90% (Moderate)			
RBC Agglutination	Present			
% Reticulocytes	4.8	4.8	%	
Reticulocytes	172.3	172.3	10.0 - 110.0 K/ μ L	
Reticulocyte Hemoglobin	17.1	17.1	22.3 - 29.6 pg	

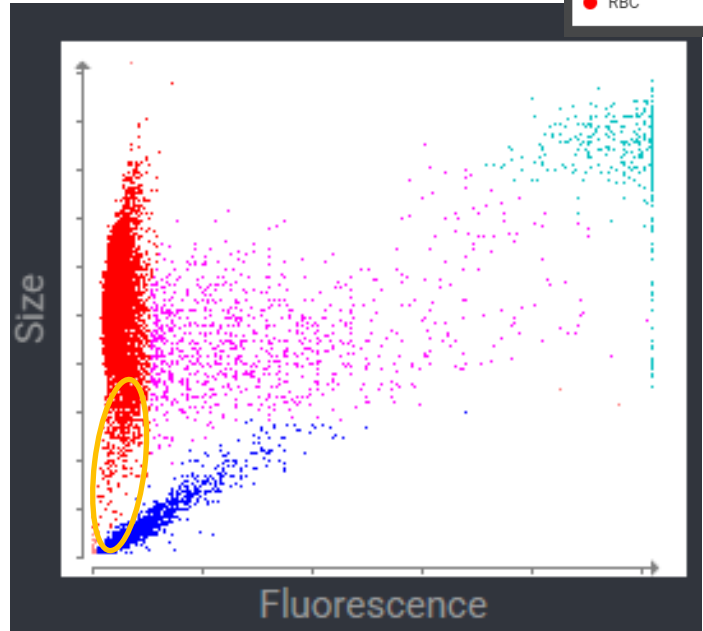
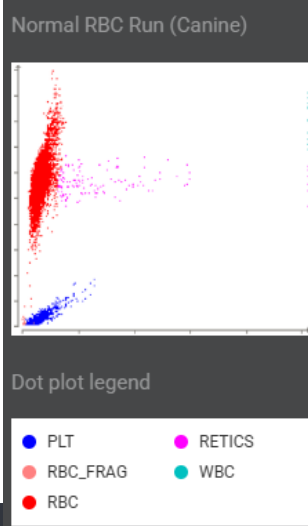
a. Results imported from ProCyte.



Jimmy, 2 year-old, male neutered, mixed breed

Hematology		3/22/25 6:33 PM	3/22/25 6:24 PM	
RBC	3.59	3.59	5.65 - 8.87 x10 ¹² /L	
Hematocrit	0.264	0.264	0.373 - 0.617 L/L	
Hemoglobin		76	131 - 205 g/L	
MCV		73.5	61.6 - 73.5 fL	
MCH		21.2	21.2 - 25.9 pg	
MCHC		288	320 - 379 g/L	
RDW		21.0	13.6 - 21.7 %	
Spherocytes	25.90% (Moderate)			
RBC Agglutination	Present			
% Reticulocytes	4.8	4.8	%	
Reticulocytes	172.3	172.3	10.0 - 110.0 K/ μ L	
Reticulocyte Hemoglobin		17.1	22.3 - 29.6 pg	

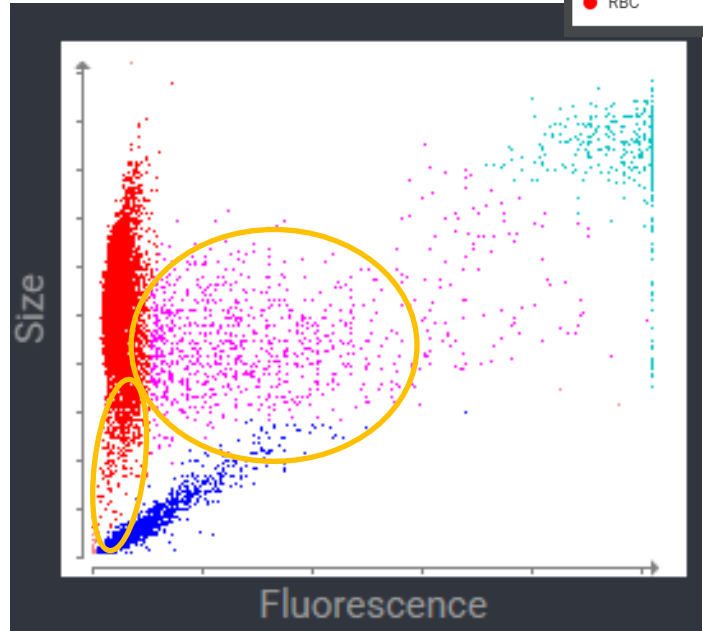
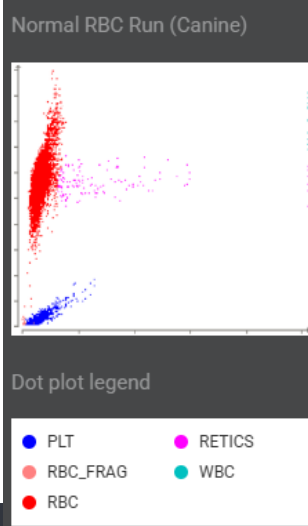
a. Results imported from ProCyte.



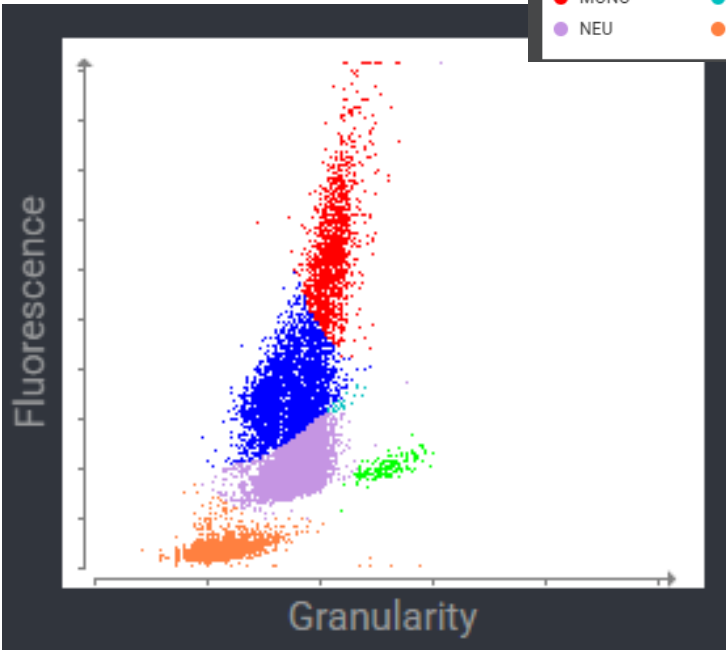
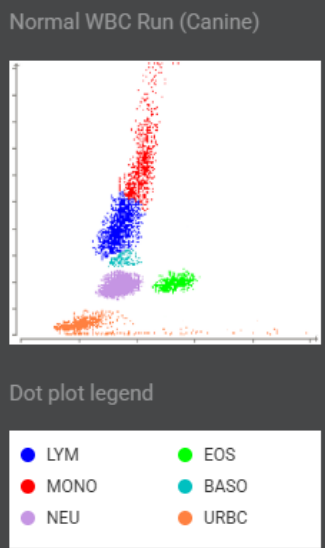
Jimmy, 2 year-old, male neutered, mixed breed

Hematology		3/22/25 6:33 PM	3/22/25 6:24 PM	
RBC	3.59	3.59	5.65 - 8.87 x10 ¹² /L	
Hematocrit	0.264	0.264	0.373 - 0.617 L/L	
Hemoglobin	76	76	131 - 205 g/L	
MCV		73.5	61.6 - 73.5 fL	
MCH		21.2	21.2 - 25.9 pg	
MCHC		288	320 - 379 g/L	
RDW		21.0	13.6 - 21.7 %	
Spherocytes	25.90% (Moderate)			
RBC Agglutination	Present			
% Reticulocytes	4.8	4.8	%	
Reticulocytes	172.3	172.3	10.0 - 110.0 K/ μ L	
Reticulocyte Hemoglobin		17.1	22.3 - 29.6 pg	

a. Results imported from ProCyte.



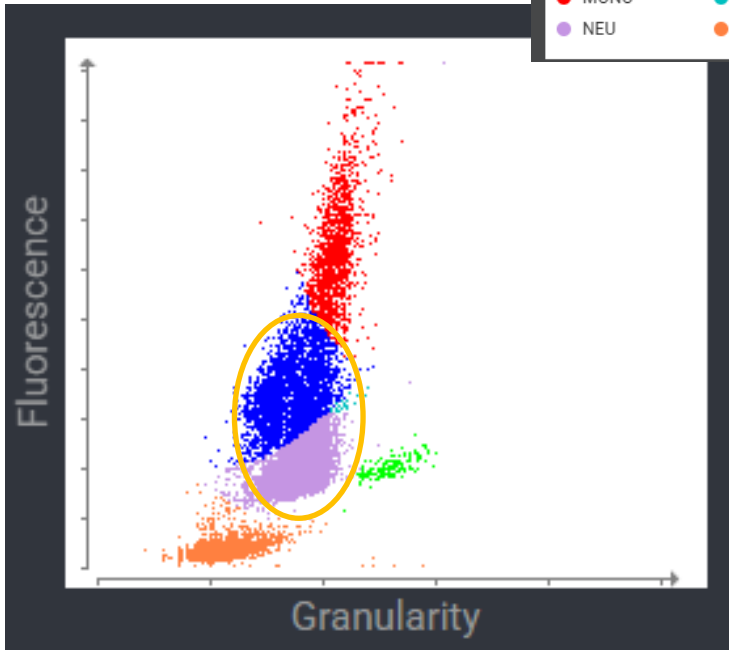
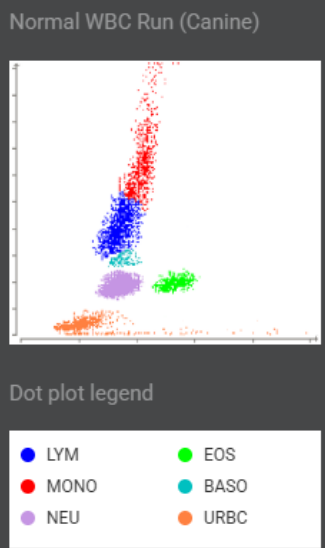
Jimmy, 2 year-old, male neutered, mixed breed



Hematology		3/22/25 6:33 PM	3/22/25 6:24 PM	
WBC	b	52.53	52.53	5.05 - 16.76 x10 ⁹ /L
% Neutrophils		86.4	76.6	%
% Lymphocytes		6.5	16.4	%
% Monocytes		6.6	6.3	%
% Eosinophils		0.5	0.6	%
% Basophils		0.0	0.1	%
Neutrophils		45.38	40.19	2.95 - 11.64 x10 ⁹ /L
Lymphocytes		3.42	8.64	1.05 - 5.10 x10 ⁹ /L
Monocytes		3.47	3.33	0.16 - 1.12 x10 ⁹ /L
Eosinophils		0.26	0.32	0.06 - 1.23 x10 ⁹ /L
Basophils		0.00	0.05	0.00 - 0.10 x10 ⁹ /L
Platelets			+189	148 - 484 x10 ⁹ /L
Platelet Estimate		>150 x10 ⁹ /L (Adequate)		

b. WBC results imported from ProCyte. The white blood cell differential has been updated based on cellular analysis.

Jimmy, 2 year-old, male neutered, mixed breed



Hematology		3/22/25 6:33 PM	3/22/25 6:24 PM	
WBC	b	52.53	52.53	5.05 - 16.76 x10 ⁹ /L
% Neutrophils		86.4	76.6	%
% Lymphocytes		6.5	16.4	%
% Monocytes		6.6	6.3	%
% Eosinophils		0.5	0.6	%
% Basophils		0.0	0.1	%
Neutrophils		45.38	40.19	2.95 - 11.64 x10 ⁹ /L
Lymphocytes		3.42	8.64	1.05 - 5.10 x10 ⁹ /L
Monocytes		3.47	3.33	0.16 - 1.12 x10 ⁹ /L
Eosinophils		0.26	0.32	0.06 - 1.23 x10 ⁹ /L
Basophils		0.00	0.05	0.00 - 0.10 x10 ⁹ /L
Platelets			+189	148 - 484 x10 ⁹ /L
Platelet Estimate		>150 x10 ⁹ /L (Adequate)		

b. WBC results imported from ProCyte. The white blood cell differential has been updated based on cellular analysis.

Jimmy, 2 year-old, male neutered, mixed breed



Hematology		3/22/25 6:33 PM	3/22/25 6:24 PM		
RBC	a	3.59	3.59	5.65 - 8.87 x10 ¹² /L	
Hematocrit	a	0.264	0.264	0.373 - 0.617 L/L	
Hemoglobin			76	131 - 205 g/L	
MCV			73.5	61.6 - 73.5 fL	
MCH			21.2	21.2 - 25.9 pg	
MCHC			288	320 - 379 g/L	
RDW			21.0	13.6 - 21.7 %	
Spherocytes		25.90% (Moderate)			
RBC Agglutination		Present			
% Reticulocytes		4.8	4.8	%	
Reticulocytes		172.3	172.3	10.0 - 110.0 K/ μ L	
Reticulocyte Hemoglobin			17.1	22.3 - 29.6 pg	


a. Results imported from ProCyte.

Jimmy, 2 year-old, male neutered, mixed breed



Hematology		3/22/25 6:33 PM	3/22/25 6:24 PM	
WBC	b	52.53	52.53	5.05 - 16.76 x10 ⁹ /L
% Neutrophils		86.4	76.6	%
% Lymphocytes		6.5	16.4	%
% Monocytes		6.6	6.3	%
% Eosinophils		0.5	0.6	%
% Basophils		0.0	0.1	%
Neutrophils		45.38	40.19	2.95 - 11.64 x10 ⁹ /L
Lymphocytes		3.42	8.64	1.05 - 5.10 x10 ⁹ /L
Monocytes		3.47	3.33	0.16 - 1.12 x10 ⁹ /L
Eosinophils		0.26	0.32	0.06 - 1.23 x10 ⁹ /L
Basophils		0.00	0.05	0.00 - 0.10 x10 ⁹ /L
Platelets			+189	148 - 484 x10 ⁹ /L
Platelet Estimate	>150 x10 ⁹ /L (Adequate)			

b. WBC results imported from ProCyte. The white blood cell differential has been updated based on cellular analysis.



ACVIM Consensus Statement on the diagnosis of immune-mediated hemolytic anemia in dogs and cats – JVIM 2018



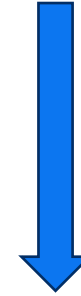≥ 2 signs of immuno-mediated destruction:

Spherocytosis (dog)

Saline Agglutination test

Coombs Test or Flow Cytometry

(Se 82%, Sp 95-100%; Se 67-87%, Sp 100%)



≥ 1 sign of haemolysis:

hyperbilirubinaemia
(r/o hepatic disease, sepsis, cholestasis)

haemoglobinaemia

haemoglobinuria

Ghost cells



Effect of dilution of canine blood samples on the specificity of saline agglutination test for immune-mediated hemolysis – JVIM 2020

Saline-to-blood ratio	Sensitivity % (95% CI)	Specificity % (95% CI)	Diagnostic accuracy % (95% CI)
1 : 1	88 (47–100)	29 (20–38)	33 (24–42)
4 : 1	88 (47–100)	49 (40–58)	51 (43–59)
9 : 1	67 (30–93)	70 (62–78)	70 (62–77)
49 : 1	67 (30–93)	97 (93–99)	95 (90–98)

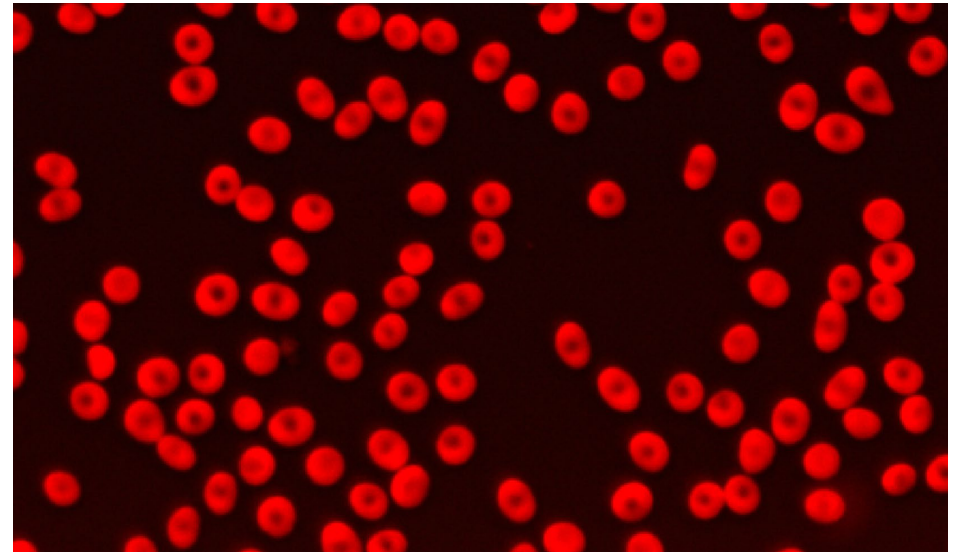
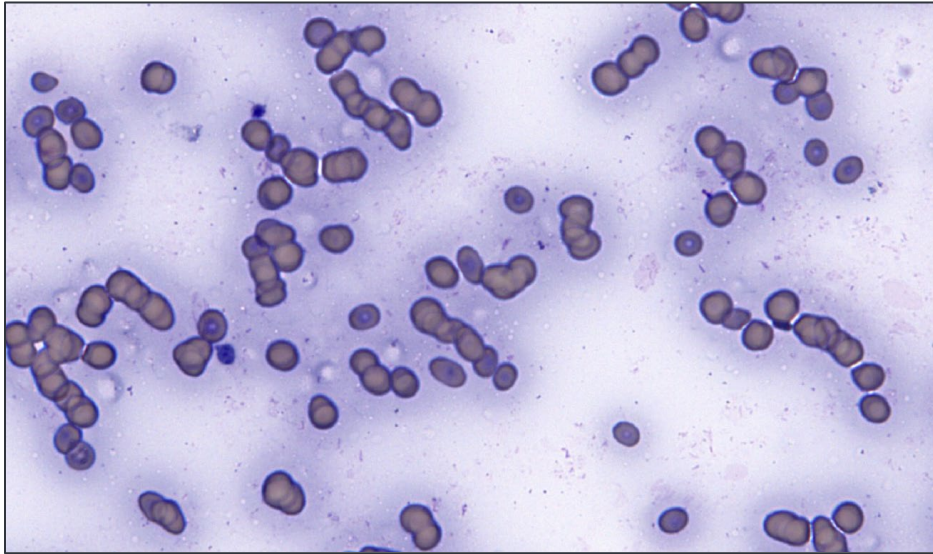


Effect of dilution of canine blood samples on the specificity of saline agglutination test for immune-mediated hemolysis – JVIM 2020

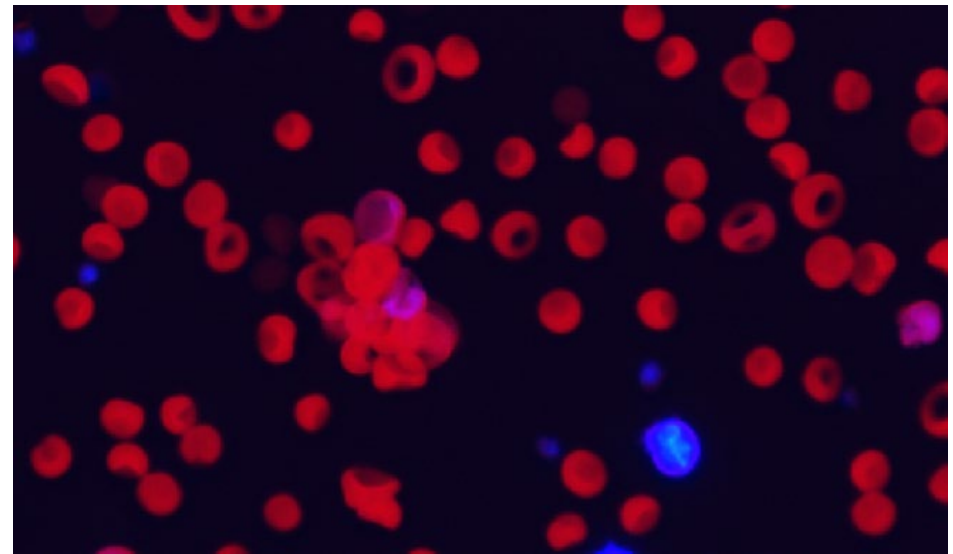
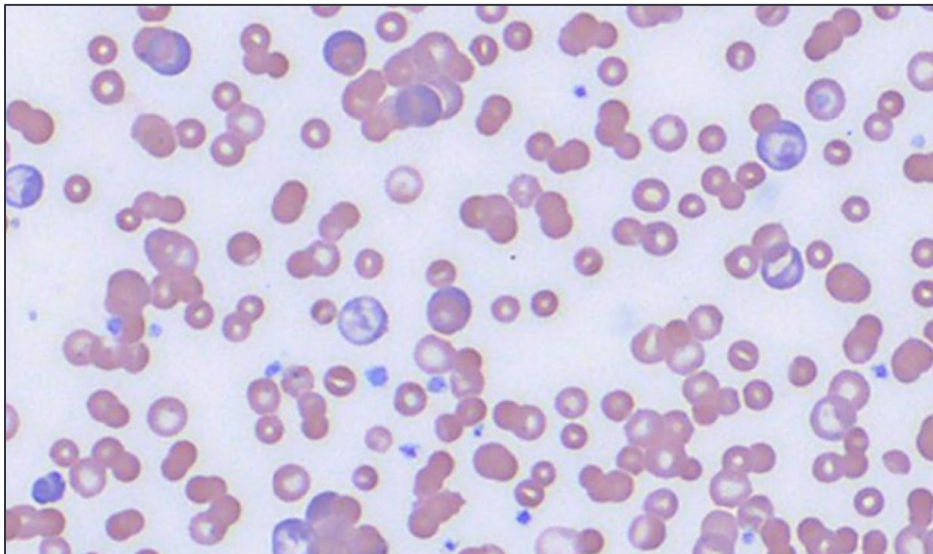
Saline-to-blood ratio	Sensitivity % (95% CI)	Specificity % (95% CI)	Diagnostic accuracy % (95% CI)
1 : 1	88 (47–100)	29 (20–38)	33 (24–42)
4 : 1	88 (47–100)	49 (40–58)	51 (43–59)
9 : 1	67 (30–93)	70 (62–78)	70 (62–77)
49 : 1	67 (30–93)	97 (93–99)	95 (90–98)

inVue Dx™ Helps Differentiate Rouleaux from Agglutination

Rouleaux

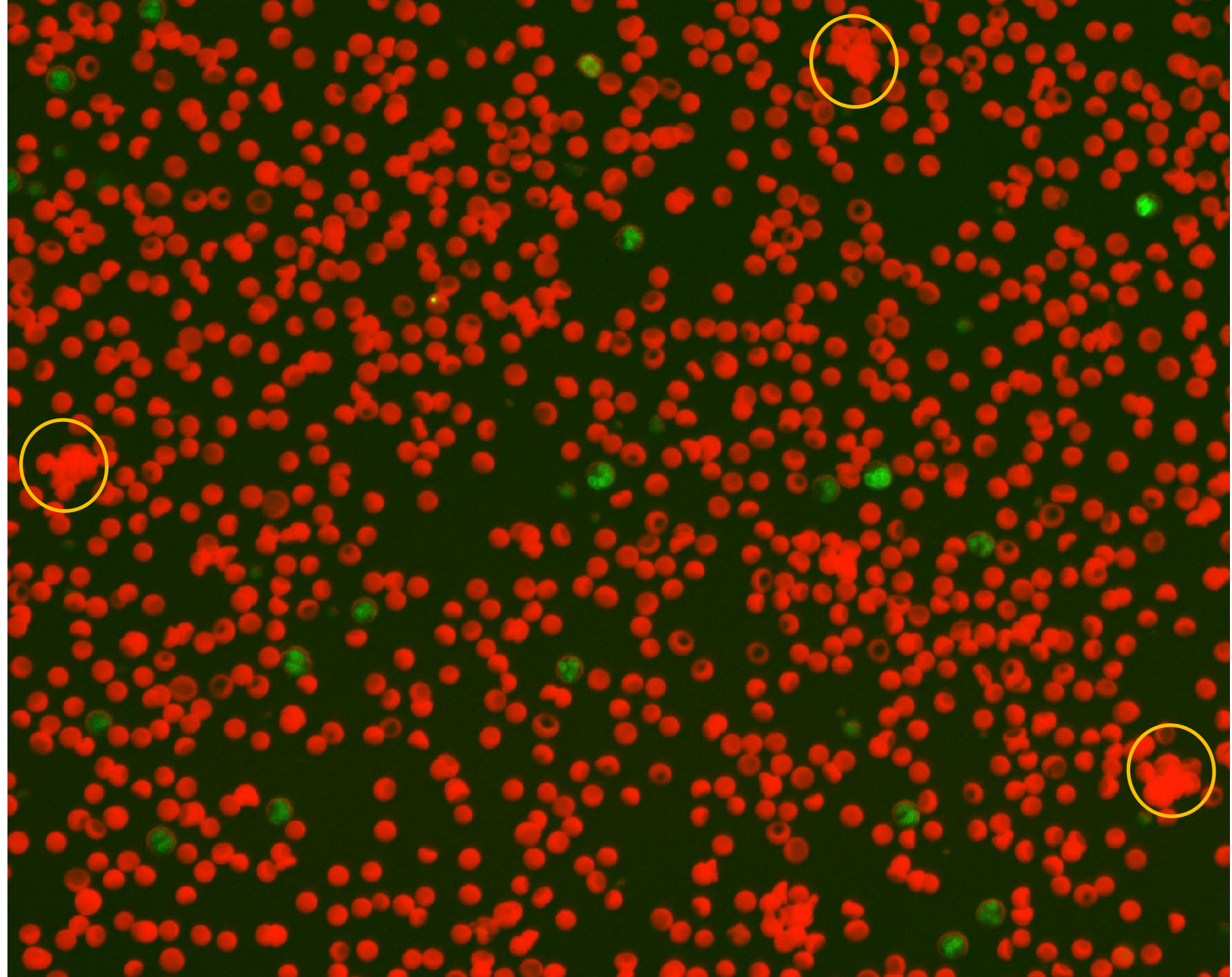


Agglutination



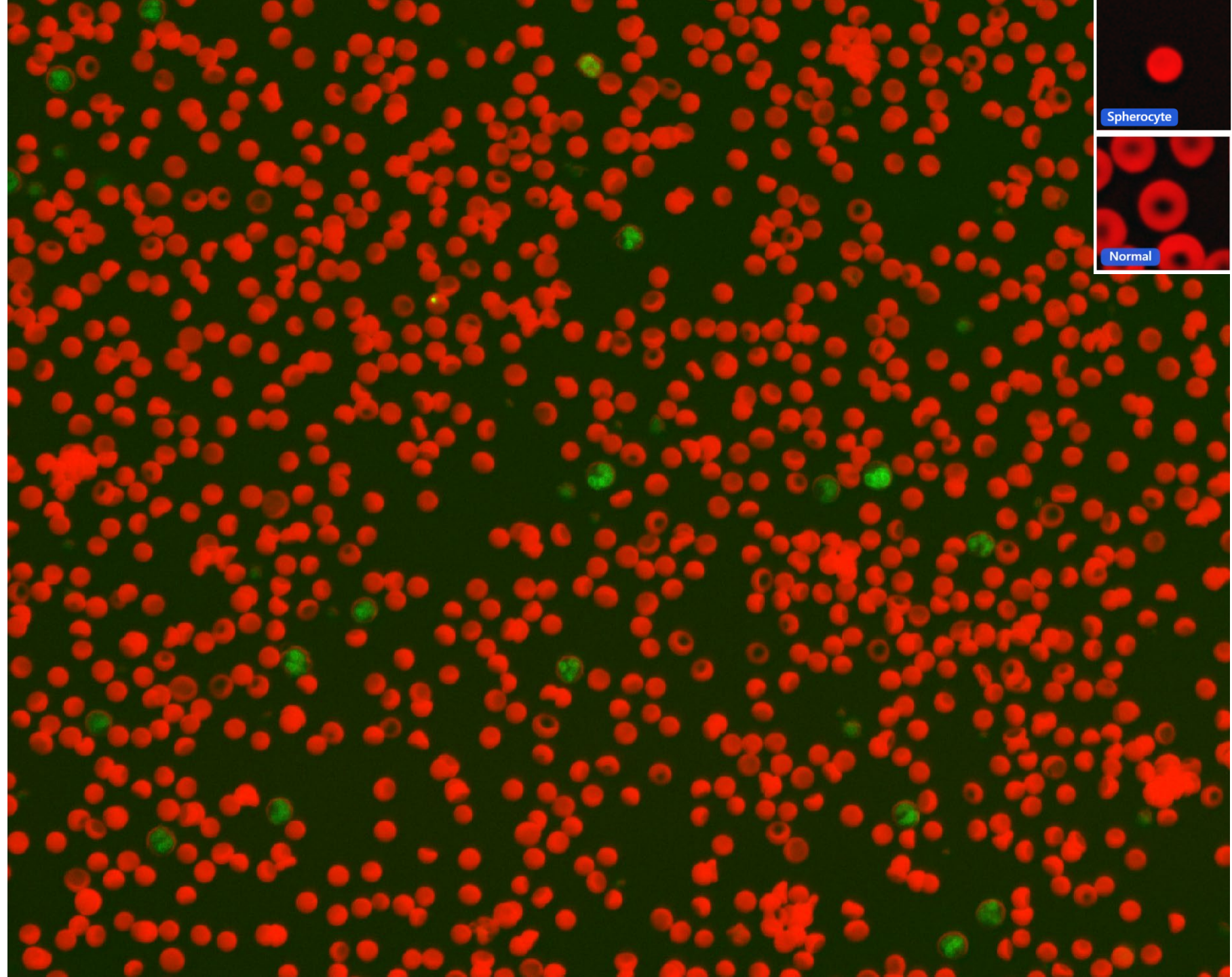


Composite image:
+ Agglutination



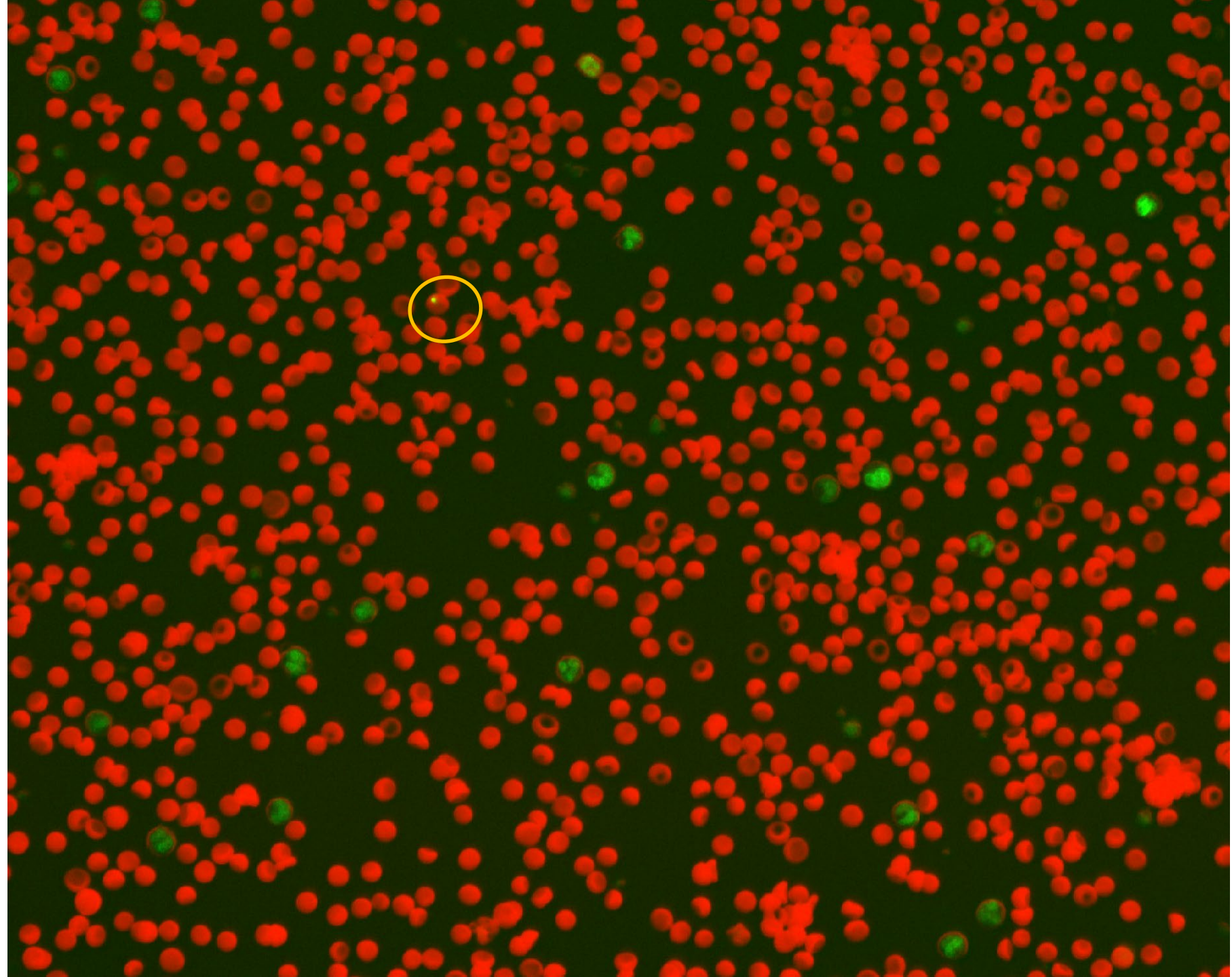
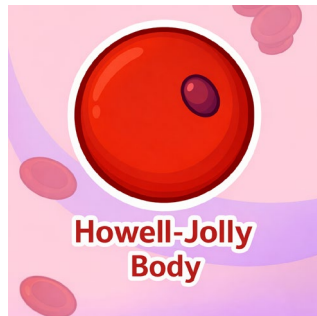

Composite image:
+ Spherocytes





Composite image:
+ HJ body

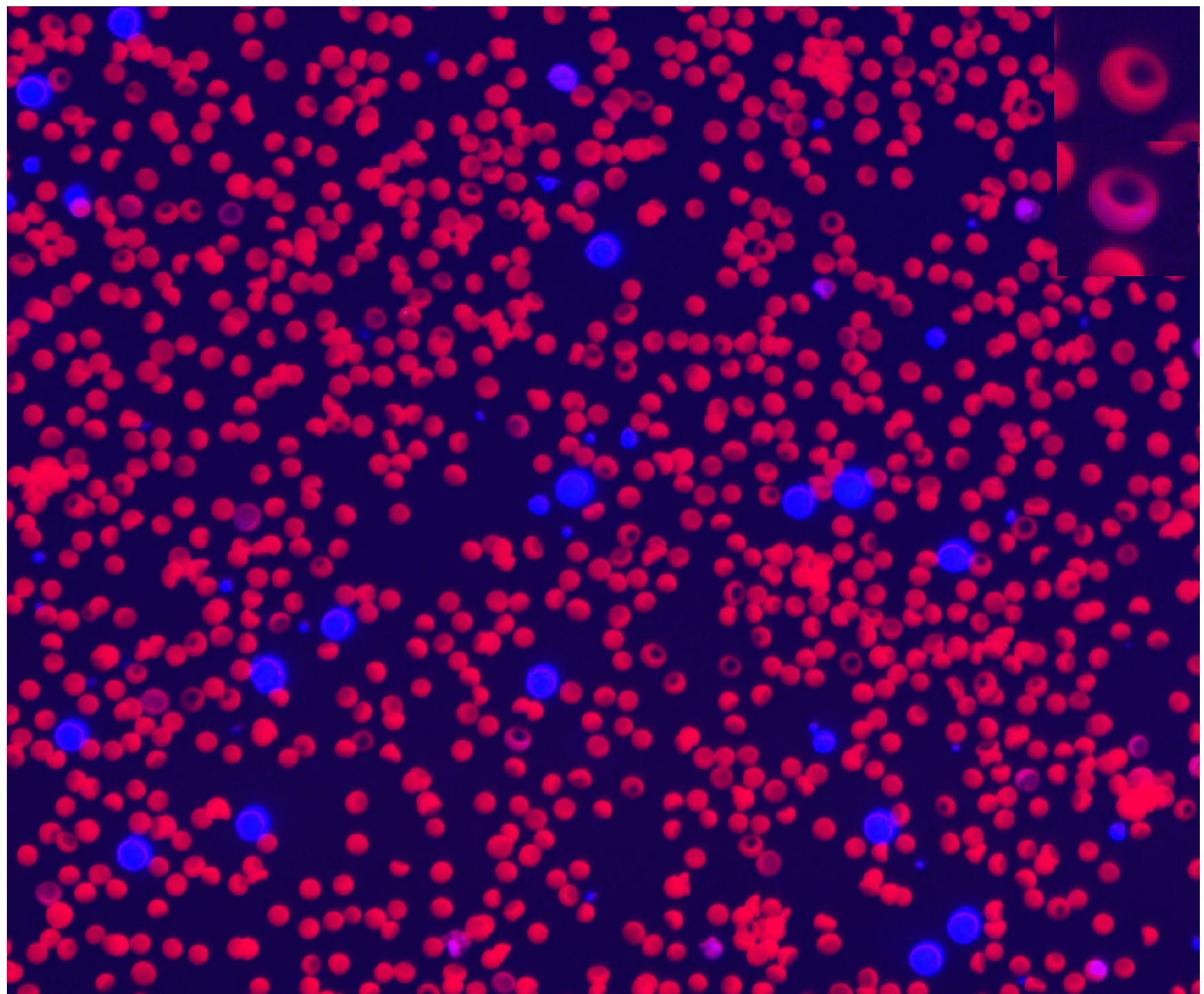




Composite image:

*Enhanced fluorescent signal

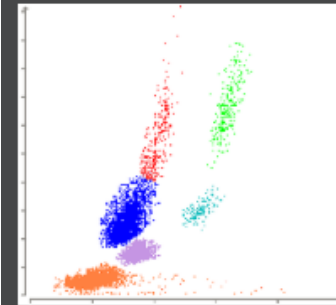
- + Agglutination
- + Spherocytes
- + Polychromasia



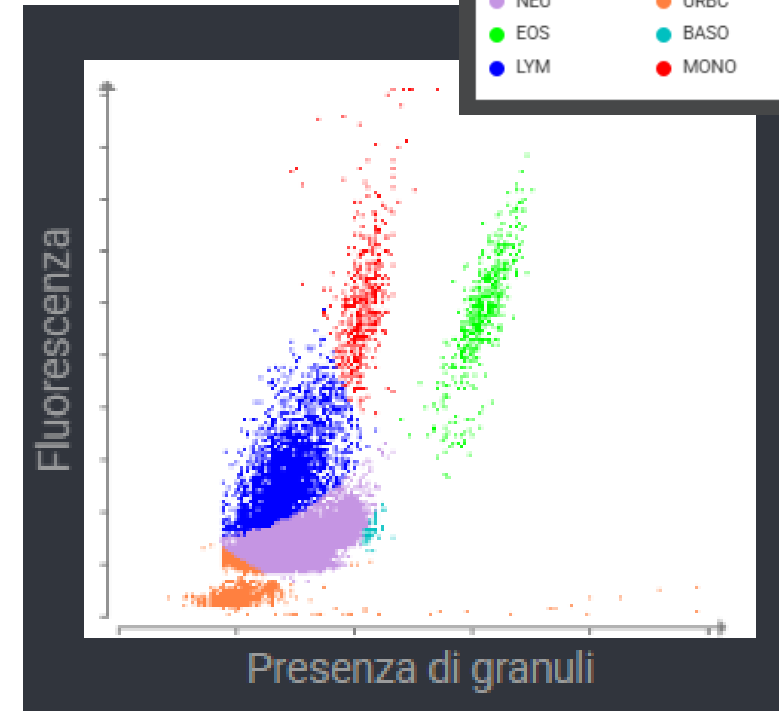
Penny 10 year-old female spayed DSH



Analisi RBC di riferimento (Gatto)



Legenda diagramma a punti



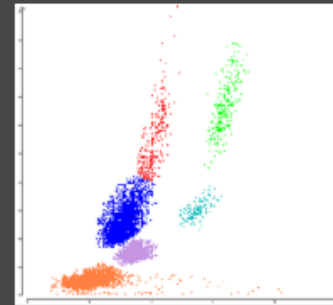
Ematologia		23/12/25 10:11	23/12/25 09:49	
Leucociti	b 11,19	*51,35	2,87 - 17,02 x10 ⁹ /L	
% Neutrofili segmentati	64,3	*83,0	%	
% Linfociti	24,4	*13,3	%	
% Monociti	5,0	*1,7	%	
% Eosinofili	6,2	*1,8	%	
% Basofili	0,0	*0,2	%	
Neutrofili segmentati	7,19	*42,63	2,30 - 10,29 x10 ⁹ /L	
Neutrofili banda		*Suspected		
Linfociti	2,73	*6,85	0,92 - 6,88 x10 ⁹ /L	
Monociti	0,56	*0,86	0,05 - 0,67 x10 ⁹ /L	
Eosinofili	0,70	*0,92	0,17 - 1,57 x10 ⁹ /L	
Basofili	0,00	*0,09	0,01 - 0,26 x10 ⁹ /L	
Eritrociti nucleati		*Suspected		
Piastrine		385	151 - 600 x10 ⁹ /L	
Stima delle piastrine	>150 x10 ⁹ /L (Adequate)			

b. The white blood cell count and differential have been updated based on cellular analysis.

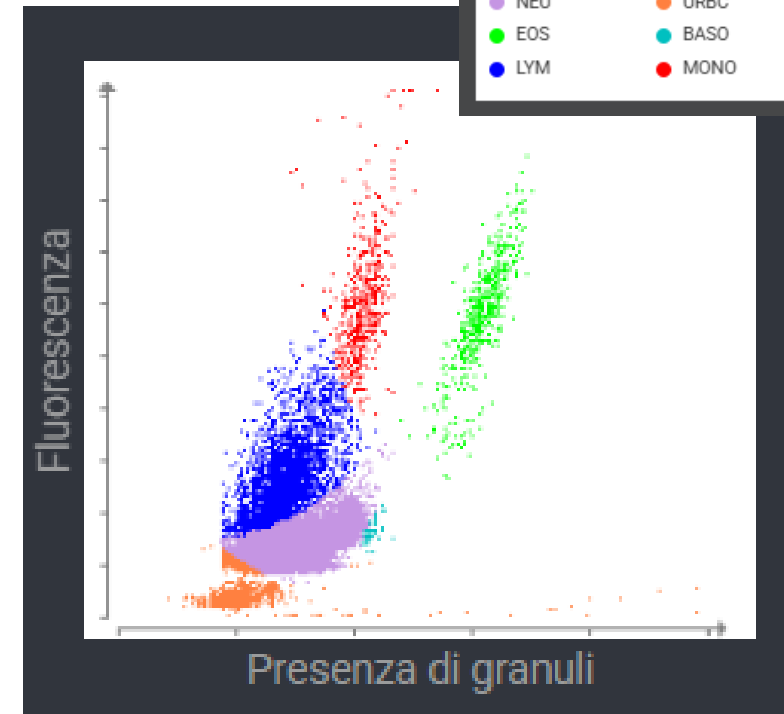
Penny 10 year-old female spayed DSH



Analisi RBC di riferimento (Gatto)



Legenda diagramma a punti



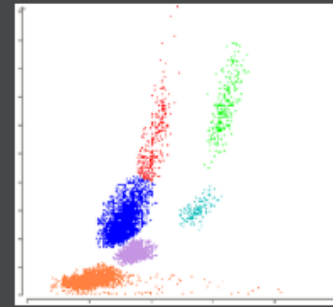
Ematologia		23/12/25 10:11	23/12/25 09:49
Leucociti	b 11,19	*51,35	2,87 - 17,02 x10 ⁹ /L
% Neutrofili segmentati	64,3	*83,0	%
% Linfociti	24,4	*13,3	%
% Monociti	5,0	*1,7	%
% Eosinofili	6,2	*1,8	%
% Basofili	0,0	*0,2	%
Neutrofili segmentati	7,19	*42,63	2,30 - 10,29 x10 ⁹ /L
Neutrofili banda		*Suspected	
Linfociti	2,73	*6,85	0,92 - 6,88 x10 ⁹ /L
Monociti	0,56	*0,86	0,05 - 0,67 x10 ⁹ /L
Eosinofili	0,70	*0,92	0,17 - 1,57 x10 ⁹ /L
Basofili	0,00	*0,09	0,01 - 0,26 x10 ⁹ /L
Eritrociti nucleati		*Suspected	
Piastrine		385	151 - 600 x10 ⁹ /L
Stima delle piastrine	>150 x10 ⁹ /L (Adequate)		

b. The white blood cell count and differential have been updated based on cellular analysis.

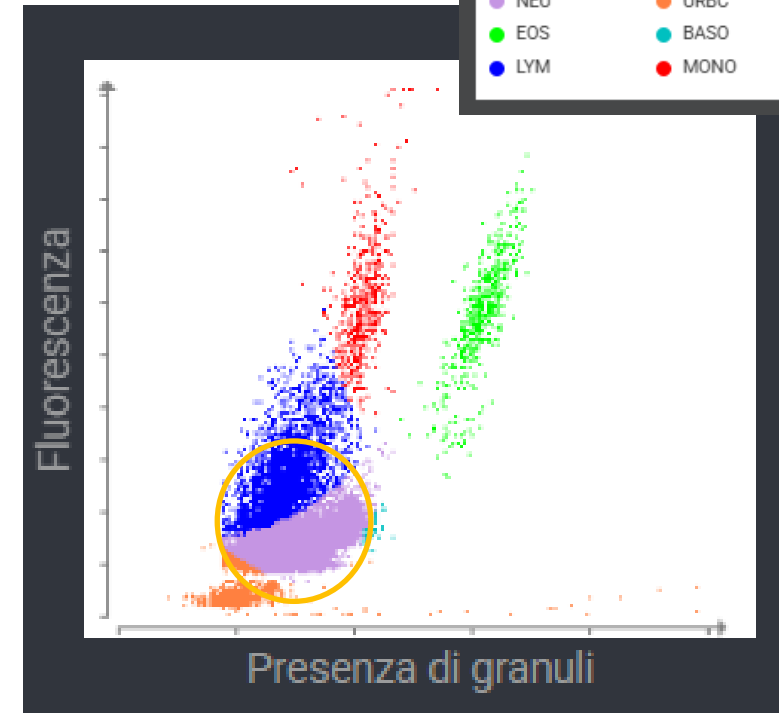
Penny 10 year-old female spayed DSH



Analisi RBC di riferimento (Gatto)



Legenda diagramma a punti



Ematologia		23/12/25 10:11	23/12/25 09:49
Leucociti	b	11,19	*51,35 2,87 - 17,02 x10 ⁹ /L
% Neutrofili segmentati		64,3	*83,0 %
% Linfociti		24,4	*13,3 %
% Monociti		5,0	*1,7 %
% Eosinofili		6,2	*1,8 %
% Basofili		0,0	*0,2 %
Neutrofili segmentati		7,19	*42,63 2,30 - 10,29 x10 ⁹ /L
Neutrofili banda			*Suspected
Linfociti		2,73	*6,85 0,92 - 6,88 x10 ⁹ /L
Monociti		0,56	*0,86 0,05 - 0,67 x10 ⁹ /L
Eosinofili		0,70	*0,92 0,17 - 1,57 x10 ⁹ /L
Basofili		0,00	*0,09 0,01 - 0,26 x10 ⁹ /L
Eritrociti nucleati			*Suspected
Piastrine			385 151 - 600 x10 ⁹ /L
Stima delle piastrine		>150 x10 ⁹ /L (Adequate)	

b. The white blood cell count and differential have been updated based on cellular analysis.

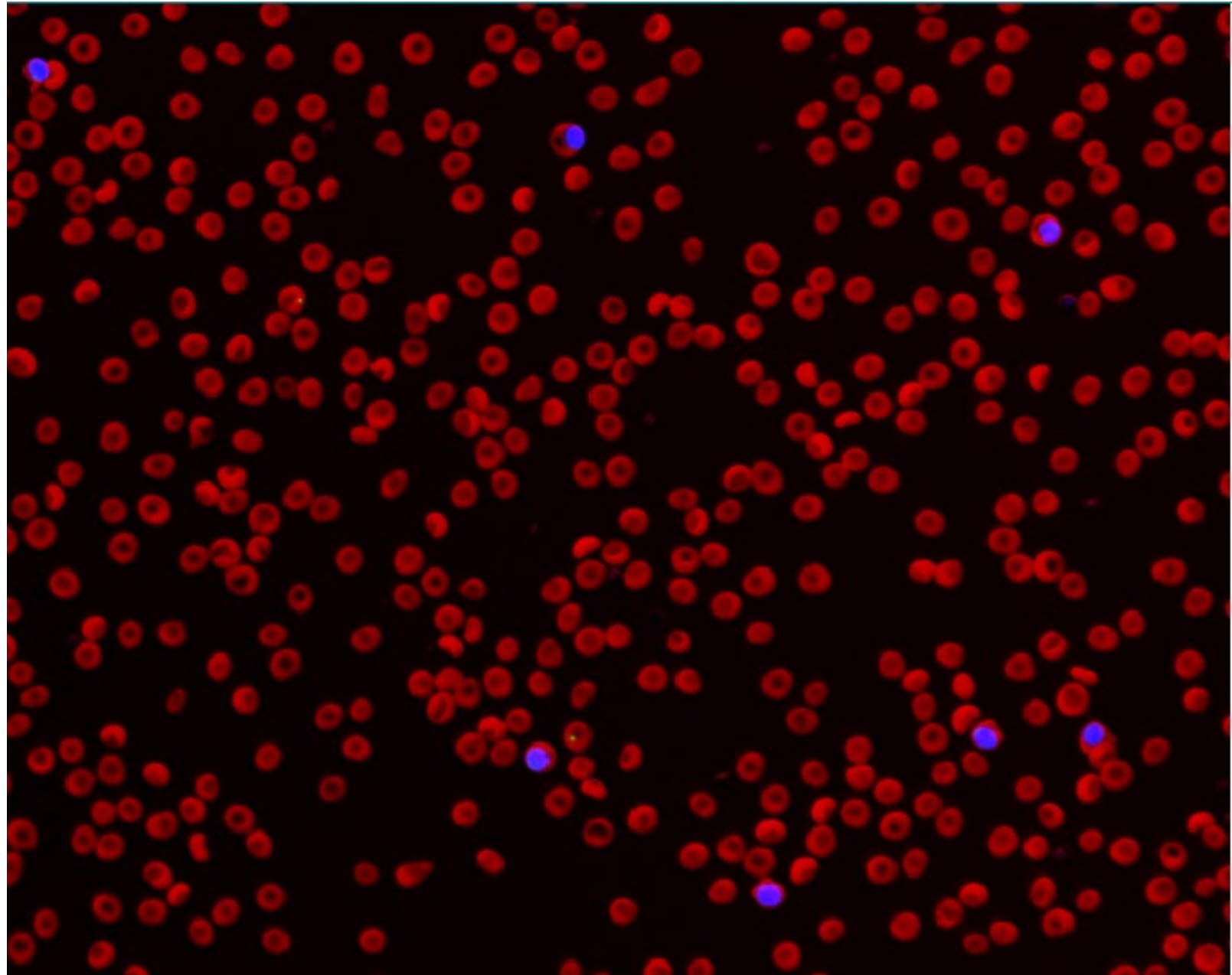
Penny 10 year-old female spayed DSH



Ematologia		23/12/25 10:11	23/12/25 09:49	
Leucociti	11,19	*51,35	2,87 - 17,02 x10 ⁹ /L	
% Neutrofili segmentati	64,3	*83,0	%	
% Linfociti	24,4	*13,3	%	
% Monociti	5,0	*1,7	%	
% Eosinofili	6,2	*1,8	%	
% Basofili	0,0	*0,2	%	
Neutrofili segmentati	7,19	*42,63	2,30 - 10,29 x10 ⁹ /L	
Neutrofili banda		*Suspected		
Linfociti	2,73	*6,85	0,92 - 6,88 x10 ⁹ /L	
Monociti	0,56	*0,86	0,05 - 0,67 x10 ⁹ /L	
Eosinofili	0,70	*0,92	0,17 - 1,57 x10 ⁹ /L	
Basofili	0,00	*0,09	0,01 - 0,26 x10 ⁹ /L	
Eritrociti nucleati		*Suspected		
Piastrine		385	151 - 600 x10 ⁹ /L	
Stima delle piastrine	>150 x10 ⁹ /L (Adequate)			

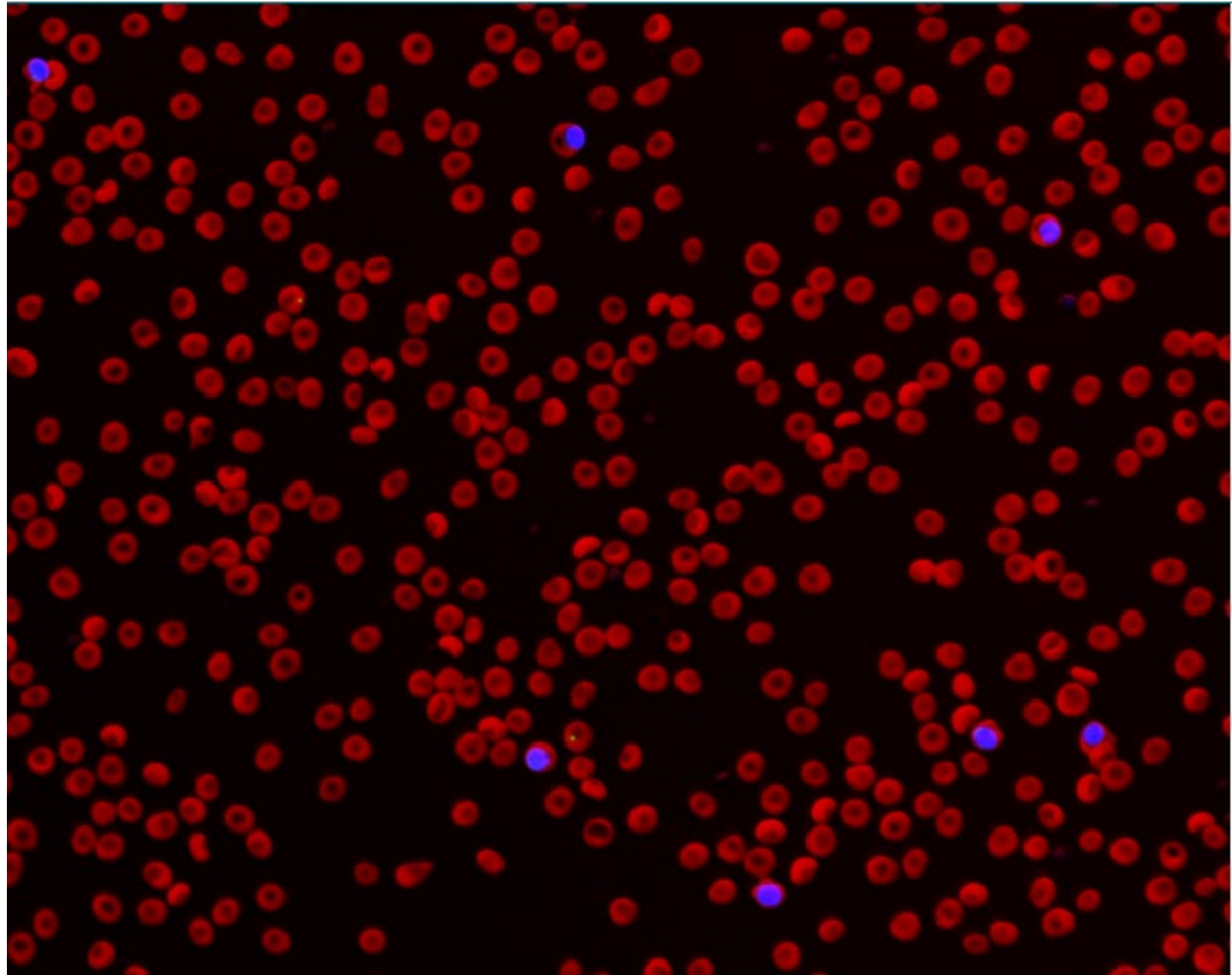
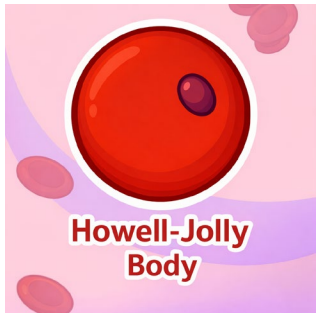

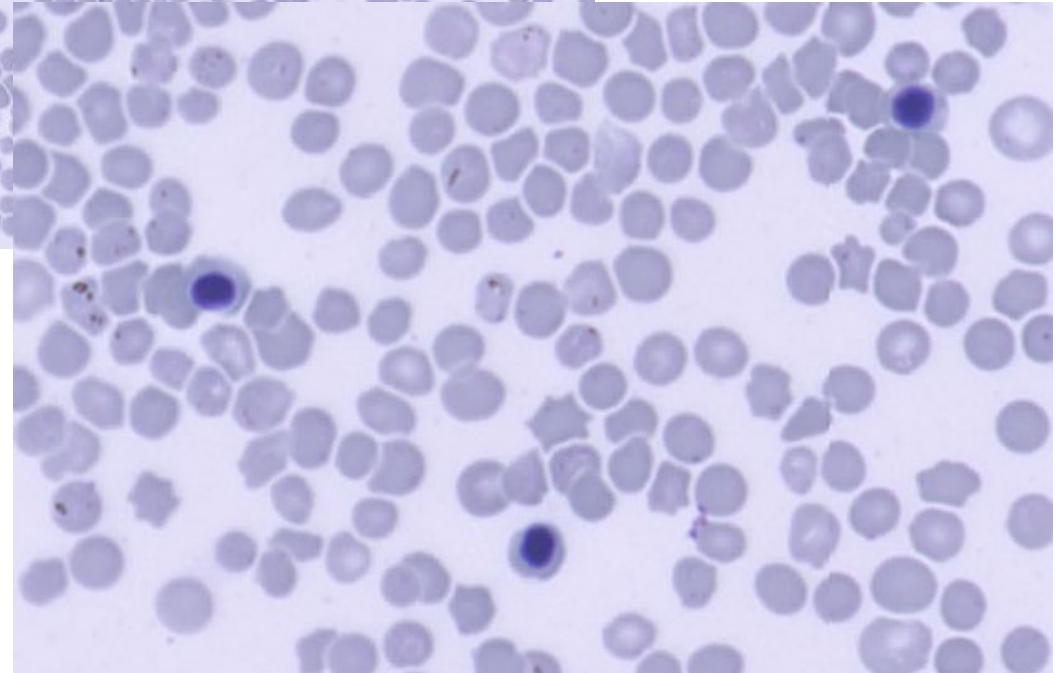
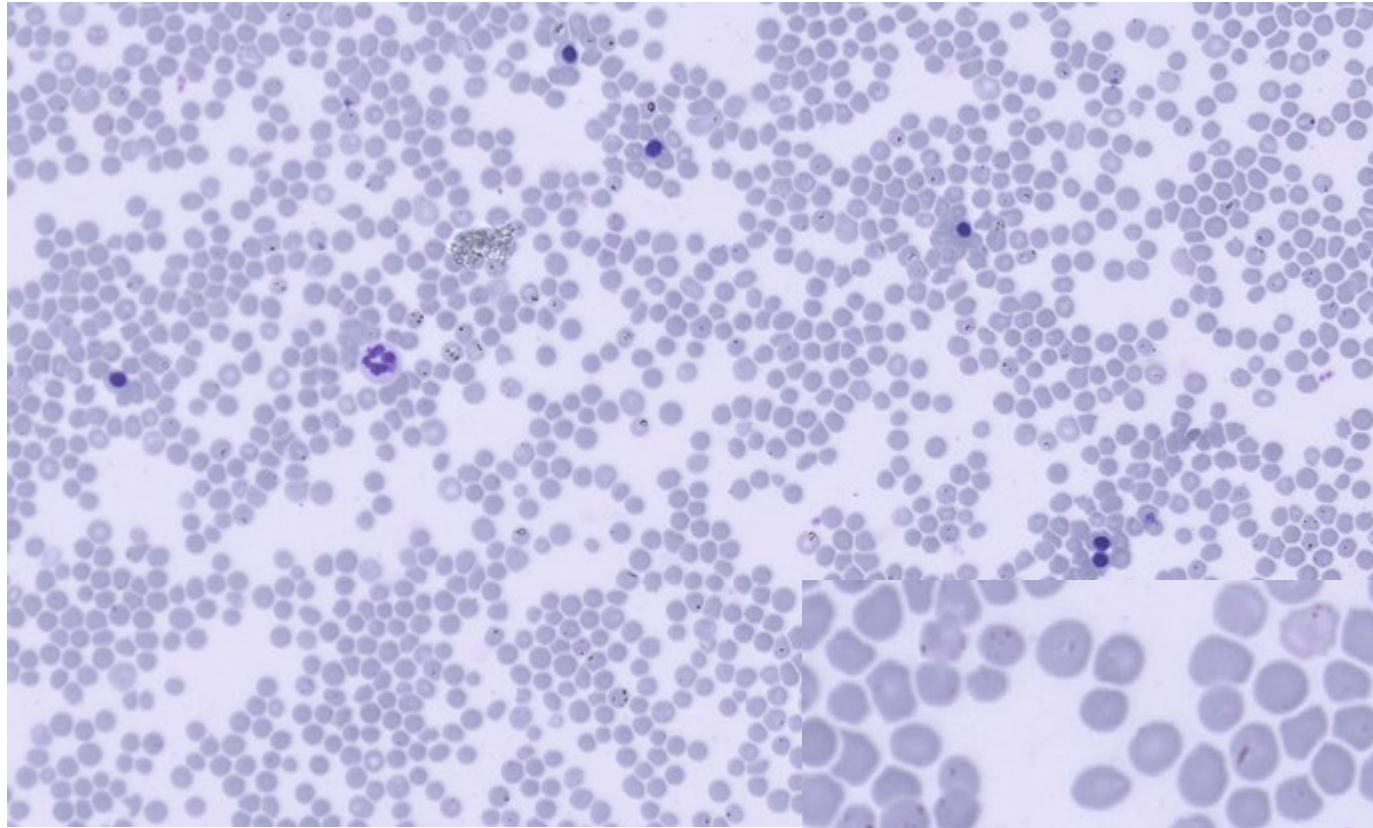
Numerous nRBCs





Numerous nRBCs





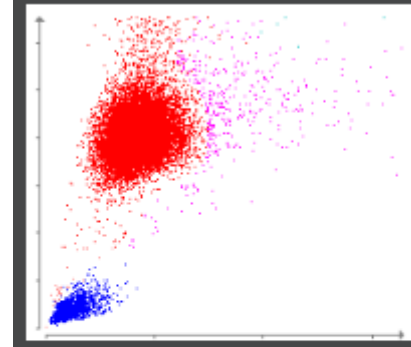
Rambo, 13 year old, male entire cross breed

Haematology < 27/04/2026 09:25

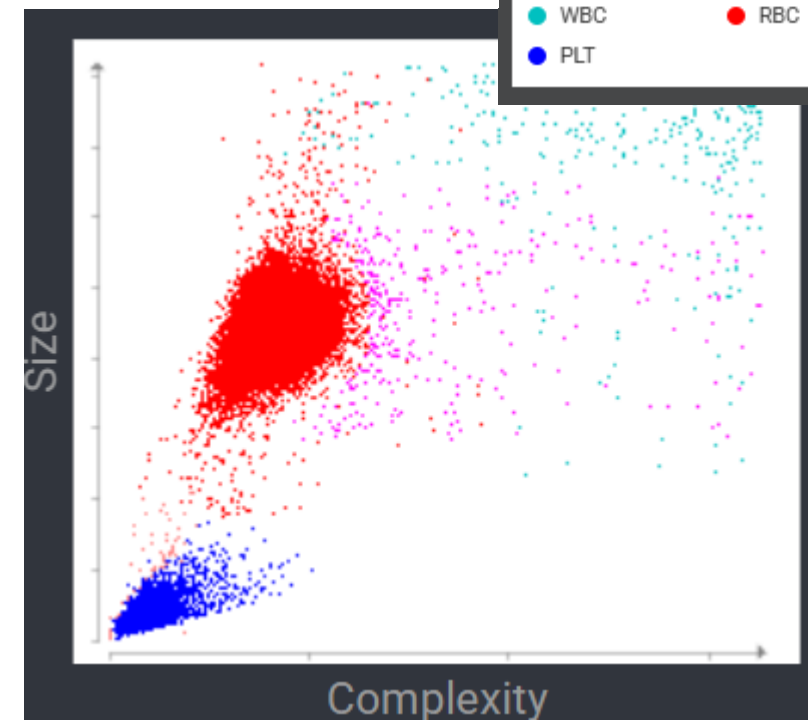

RBC	4.62	5.65 - 8.87 x10 ¹² /L	
Haematocrit	0.331	0.373 - 0.617 L/L	
Haemoglobin	102	131 - 205 g/L	
MCV	71.7	61.6 - 73.5 fL	
MCH	22.2	21.2 - 25.9 pg	
MCHC	309	320 - 379 g/L	
RDW	13.7	13.6 - 21.7 %	
% Reticulocytes	0.9	%	
Reticulocytes	40.3	10.0 - 110.0 K/ μ L	
Platelets	284	148 - 484 x10 ⁹ /L	
PDW	13.9	9.1 - 19.4 fL	
MPV	10.8	8.7 - 13.2 fL	
Plateletcrit	0.31	0.14 - 0.46 %	



Normal RBC Run (Canine)



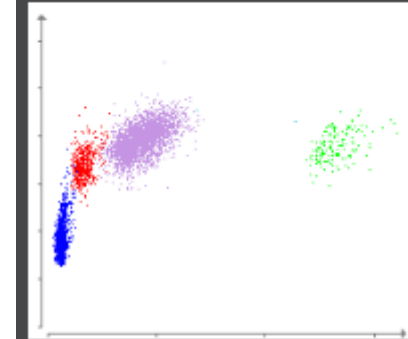
Dot plot legend



Rambo, 13 year old, male entire cross breed



Normal WBC Run (Canine)

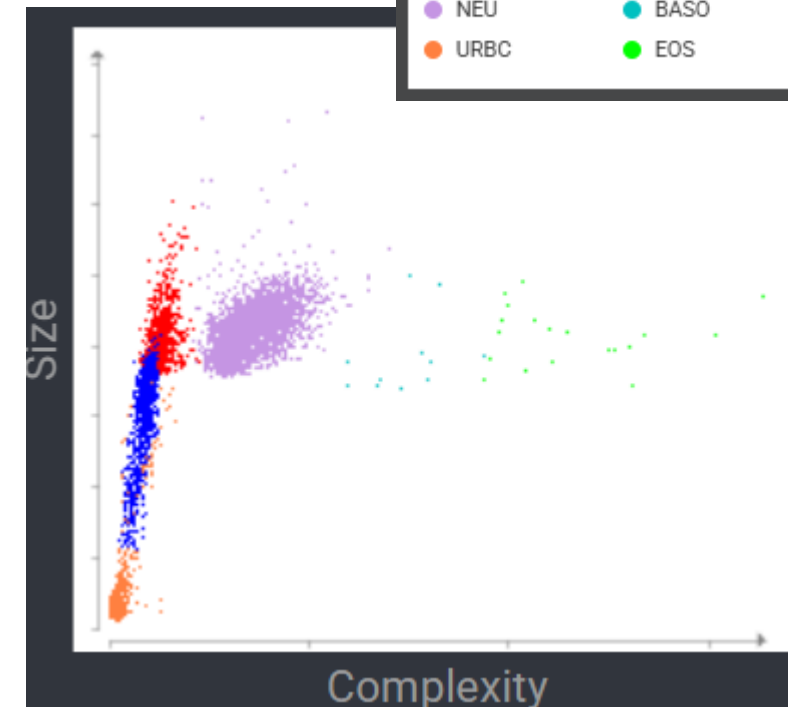


Dot plot legend



WBC	*62.90	5.05 - 16.76 x10 ⁹ /L	
% Neutrophils	*25.4	%	
% Lymphocytes	*16.4	%	
% Monocytes	*58.2	%	
% Eosinophils	*0.0	%	
% Basophils	*0.0	%	
Neutrophils	15.95	2.95 - 11.64 x10 ⁹ /L	
Lymphocytes	*10.34	1.05 - 5.10 x10 ⁹ /L	
Monocytes	*36.58	0.16 - 1.12 x10 ⁹ /L	
Eosinophils	0.02	0.06 - 1.23 x10 ⁹ /L	
Basophils	0.01	0.00 - 0.10 x10 ⁹ /L	

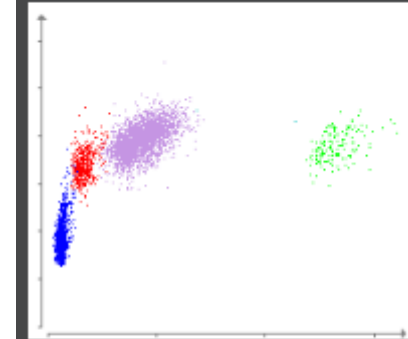
* Confirm with dot plot and/or blood film review.



Rambo, 13 year old, male entire cross breed



Normal WBC Run (Canine)

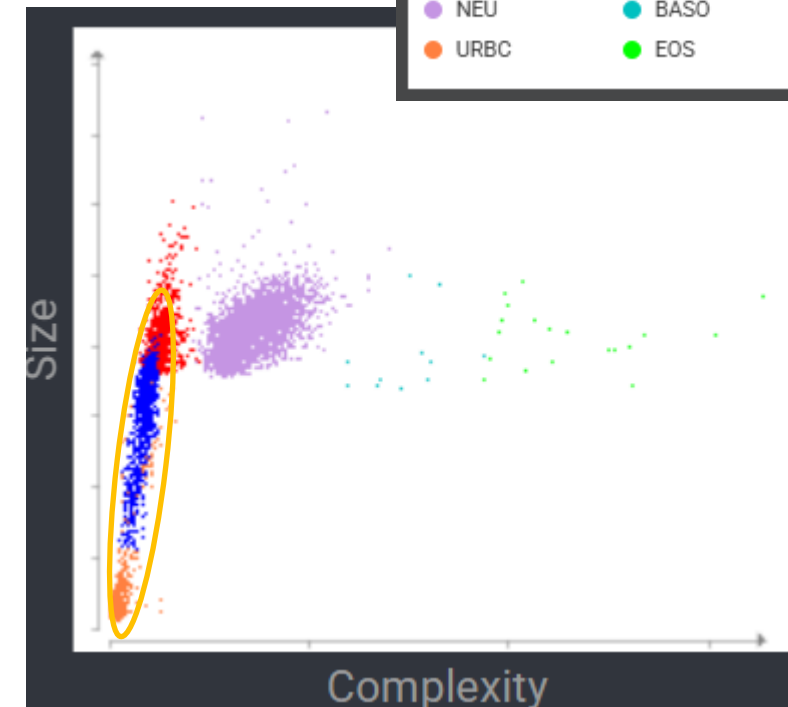


Dot plot legend



WBC	*62.90	5.05 - 16.76 x10 ⁹ /L	
% Neutrophils	*25.4	%	
% Lymphocytes	*16.4	%	
% Monocytes	*58.2	%	
% Eosinophils	*0.0	%	
% Basophils	*0.0	%	
Neutrophils	15.95	2.95 - 11.64 x10 ⁹ /L	
Lymphocytes	*10.34	1.05 - 5.10 x10 ⁹ /L	
Monocytes	*36.58	0.16 - 1.12 x10 ⁹ /L	
Eosinophils	0.02	0.06 - 1.23 x10 ⁹ /L	
Basophils	0.01	0.00 - 0.10 x10 ⁹ /L	

* Confirm with dot plot and/or blood film review.



Rambo, 13 year old, male entire cross breed



Haematology		27/04/2026 10:08	
RBC	a 4.96	5.65 - 8.87 x10 ¹² /L	
Haematocrit	b 0.319	0.373 - 0.617 L/L	
Haemoglobin			
MCV			
MCH			
MCHC			
RDW			
% Reticulocytes	1.0	%	
Reticulocytes	c 47.1	10.0 - 110.0 K/ μ L	
Reticulocyte Haemoglobin			
Platelets			
Platelet Estimate		>150 x10 ⁹ /L (Adequate)	

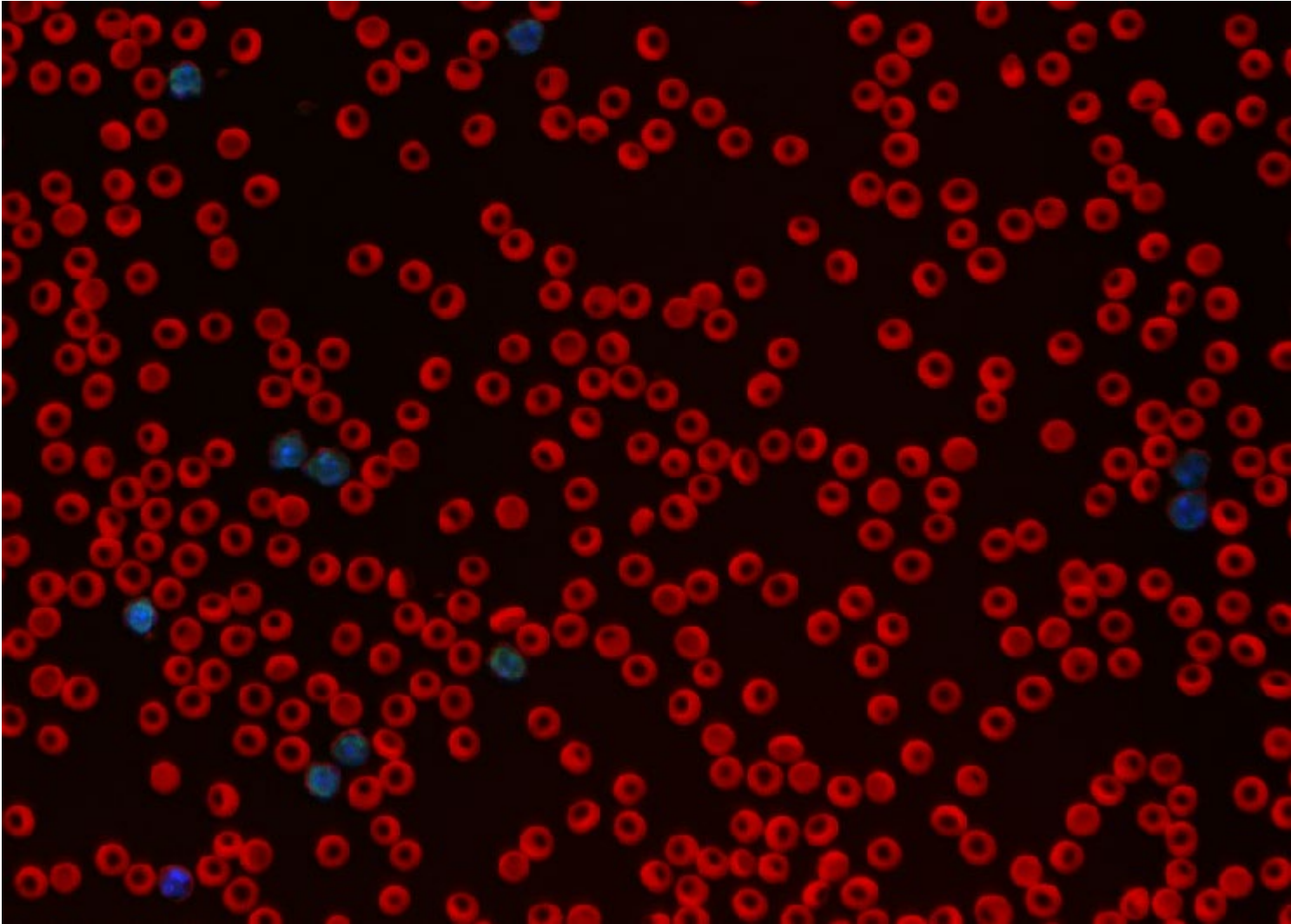
Rambo, 13 year old, male entire cross breed



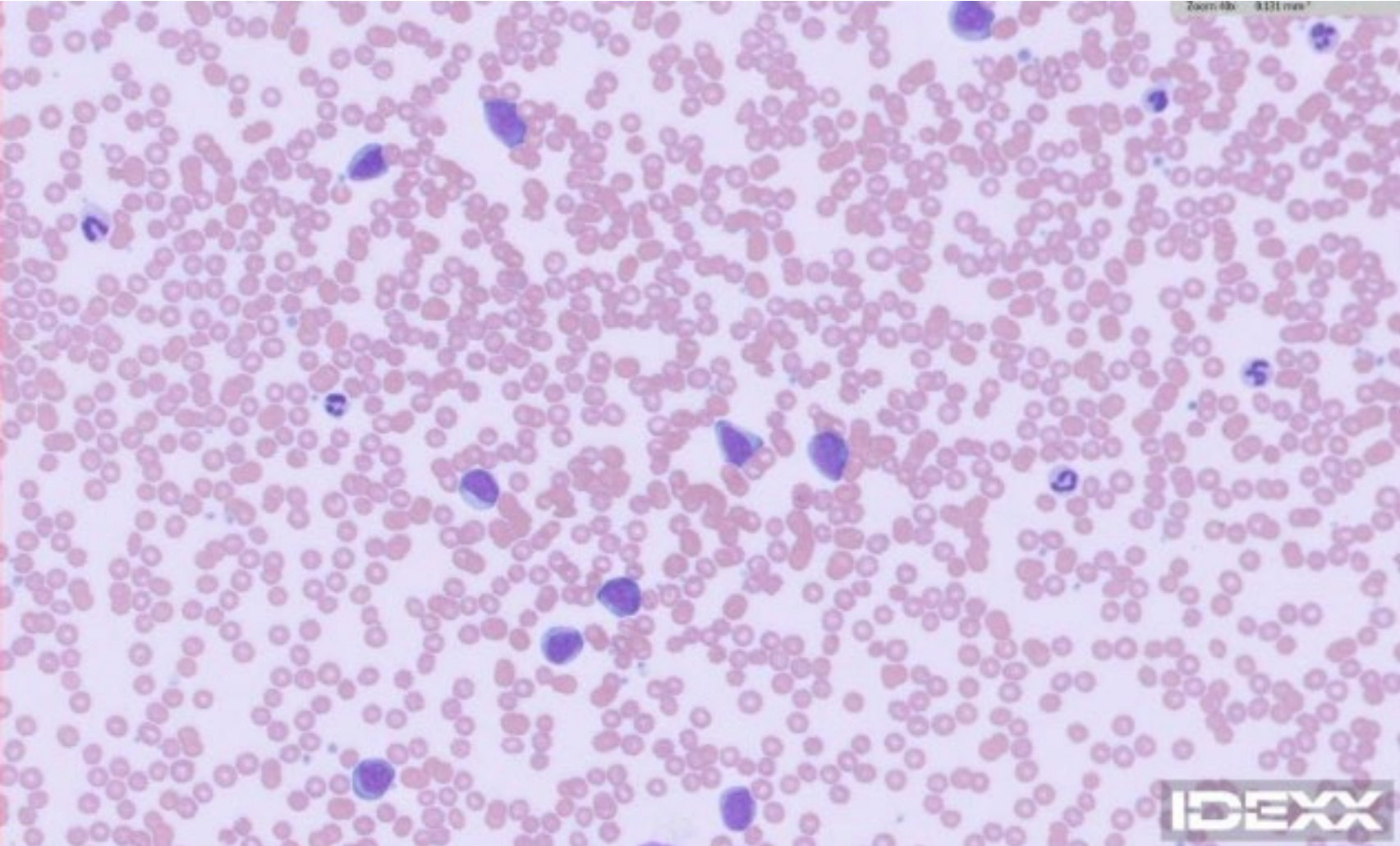
WBC	d	78.79	5.05 - 16.76 x10 ⁹ /L	
% Neutrophils				
% Lymphocytes				
% Monocytes				
% Eosinophils				
% Basophils				
Neutrophils				
Lymphocytes				
Monocytes				
Eosinophils				
Basophils				

Other nucleated cells suspected. Other nucleated blood cells may include early precursor cells, and reactive and neoplastic cell proliferations. When this finding occurs, pathologist evaluation of a traditional blood smear may be pursued to provide further information about the patient's hematologic abnormalities.

Rambo, 13 year old, male entire cross breed



Rambo, 13 year old, male entire cross breed



Nova, 4 year old female entire Siberian husky



Chemistry		12/11/24 7:14 PM	
Glucose	7.49	4.11 - 7.94 mmol/L	
IDEXX SDMA	9	0 - 14 µg/dL	
Creatinine	26.52	44.2 - 159.12 µmol/L	
BUN	2.14	2.5 - 9.64 mmol/L	
BUN: Creatinine Ratio	20		
Phosphorus	1.1	0.81 - 2.2 mmol/L	
Calcium	2	1.97 - 2.99 mmol/L	
Sodium	157	144 - 160 mmol/L	
Potassium	3.7	3.5 - 5.8 mmol/L	
Na: K Ratio	42		
Chloride	112	109 - 122 mmol/L	
Total Protein	47	52 - 82 g/L	
Albumin	16	23 - 40 g/L	
Globulin	31	25 - 45 g/L	
Albumin: Globulin Ratio	0.5		
ALT	104	10 - 125 U/L	
ALP	110	23 - 212 U/L	
GGT	18	0 - 11 U/L	
Bilirubin - Total	8.55	0 - 15.39 µmol/L	
Cholesterol	2.56	2.84 - 8.28 mmol/L	
Amylase	280	500 - 1,500 U/L	
Lipase	437	200 - 1,800 U/L	
Osmolality	309	mmol/kg	

Nova, 4 year old female entire Siberian husky



Chemistry		12/11/24 7:14 PM	
Glucose	7.49	4.11 - 7.94 mmol/L	
IDEXX SDMA	9	0 - 14 µg/dL	
Creatinine	26.52	44.2 - 159.12 µmol/L	
BUN	2.14	2.5 - 9.64 mmol/L	
BUN: Creatinine Ratio	20		
Phosphorus	1.1	0.81 - 2.2 mmol/L	
Calcium	2	1.97 - 2.99 mmol/L	
Sodium	157	144 - 160 mmol/L	
Potassium	3.7	3.5 - 5.8 mmol/L	
Na: K Ratio	42		
Chloride	112	109 - 122 mmol/L	
Total Protein	47	52 - 82 g/L	
Albumin	16	23 - 40 g/L	
Globulin	31	25 - 45 g/L	
Albumin: Globulin Ratio	0.5		
ALT	104	10 - 125 U/L	
ALP	110	23 - 212 U/L	
GGT	18	0 - 11 U/L	
Bilirubin - Total	8.55	0 - 15.39 µmol/L	
Cholesterol	2.56	2.84 - 8.28 mmol/L	
Amylase	280	500 - 1,500 U/L	
Lipase	437	200 - 1,800 U/L	
Osmolality	309	mmol/kg	



Moderate regenerative anaemia
Microcytosis

Hematology		12/11/24 6:55 PM	
RBC	4.08	5.65 - 8.87 x10 ¹² /L	
Hematocrit	0.224	0.373 - 0.617 L/L	
Hemoglobin	82	131 - 205 g/L	
MCV	54.9	61.6 - 73.5 fL	
MCH	20.1	21.2 - 25.9 pg	
MCHC	366	320 - 379 g/L	
RDW	18.6	13.6 - 21.7 %	
% Reticulocytes	4.2	%	
Reticulocytes	169.7	10.0 - 110.0 K/ μ L	
Reticulocyte Hemoglobin	23.5	22.3 - 29.6 pg	
WBC	*17.50	5.05 - 16.76 x10 ⁹ /L	
% Neutrophils	*80.6	%	
% Lymphocytes	*12.4	%	
% Monocytes	*4.3	%	
% Eosinophils	*2.6	%	
% Basophils	*0.1	%	
Neutrophils	*14.11	2.95 - 11.64 x10 ⁹ /L	
Lymphocytes	*2.17	1.05 - 5.10 x10 ⁹ /L	
Monocytes	*0.75	0.16 - 1.12 x10 ⁹ /L	
Eosinophils	*0.45	0.06 - 1.23 x10 ⁹ /L	
Basophils	*0.02	0.00 - 0.10 x10 ⁹ /L	
Nucleated RBCs	*Suspected		
Platelets	225	148 - 484 x10 ⁹ /L	
PDW	14.6	9.1 - 19.4 fL	
MPV	11.0	8.7 - 13.2 fL	
Plateletcrit	0.25	0.14 - 0.46 %	



Leukocytosis
Suspected nRBCs

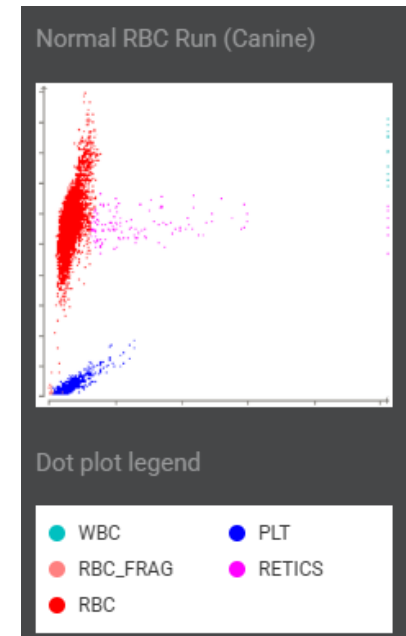
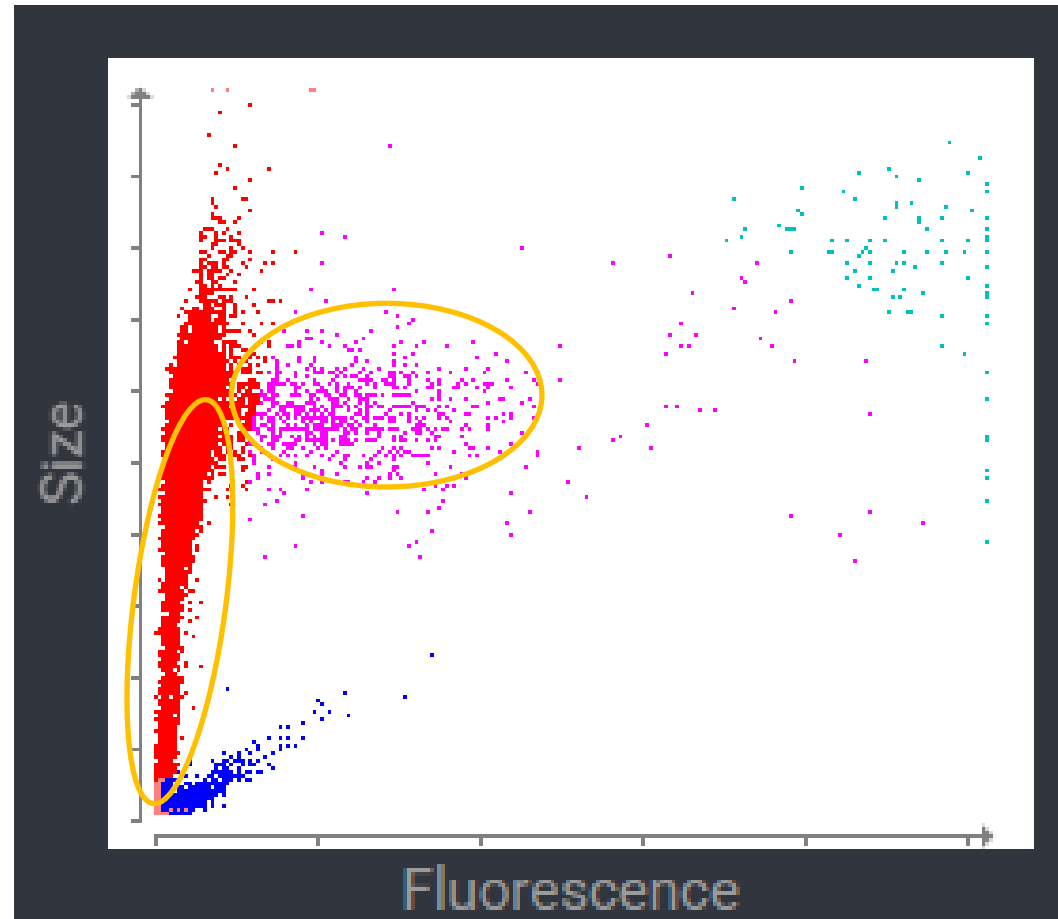
Hematology		12/11/24 6:55 PM	
WBC	*17.50	5.05 - 16.76 x10 ⁹ /L	
% Neutrophils	*80.6	%	
% Lymphocytes	*12.4	%	
% Monocytes	*4.3	%	
% Eosinophils	*2.6	%	
% Basophils	*0.1	%	
Neutrophils	*14.11	2.95 - 11.64 x10 ⁹ /L	
Lymphocytes	*2.17	1.05 - 5.10 x10 ⁹ /L	
Monocytes	*0.75	0.16 - 1.12 x10 ⁹ /L	
Eosinophils	*0.45	0.06 - 1.23 x10 ⁹ /L	
Basophils	*0.02	0.00 - 0.10 x10 ⁹ /L	
Nucleated RBCs	*Suspected		
Platelets	225	148 - 484 x10 ⁹ /L	
PDW	14.6	9.1 - 19.4 fL	
MPV	11.0	8.7 - 13.2 fL	
Plateletcrit	0.25	0.14 - 0.46 %	



Hematology		12/11/24 6:55 PM	
WBC	*17.50	5.05 - 16.76 x10 ⁹ /L	
% Neutrophils	*80.6	%	
% Lymphocytes	*12.4	%	
% Monocytes	*4.3	%	
% Eosinophils	*2.6	%	
% Basophils	*0.1	%	
Neutrophils	*14.11	2.95 - 11.64 x10 ⁹ /L	
Lymphocytes	*2.17	1.05 - 5.10 x10 ⁹ /L	
Monocytes	*0.75	0.16 - 1.12 x10 ⁹ /L	
Eosinophils	*0.45	0.06 - 1.23 x10 ⁹ /L	
Basophils	*0.02	0.00 - 0.10 x10 ⁹ /L	
Nucleated RBCs	*Suspected		
Platelets	225	148 - 484 x10 ⁹ /L	
PDW	14.6	9.1 - 19.4 fL	
MPV	11.0	8.7 - 13.2 fL	
Plateletcrit	0.25	0.14 - 0.46 %	

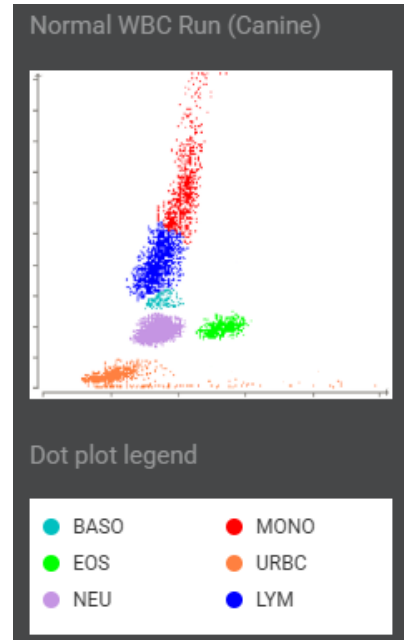
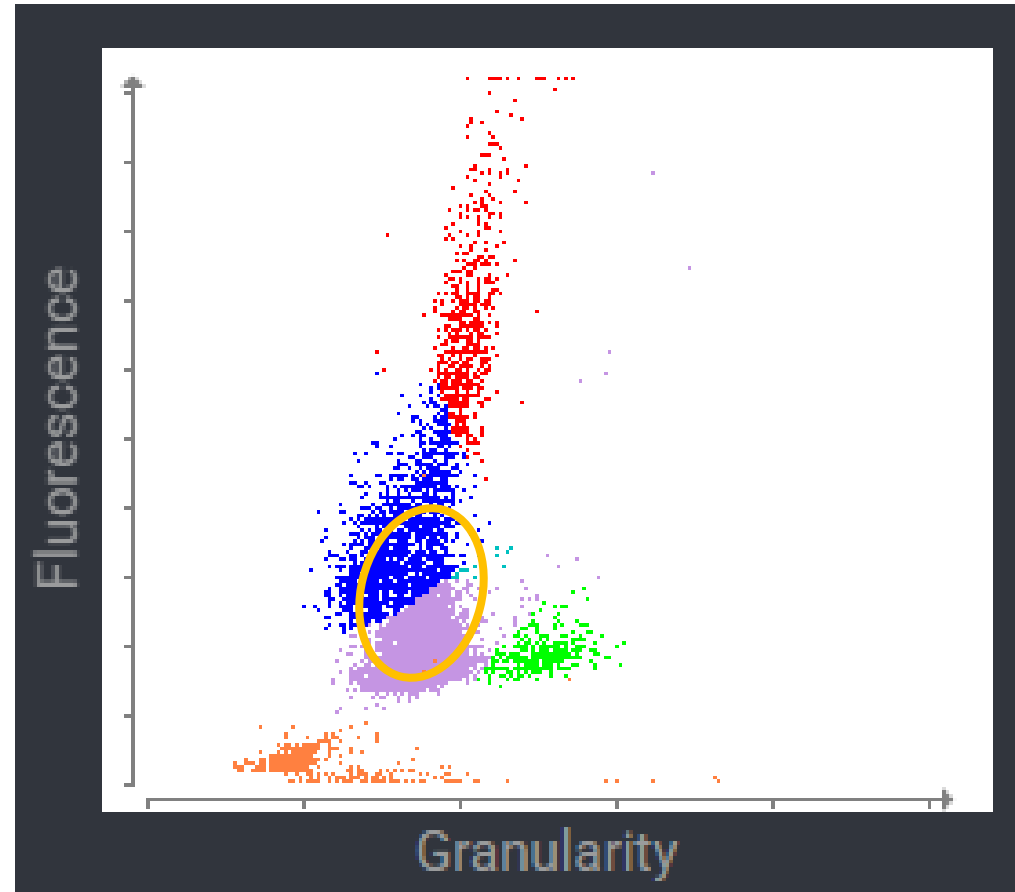
Nova

Reticulocytes
RBC plot is elongated
and shifted downwards
Platelet cloud appears
normal



Nova

Convergence of neutrophil and lymphocyte cloud
This may be due to increased fluorescence of neutrophils e.g. toxicity



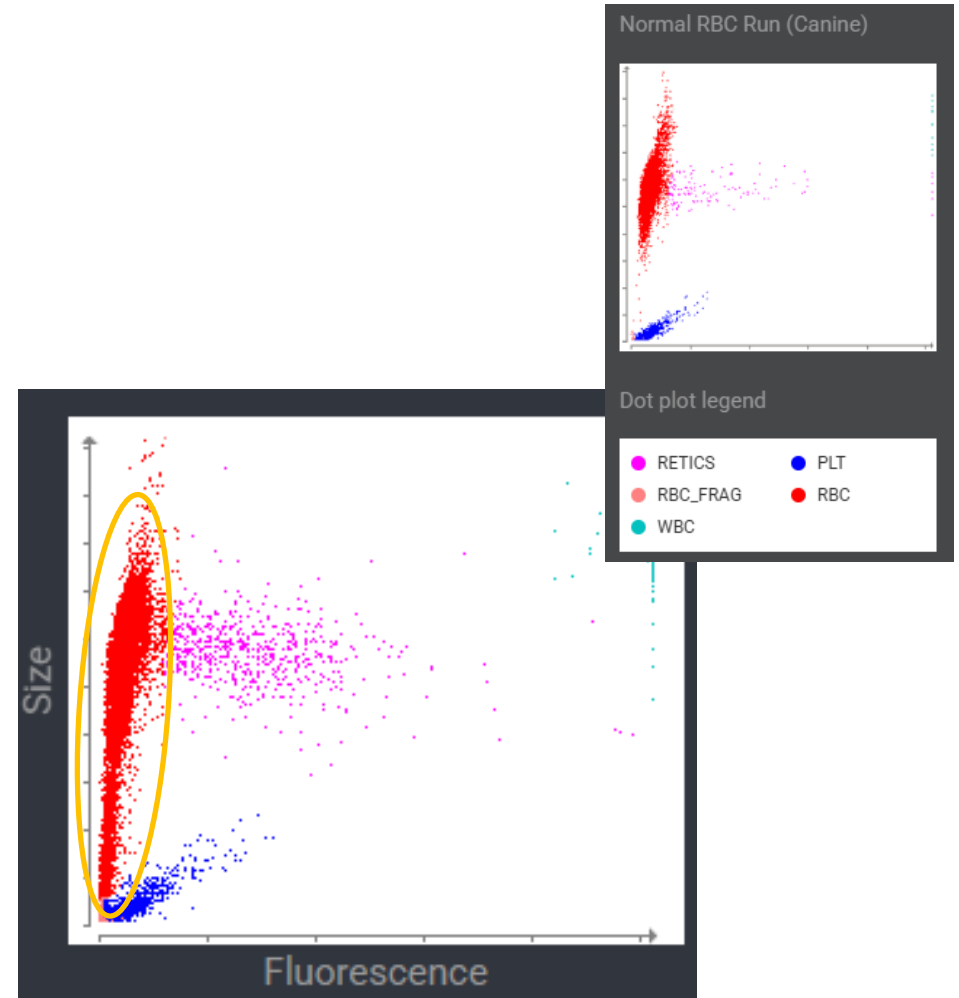
Nova, 4 year old female entire Siberian husky

10-day follow-up

Distended, painful abdomen with palpable fluid wave

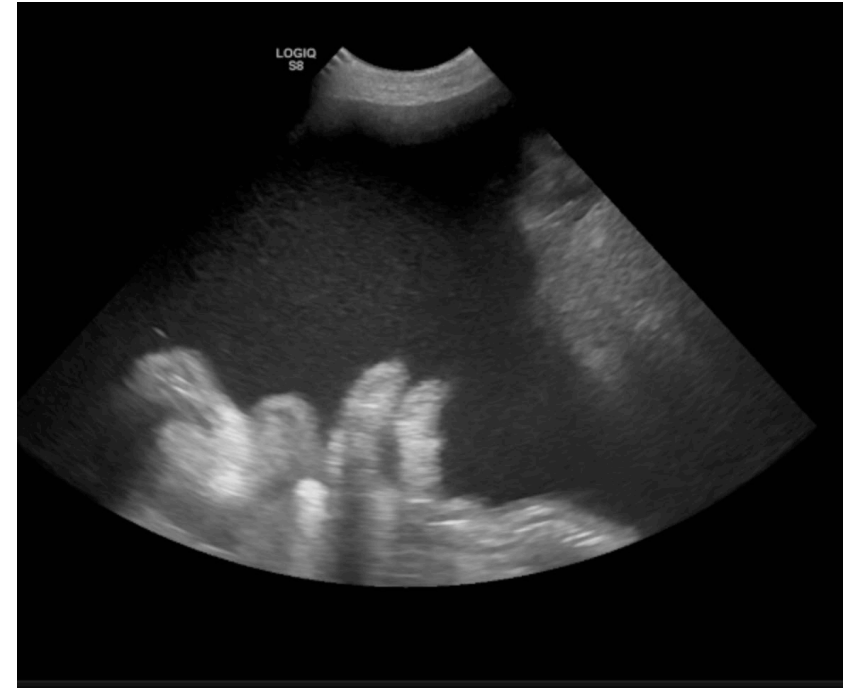Hematology		12/20/24	12/20/24
		8:45 AM	8:33 AM
RBC	3.40	3.40	5.65 - 8.87 x10 ¹² /L
Hematocrit	0.181	0.181	0.373 - 0.617 L/L
Hemoglobin	72	72	131 - 205 g/L
MCV	53.2	53.2	61.6 - 73.5 fL
MCH	21.2	21.2	21.2 - 25.9 pg
MCHC	398	398	320 - 379 g/L
RDW	22.9	22.9	13.6 - 21.7 %
% Reticulocytes	3.2	3.2	%
Reticulocytes	107.4	107.4	10.0 - 110.0 K/ μ L
Reticulocyte Hen	23.8	23.8	22.3 - 29.6 pg

Agglutination and spherocytes were not detected.



Nova, 4 year old female entire Siberian husky

- + 10-day follow-up exam
- + Distended, painful abdomen with palpable fluid wave
- + Worsening microcytic, nonregenerative anaemia



Nova, 4 year old female entire Siberian husky

Hematology		10:19 AM	10:18 AM
RBC	3.40	5.65 - 8.87 x10 ¹² /L	a 3.40 5.65 - 8.87 x10 ¹² /L
Hematocrit	0.181	0.373 - 0.617 L/L	b 0.181 0.373 - 0.617 L/L
Hemoglobin	72	131 - 205 g/L	
MCV	53.2	61.6 - 73.5 fL	
MCH	21.2	21.2 - 25.9 pg	
MCHC	398	320 - 379 g/L	
RDW	22.9	13.6 - 21.7 %	
Acanthocytes			1.29% (Moderate)
Schistocytes			4.91% (Moderate)
% Reticulocytes	3.2	%	3.2 %
Reticulocytes	107.4	10.0 - 110.0 K/ μ L	b 107.4 10.0 - 110.0 K/ μ L
Reticulocyte Hemoglobin	23.8	22.3 - 29.6 pg	
WBC	26.03	5.05 - 16.76 x10 ⁹ /L	c 26.03 5.05 - 16.76 x10 ⁹ /L
% Neutrophils	*77.6	%	86.4 %
% Immature Neutrophils			3.1 %
% Lymphocytes	*17.1	%	3.8 %
% Monocytes	*5.1	%	4.8 %
% Eosinophils	0.2	%	1.4 %
% Basophils	0.0	%	0.4 %

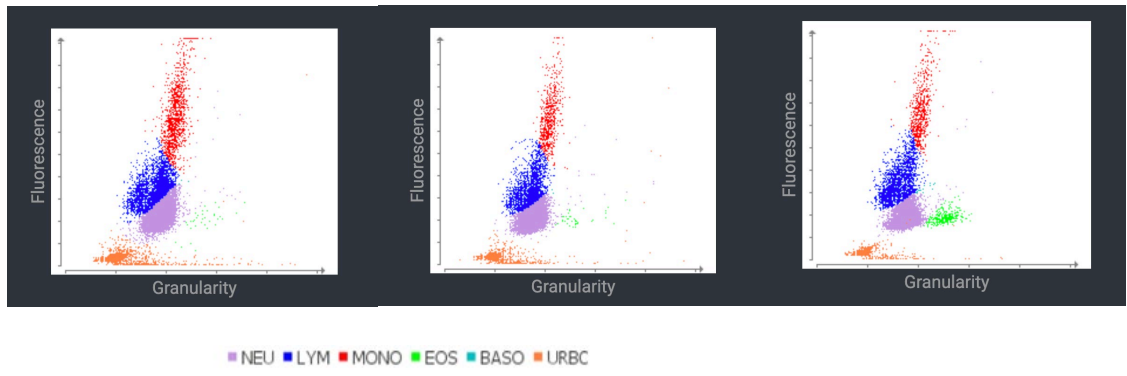
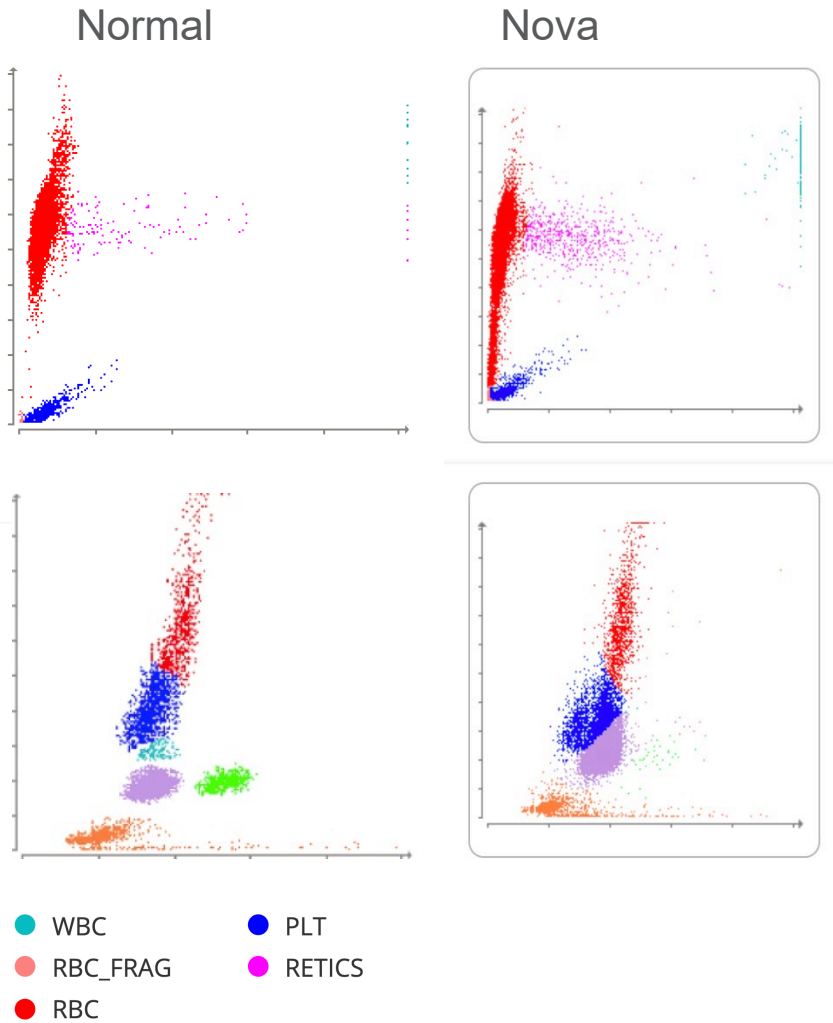


Nova, 4 year old female entire Siberian husky

Hematology		10:19 AM	10:18 AM	
Neutrophils	+20.21	2.95 - 11.64 x10 ⁹ /L	22.50	2.95 - 11.64 x10 ⁹ /L
Immature Neutrophils			0.80	x10 ⁹ /L
Lymphocytes	+4.45	1.05 - 5.10 x10 ⁹ /L	0.99	1.05 - 5.10 x10 ⁹ /L
Monocytes	+1.33	0.16 - 1.12 x10 ⁹ /L	1.26	0.16 - 1.12 x10 ⁹ /L
Eosinophils	0.04	0.06 - 1.23 x10 ⁹ /L	0.36	0.06 - 1.23 x10 ⁹ /L
Basophils	0.00	0.00 - 0.10 x10 ⁹ /L	0.12	0.00 - 0.10 x10 ⁹ /L
Platelets	+219	148 - 484 x10 ⁹ /L		
Platelet Estimate				>150 x10 ⁹ /L (Adequate)
PDW	-	--		9.1 - 19.4 fL
MPV	13.1	8.7 - 13.2 fL		
Plateletcrit	0.08	0.14 - 0.46 %		



Nova, 4 year old female entire Siberian husky



←
Trending
over time

Nova, 4 year old female entire Siberian husky

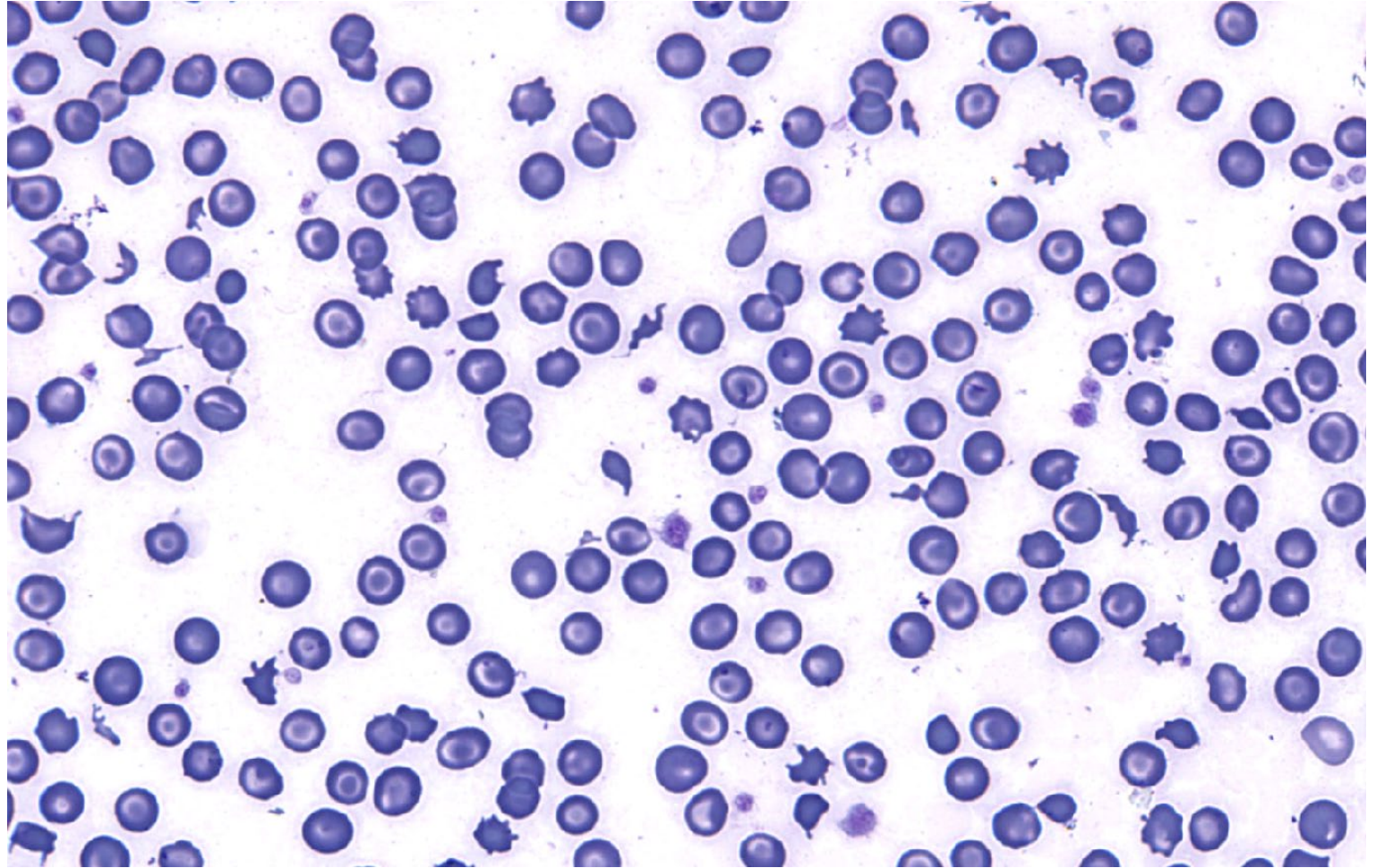
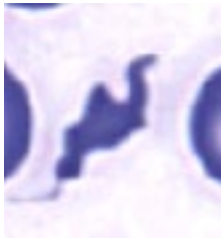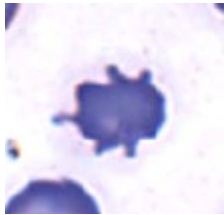
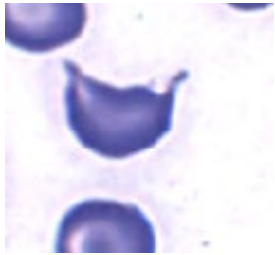
Hematology		10:19 AM	10:18 AM
RBC	3.40	5.65 - 8.87 x10 ¹² /L	a 3.40 5.65 - 8.87 x10 ¹² /L
Hematocrit	0.181	0.373 - 0.617 L/L	b 0.181 0.373 - 0.617 L/L
Hemoglobin	72	131 - 205 g/L	
MCV	53.2	61.6 - 73.5 fL	
MCH	21.2	21.2 - 25.9 pg	
MCHC	398	320 - 379 g/L	
RDW	22.9	13.6 - 21.7 %	
Acanthocytes			1.29% (Moderate)
Schistocytes			4.91% (Moderate)
% Reticulocytes	3.2	%	3.2 %
Reticulocytes	107.4	10.0 - 110.0 K/ μ L	b 107.4 10.0 - 110.0 K/ μ L
Reticulocyte Hemoglobin	23.8	22.3 - 29.6 pg	
WBC	26.03	5.05 - 16.76 x10 ⁹ /L	c 26.03 5.05 - 16.76 x10 ⁹ /L
% Neutrophils	*77.6	%	86.4 %
% Immature Neutrophils			3.1 %
% Lymphocytes	*17.1	%	3.8 %
% Monocytes	*5.1	%	4.8 %
% Eosinophils	0.2	%	1.4 %
% Basophils	0.0	%	0.4 %

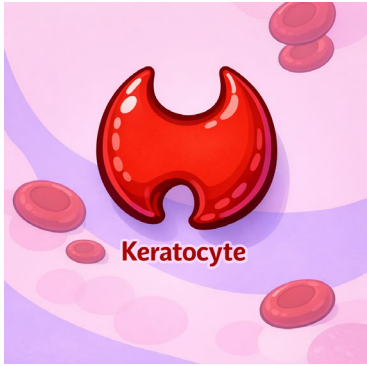

Nova, 4 year old female entire Siberian husky

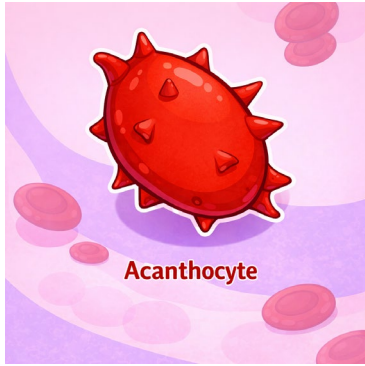
Hematology		10:19 AM	10:18 AM
Neutrophils	+20.21	2.95 - 11.64 x10 ⁹ /L	22.50 2.95 - 11.64 x10 ⁹ /L
Immature Neutrophils			0.80 x10 ⁹ /L
Lymphocytes	*4.45	1.05 - 5.10 x10 ⁹ /L	0.99 1.05 - 5.10 x10 ⁹ /L
Monocytes	*1.33	0.16 - 1.12 x10 ⁹ /L	1.26 0.16 - 1.12 x10 ⁹ /L
Eosinophils	0.04	0.06 - 1.23 x10 ⁹ /L	0.36 0.06 - 1.23 x10 ⁹ /L
Basophils	0.00	0.00 - 0.10 x10 ⁹ /L	0.12 0.00 - 0.10 x10 ⁹ /L
Platelets	*219	148 - 484 x10 ⁹ /L	
Platelet Estimate			>150 K/uL (Adequate)
PDW	- --	9.1 - 19.4 fL	
MPV	13.1	8.7 - 13.2 fL	
Plateletcrit	0.08	0.14 - 0.46 %	



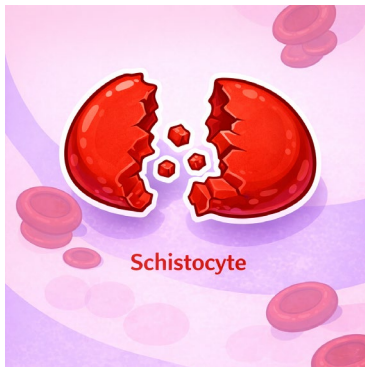



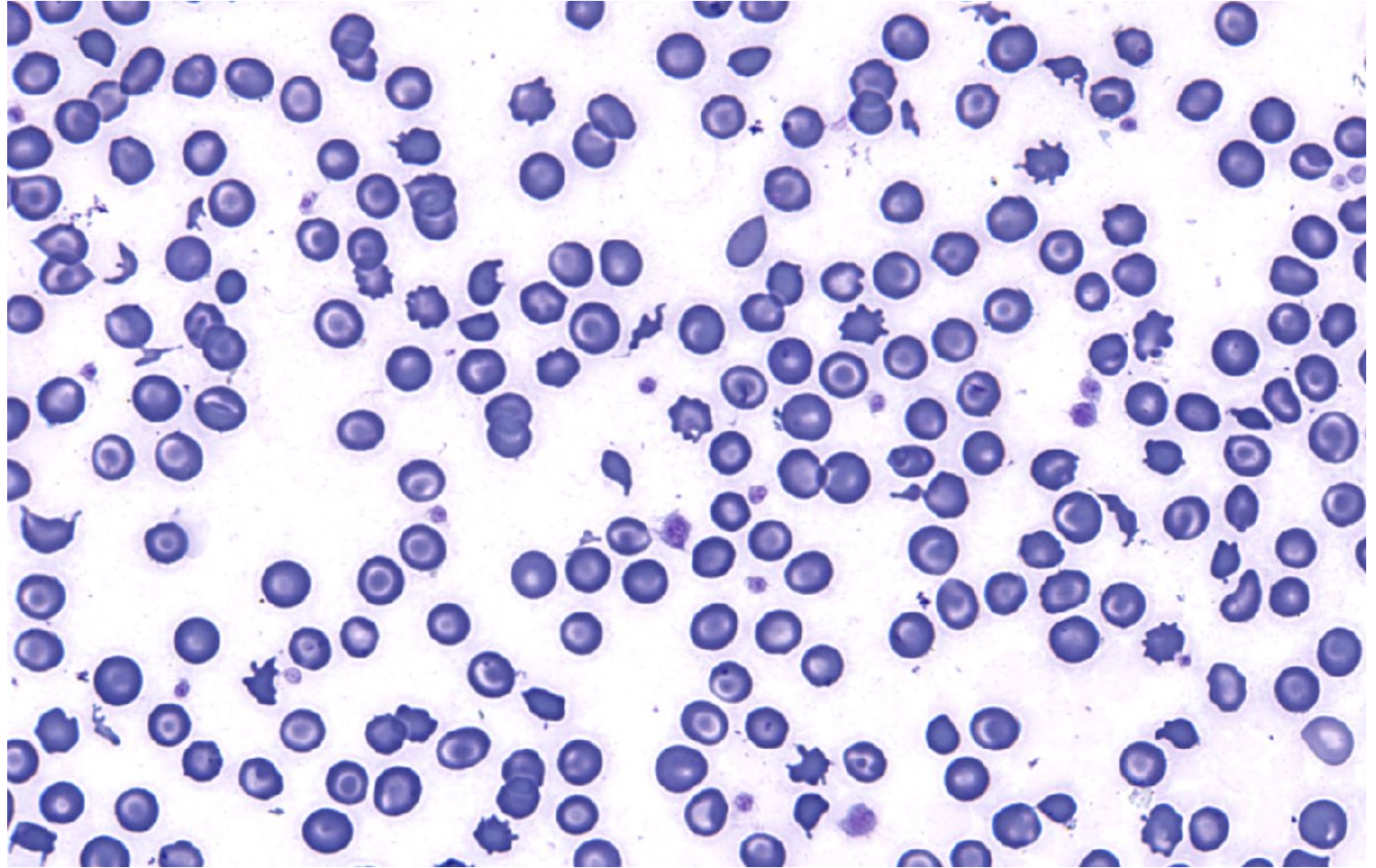
Keratocyte

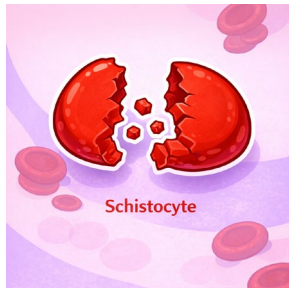
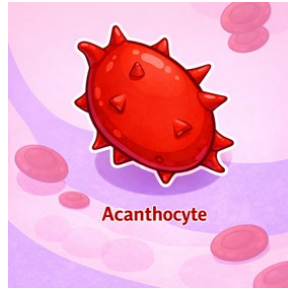
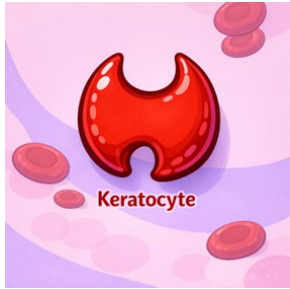
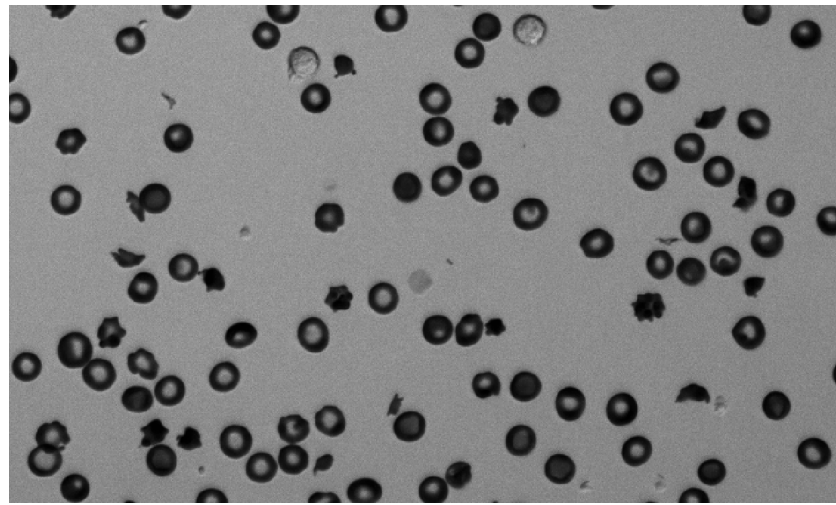


Acanthocyte

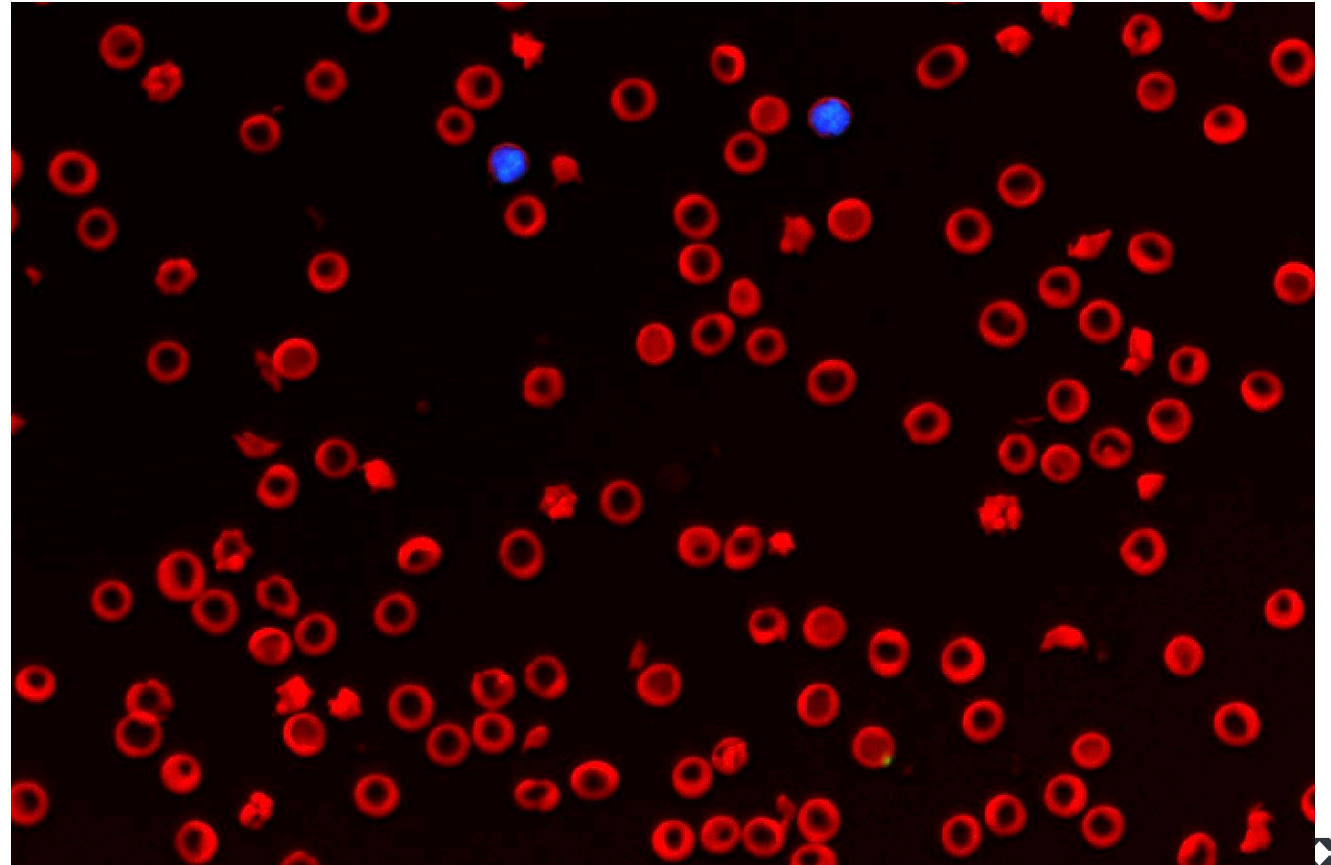


Schistocyte






No spherocytes or agglutination seen





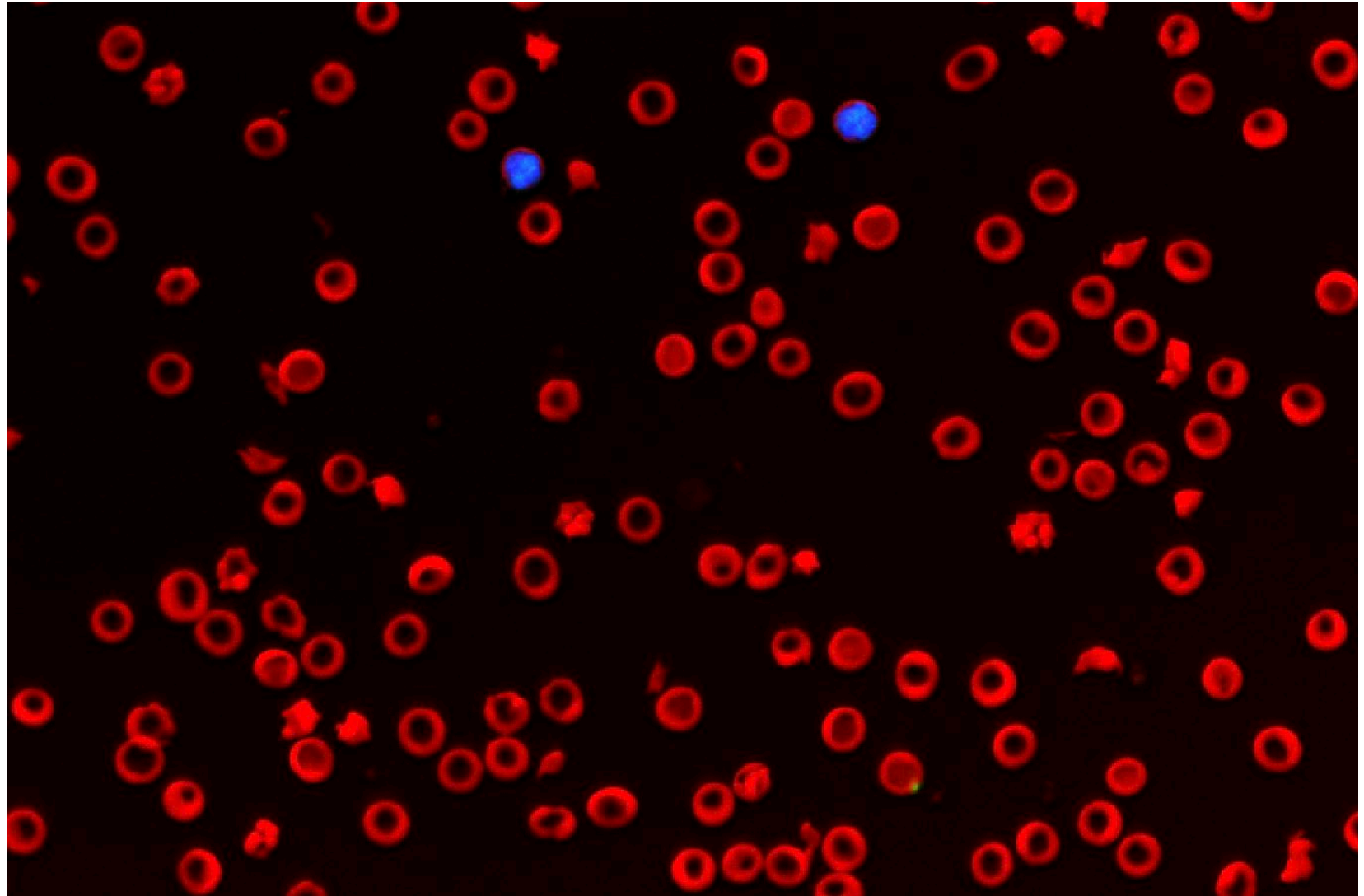
Acanthocytes, schistocytes, &
keratocytes

No spherocytes or agglutination
seen





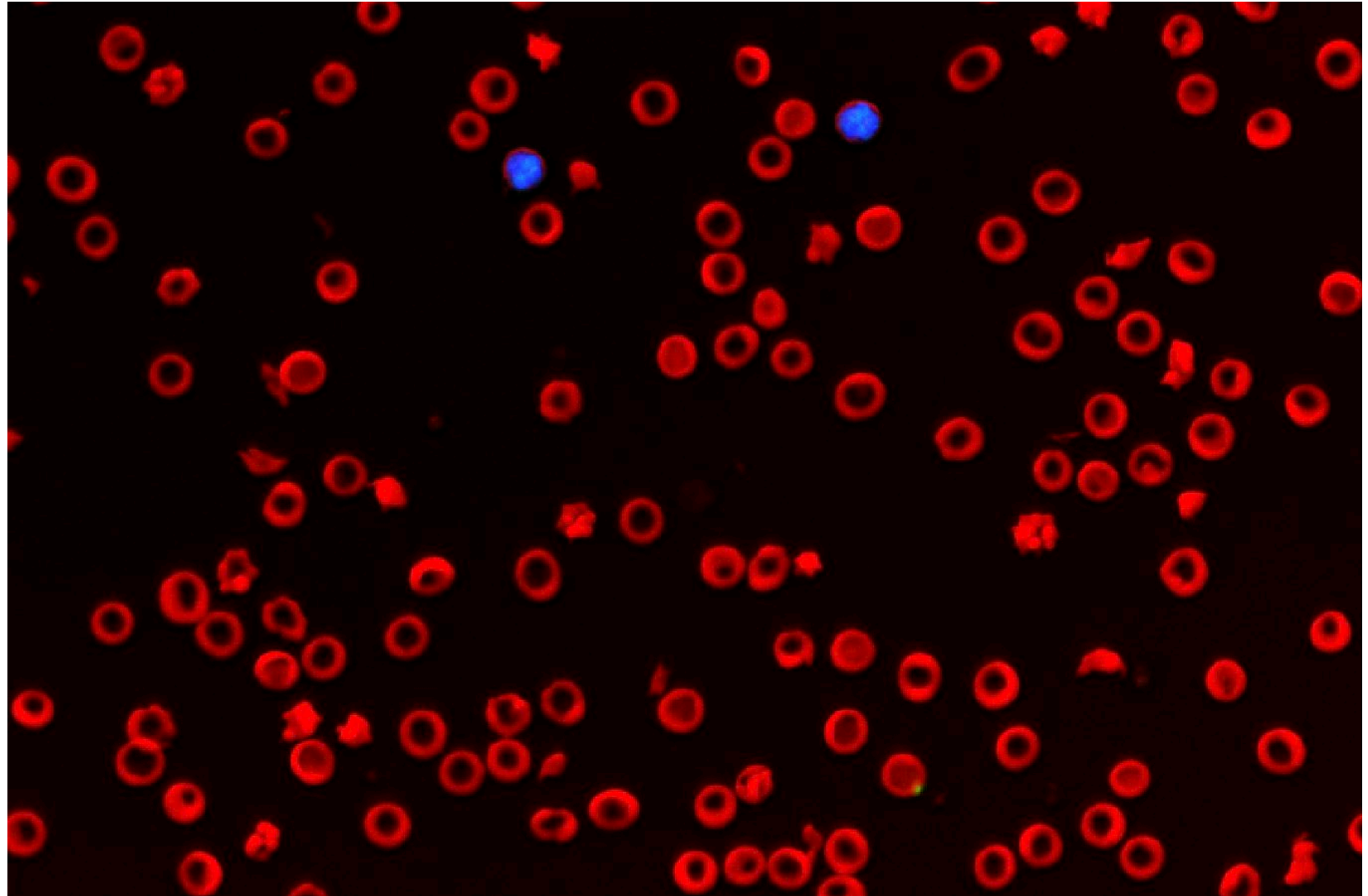
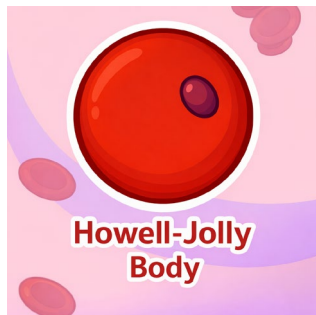Acanthocytes, schistocytes, &
keratocytes
No spherocytes or agglutination
seen



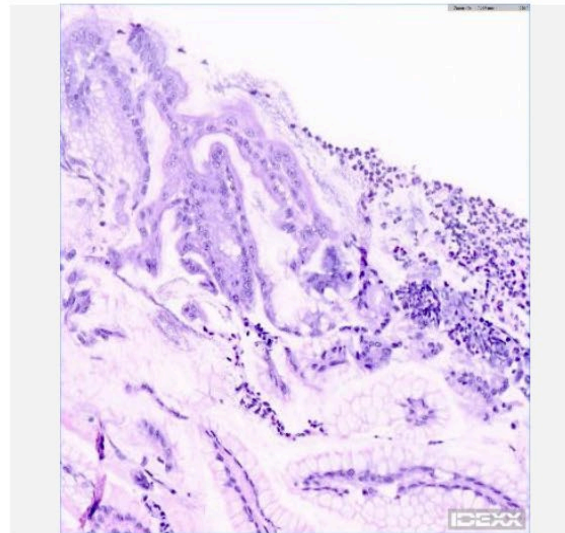
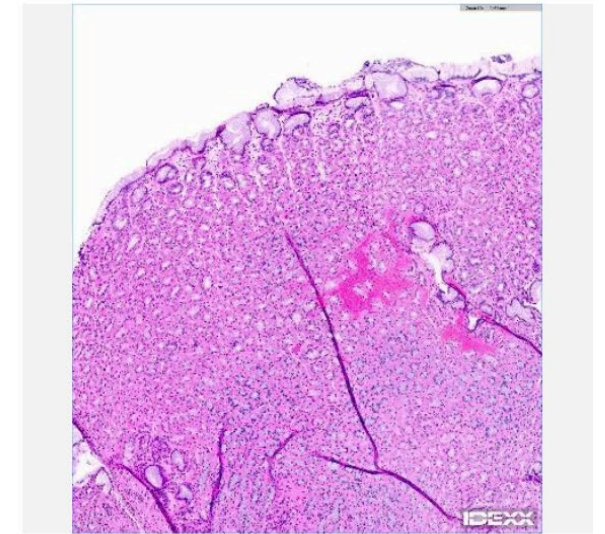
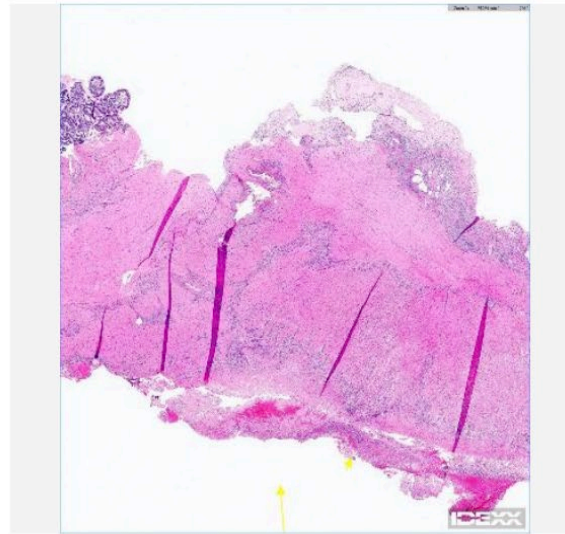


Acanthocytes, schistocytes, & keratocytes

No spherocytes or agglutination seen



- **Gastroduodenoscopy findings:**
 - Ulcers seen in stomach, proximal duodenum ended up having a perforation and patient was taken for exploratory
- Diagnosed with **Helicobacter gastritis**



Small intestine (duodenum perforation site): Severe subacute to chronic segmental ulceration with fibrosis and suppurative inflammation with edema and serositis

Small intestine (duodenum): Mild chronic lymphoplasmacytic enteritis

Stomach: Mild chronic active superficial gastritis with fibrosis and edema, hemorrhage and rare erosion and *Helicobacter* species

What the IDEXX inVue Dx™ Cellular Analyser adds

ProCyte Dx™

- Platelet count
- 5-part WBC differential
- Interpretive Prompts for platelet clumping and bands
- Dot Plots for RBC, PLT, WBC



IDEXX inVue Dx

- Platelet estimate even if clumps
- Update WBC tot and diff when necessary
- Informs when WBC differential is updated
- Immature neutrophils (canine, feline)
- Other nucleated cells (canine, feline)
- Reticulocytes
- RBC morphology assessment (canine)
- RBC Agglutination (canine)





Any Question?



IDEXX